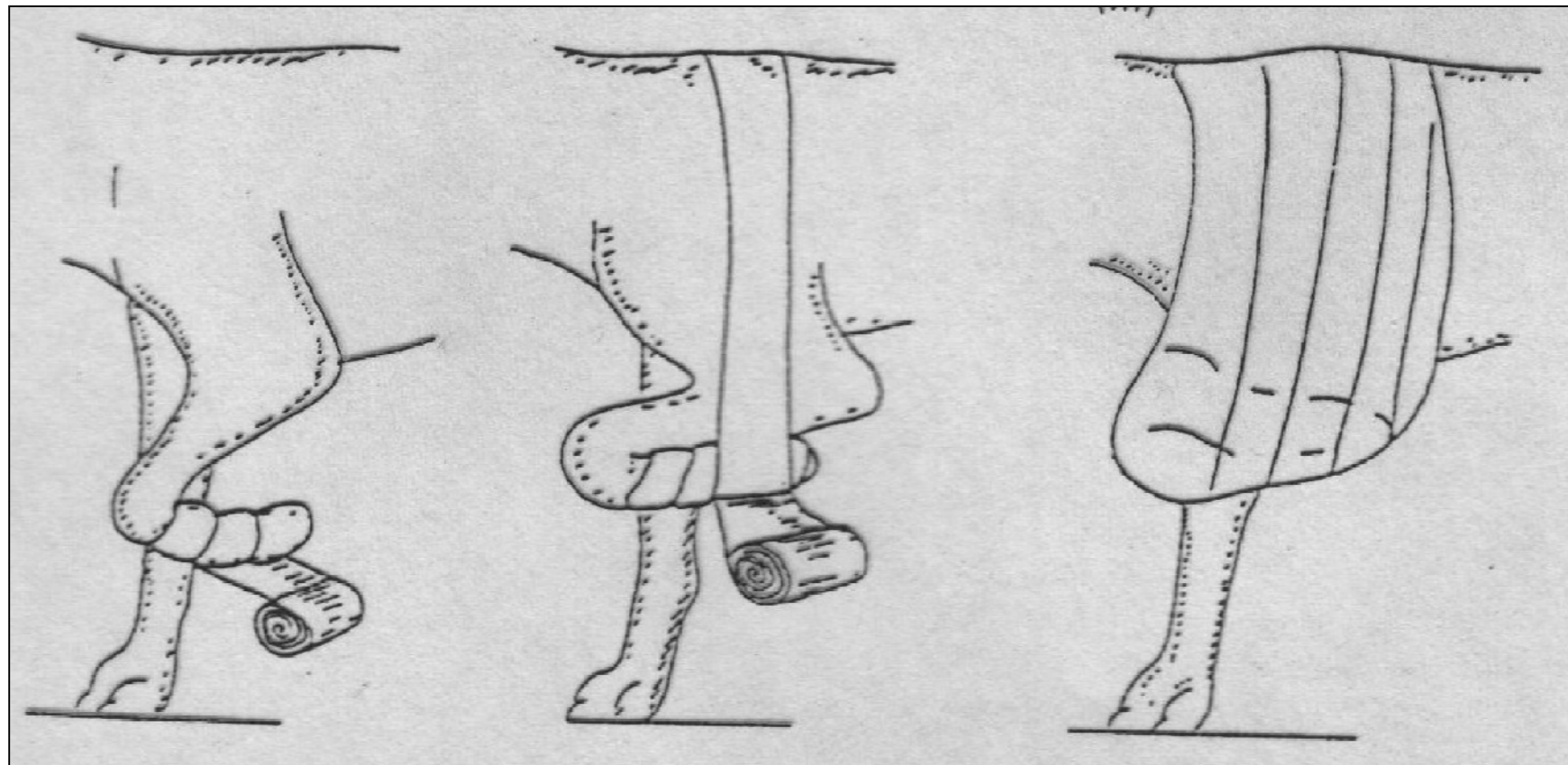
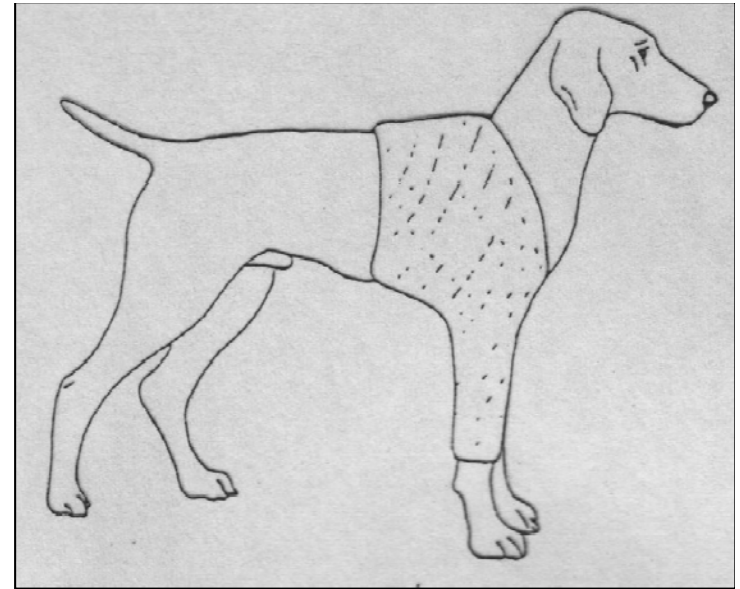


Παθήσεις των οστών τραυματικής αιτιολογίας

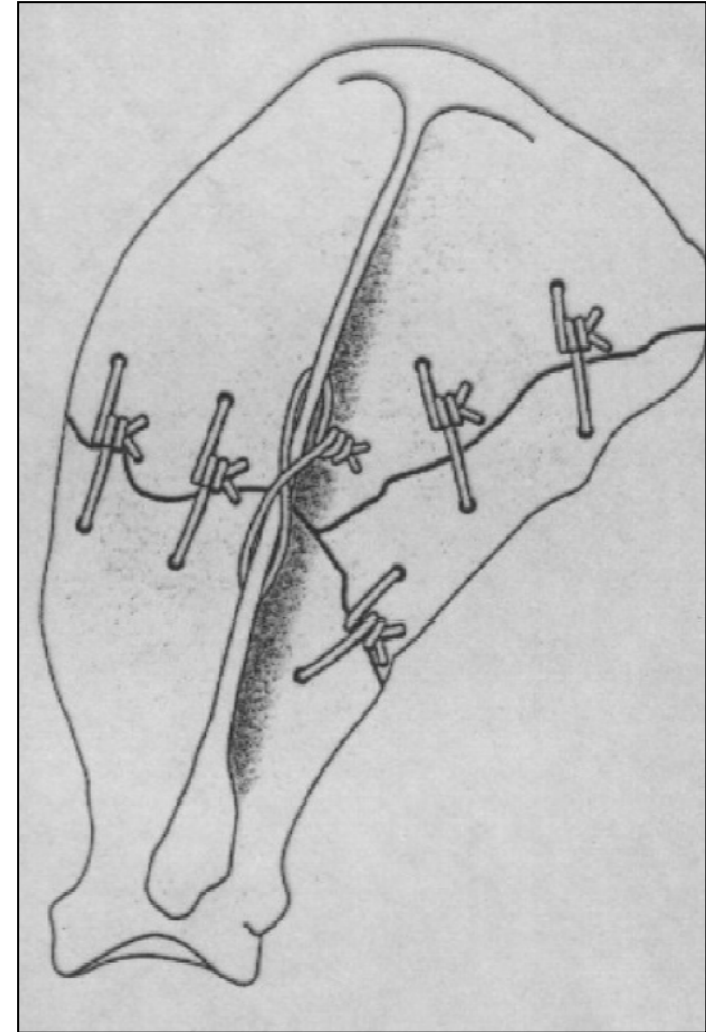
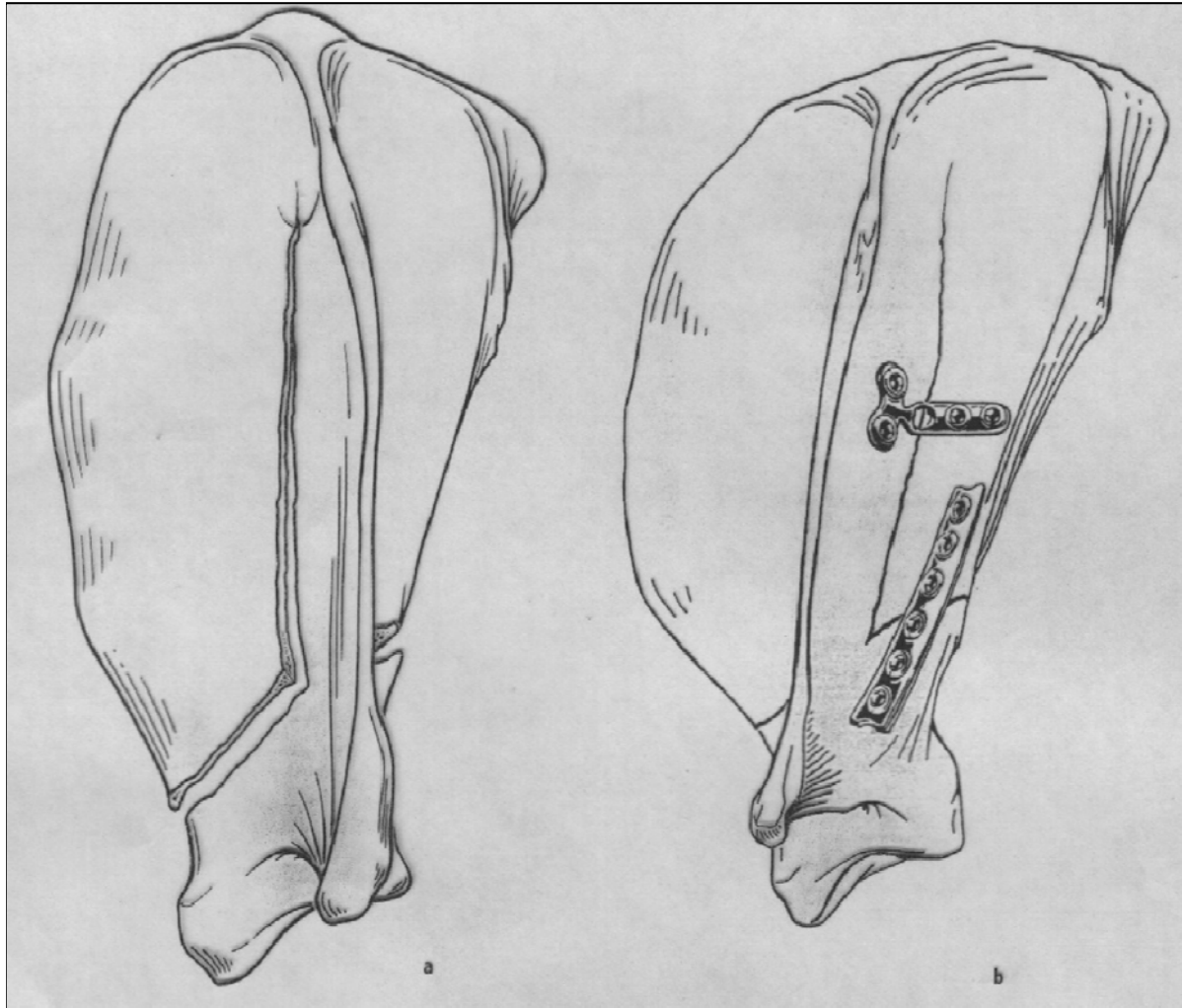
ΚΑΤΑΓΜΑΤΑ
Ειδικό μέρος

Πρόσθιο άκρο

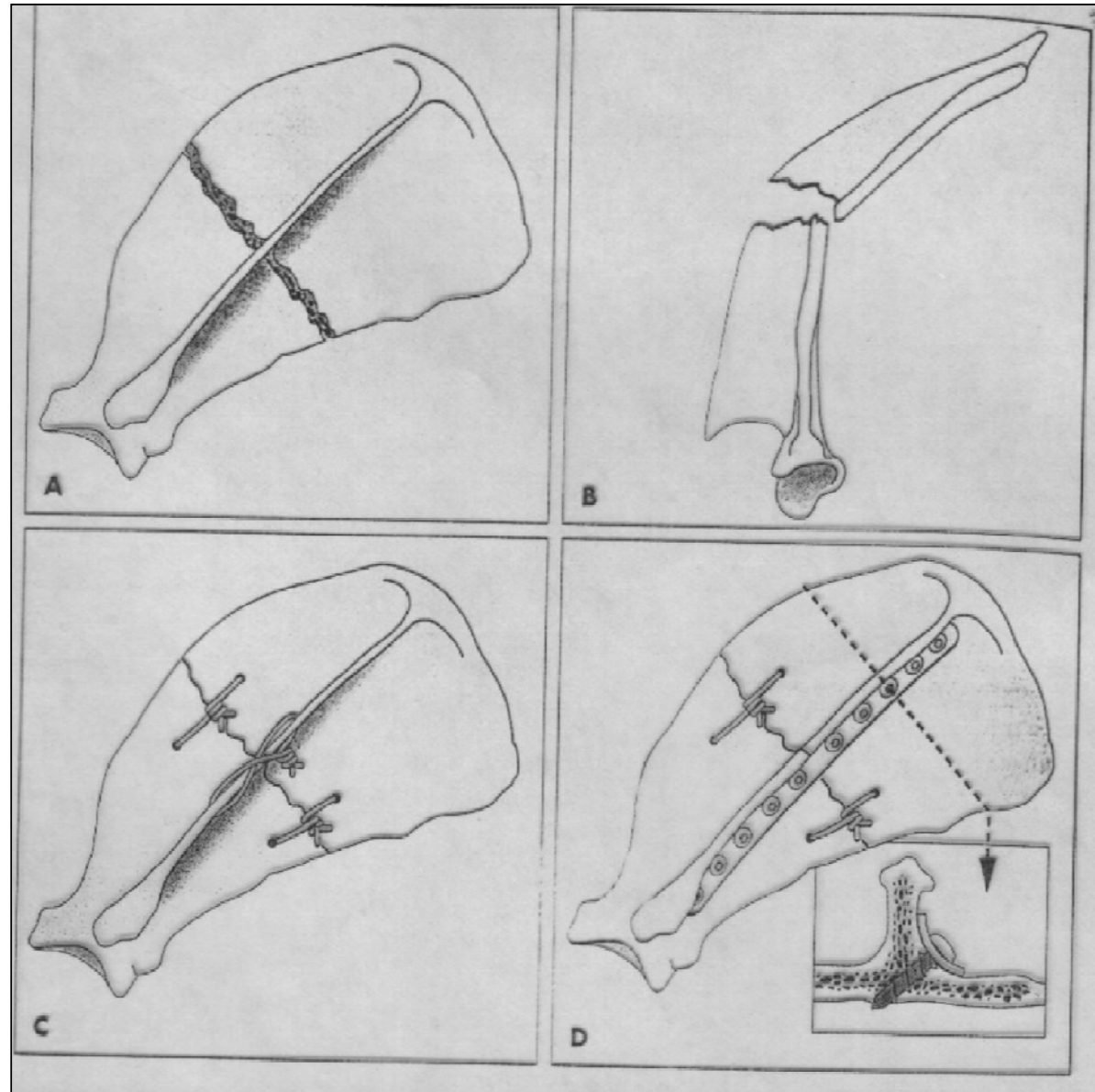
Ωμοπλάτη



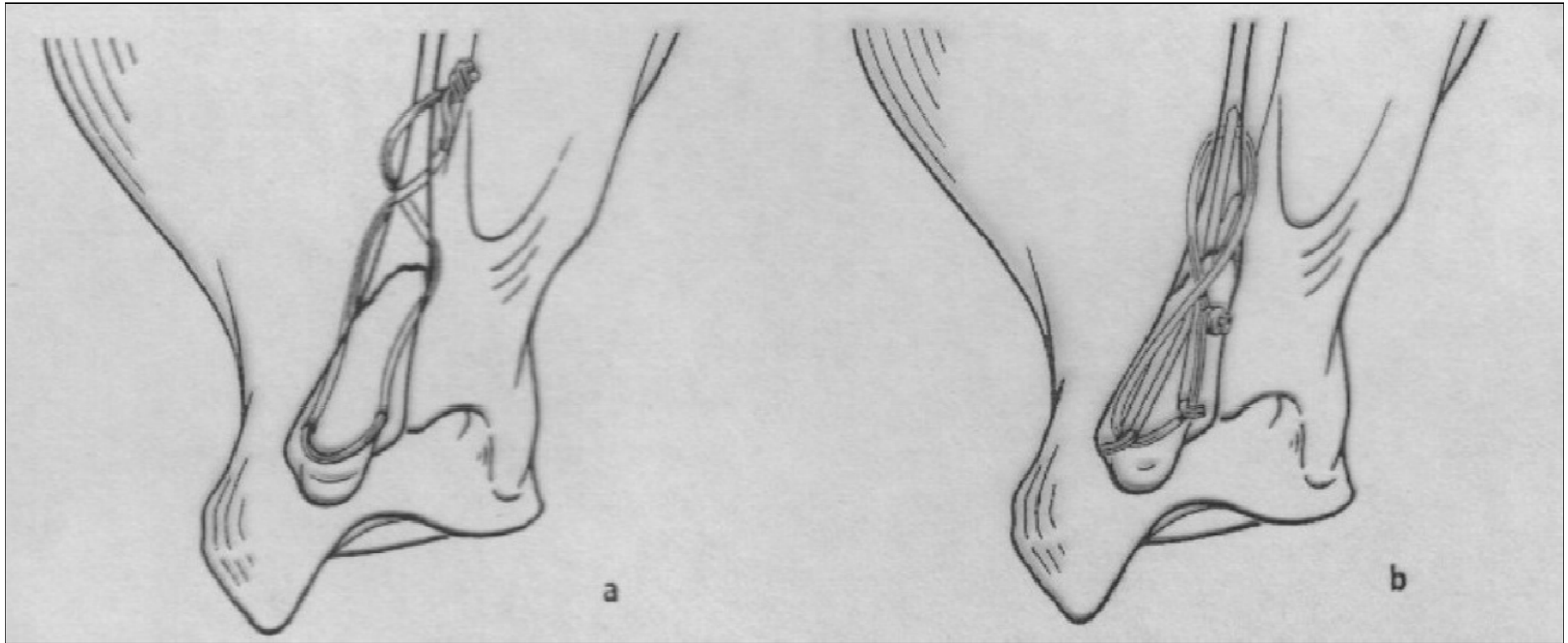
Ωμοπλάτη



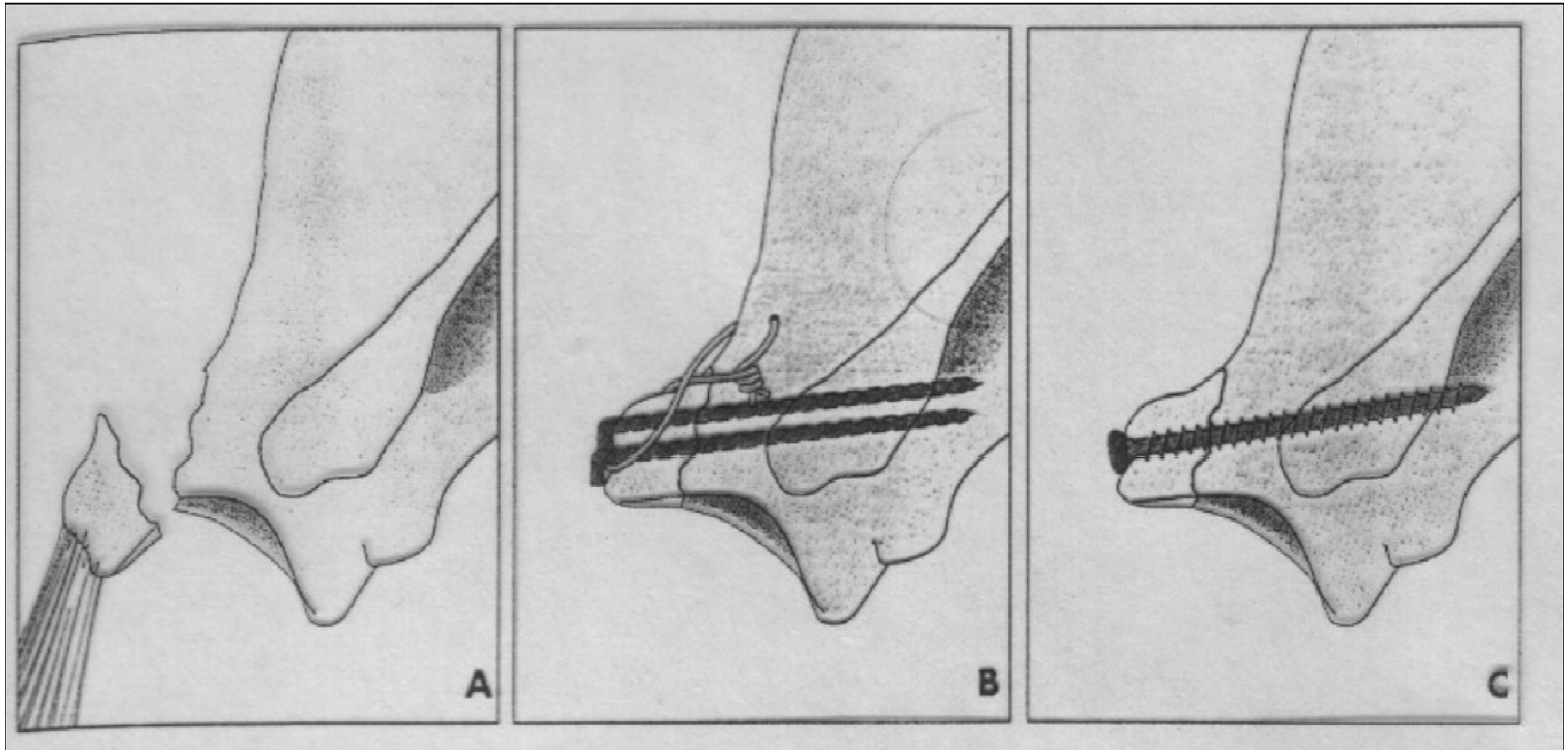
Ωμοπλάτη



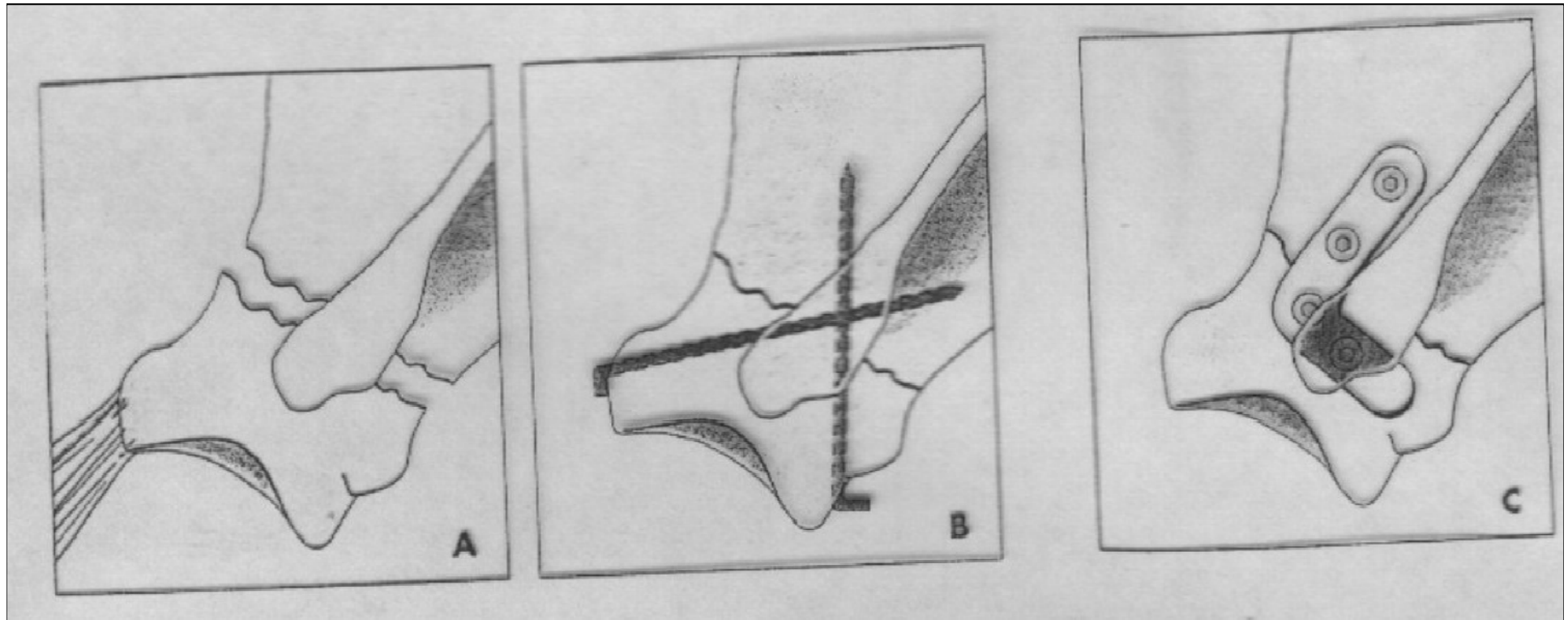
Ακρώμιο



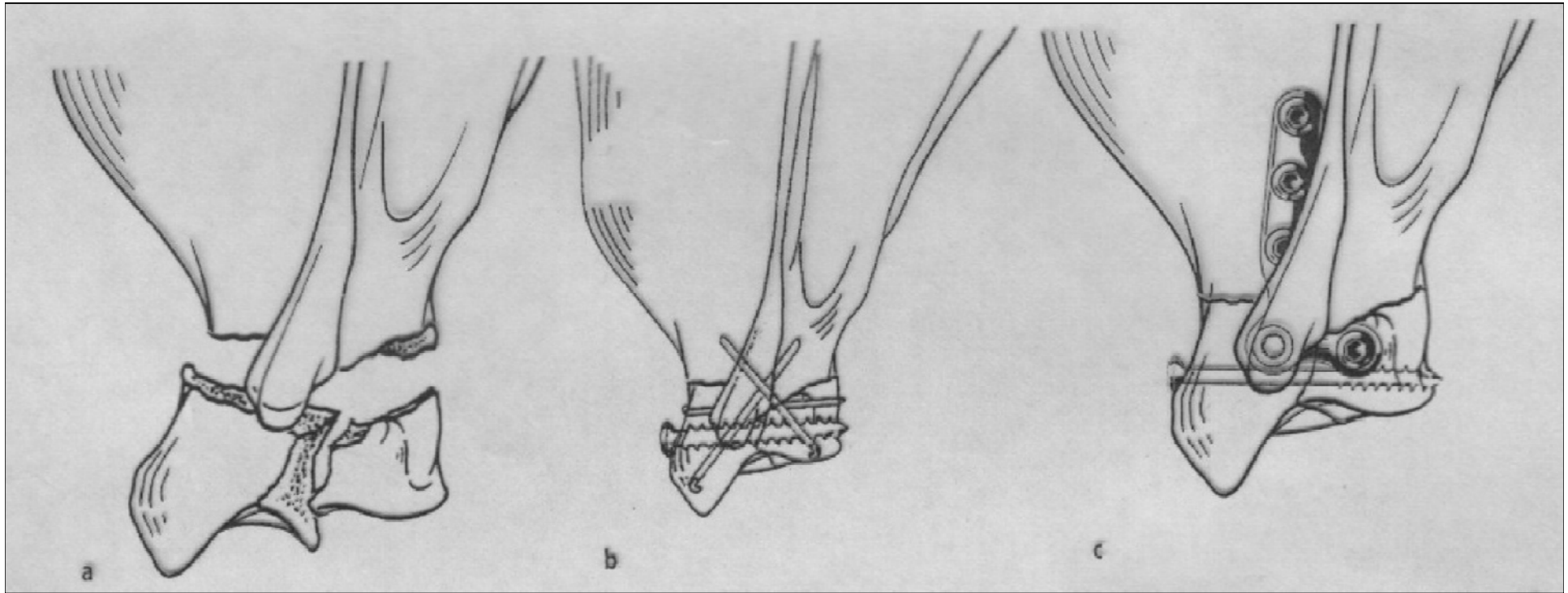
Υπεργλήνιο φύμα



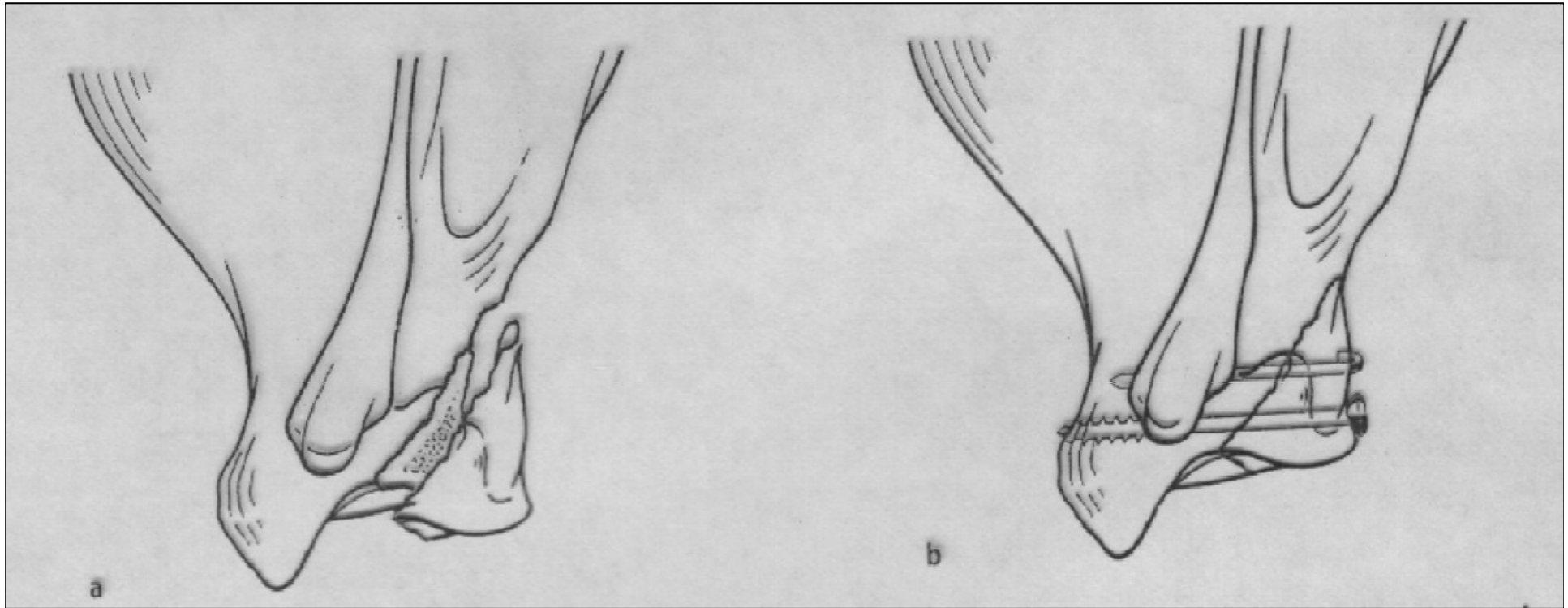
Αυχένας



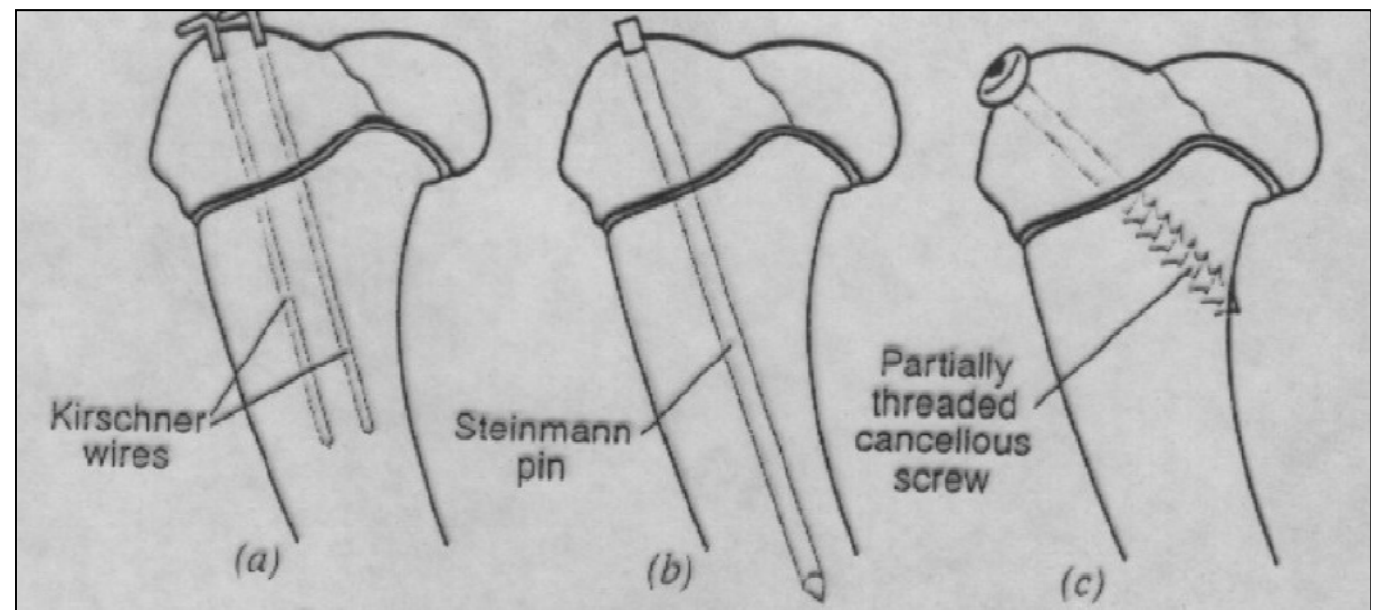
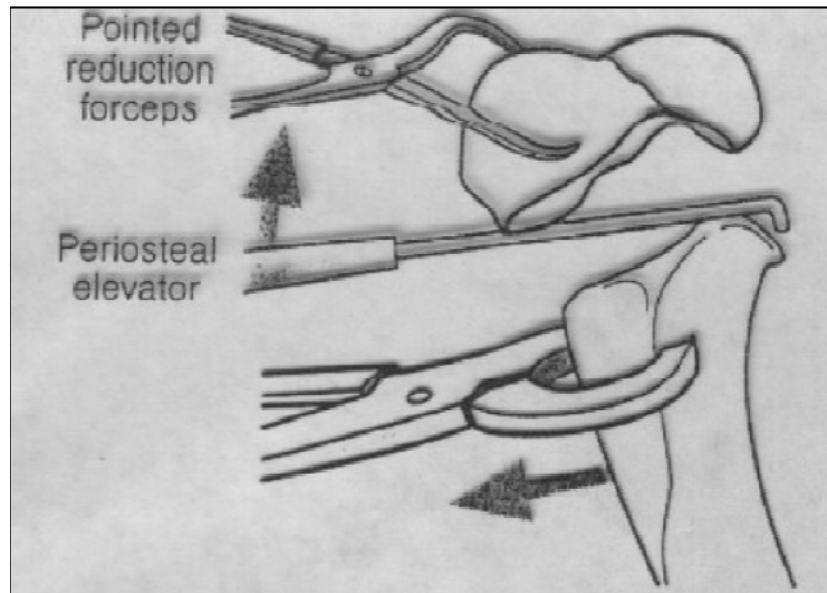
Κάτω γωνία



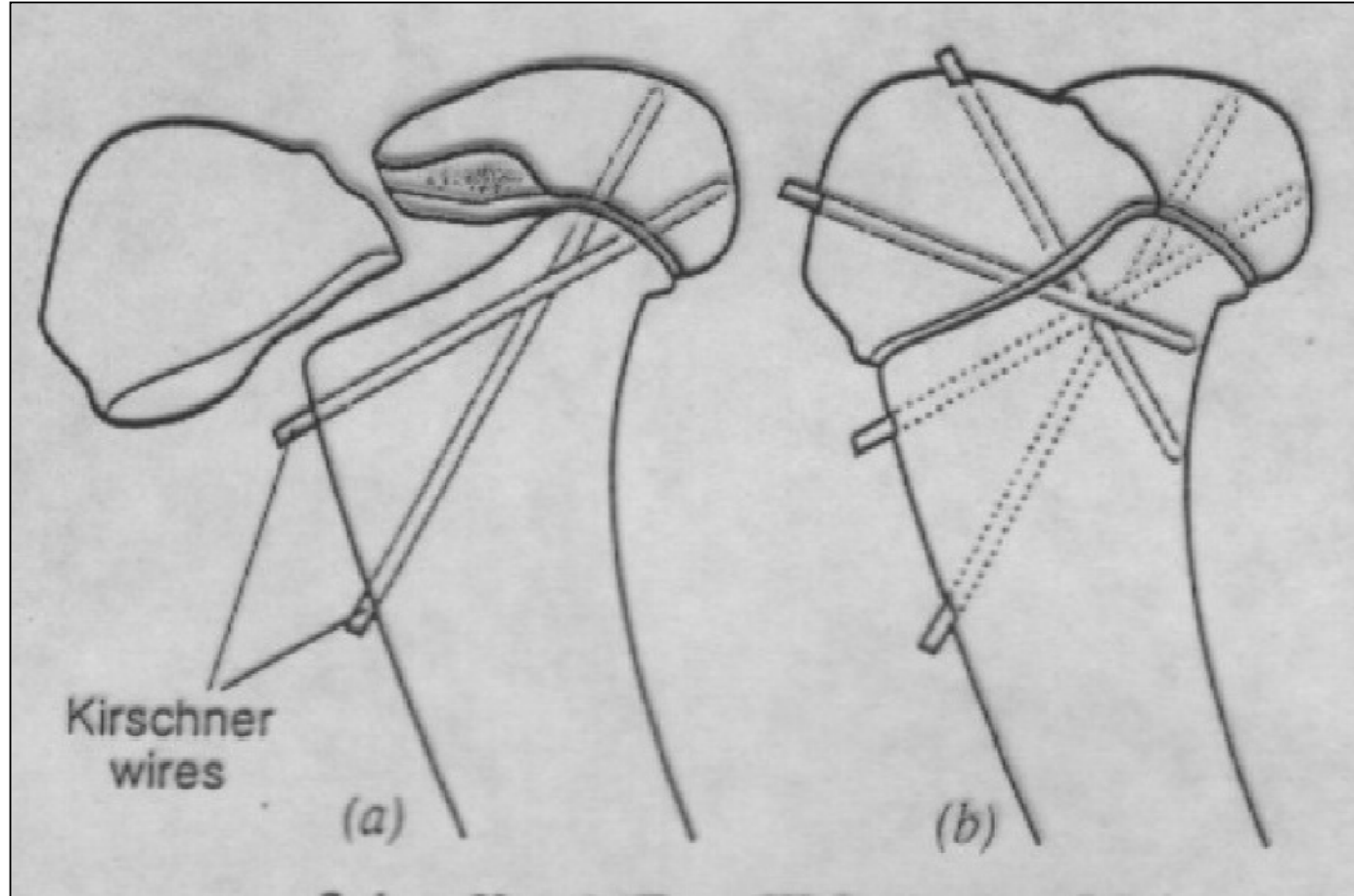
Κάτω γωνία



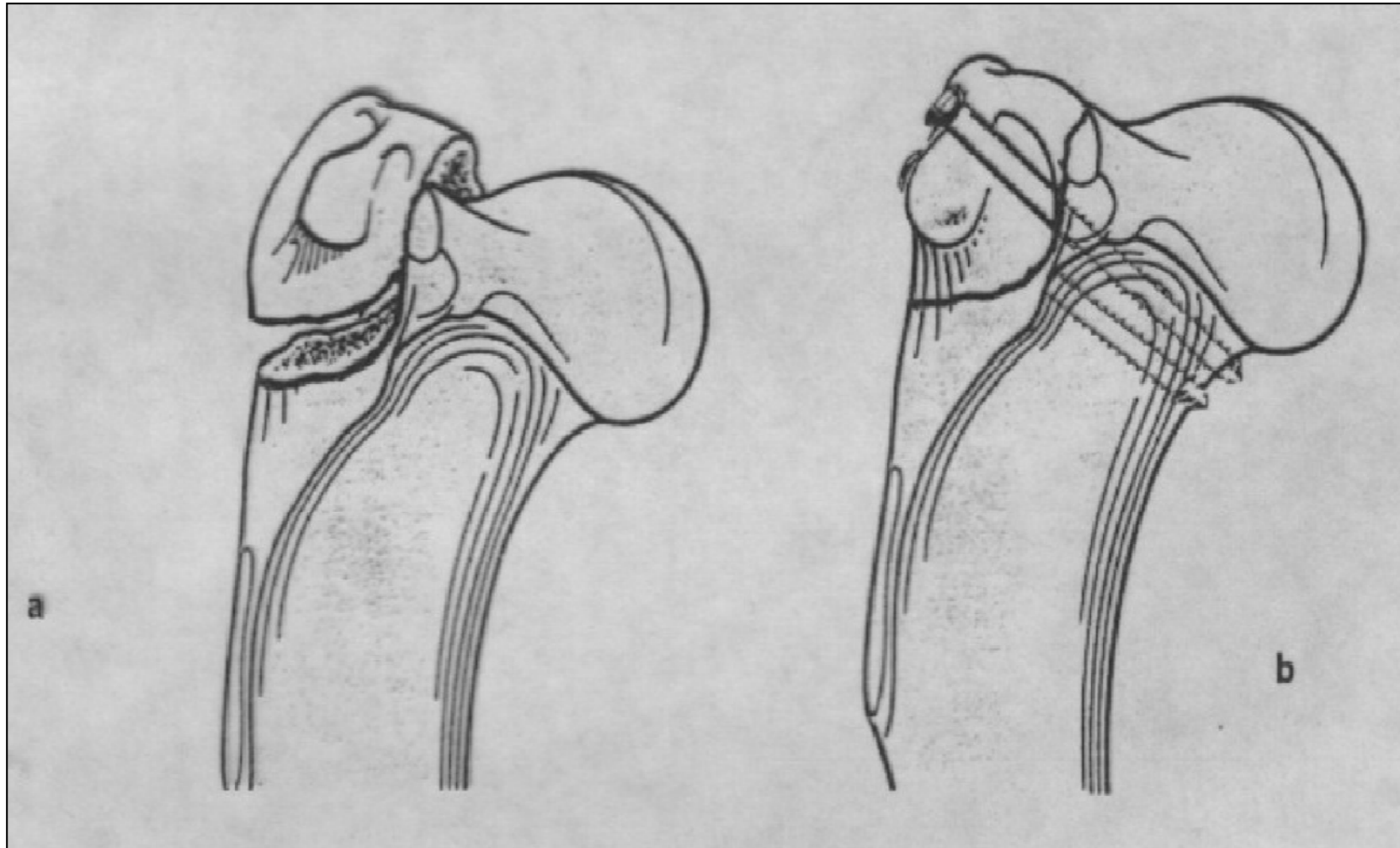
Κεντρική επίφυση - μετάφυση



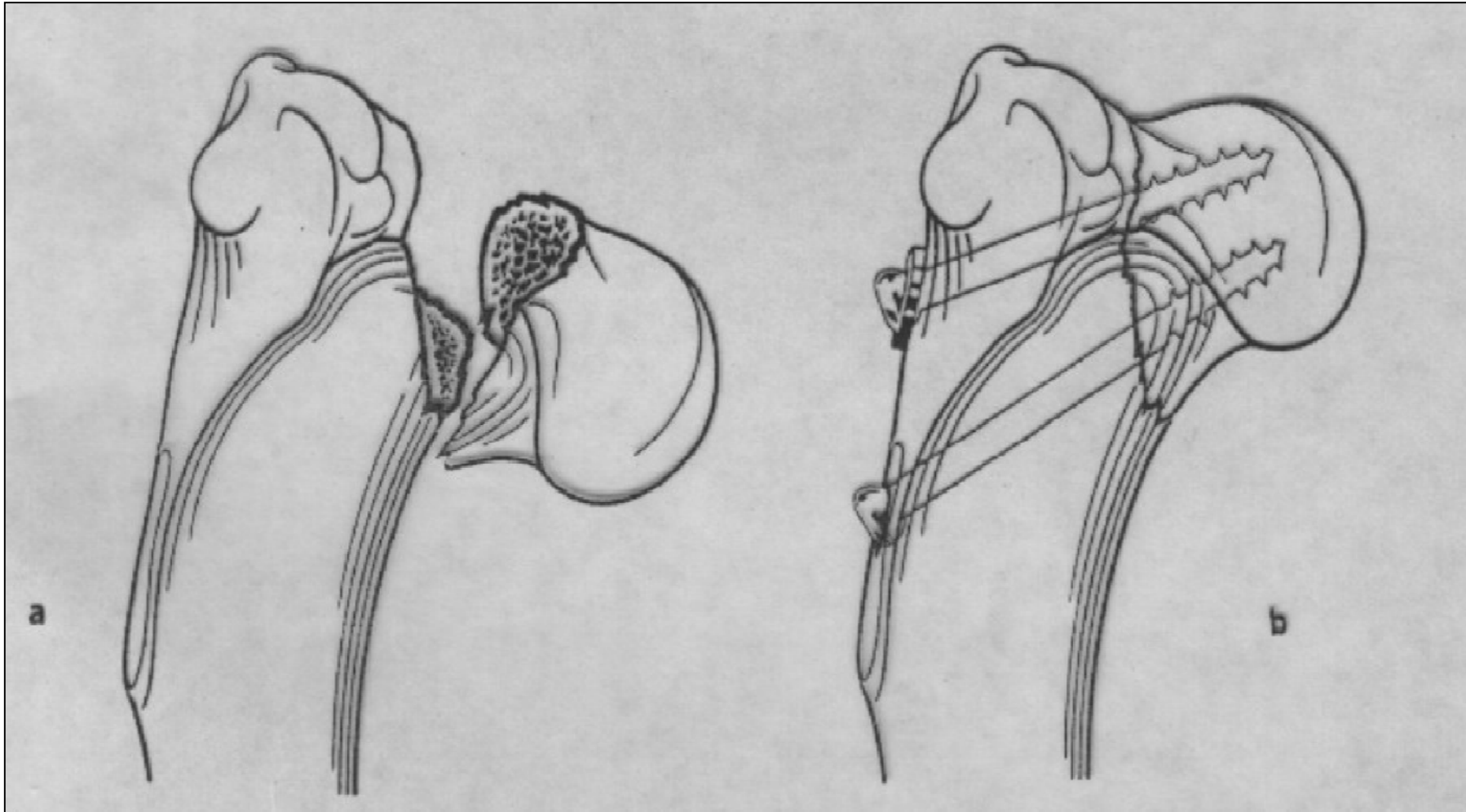
Κεντρική επίφυση - μετάφυση



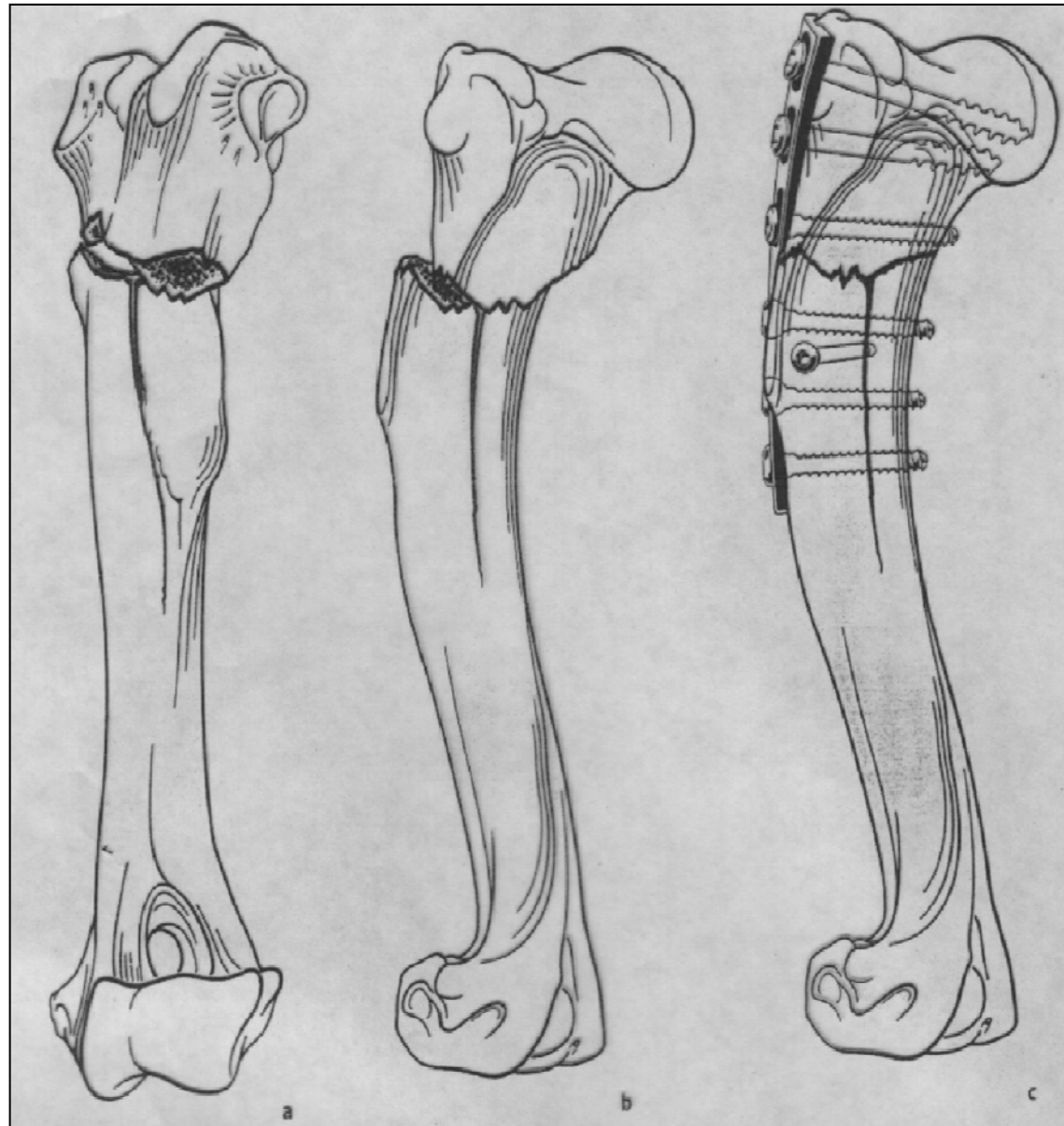
Μείζον βραχιόνιο όγκωμα



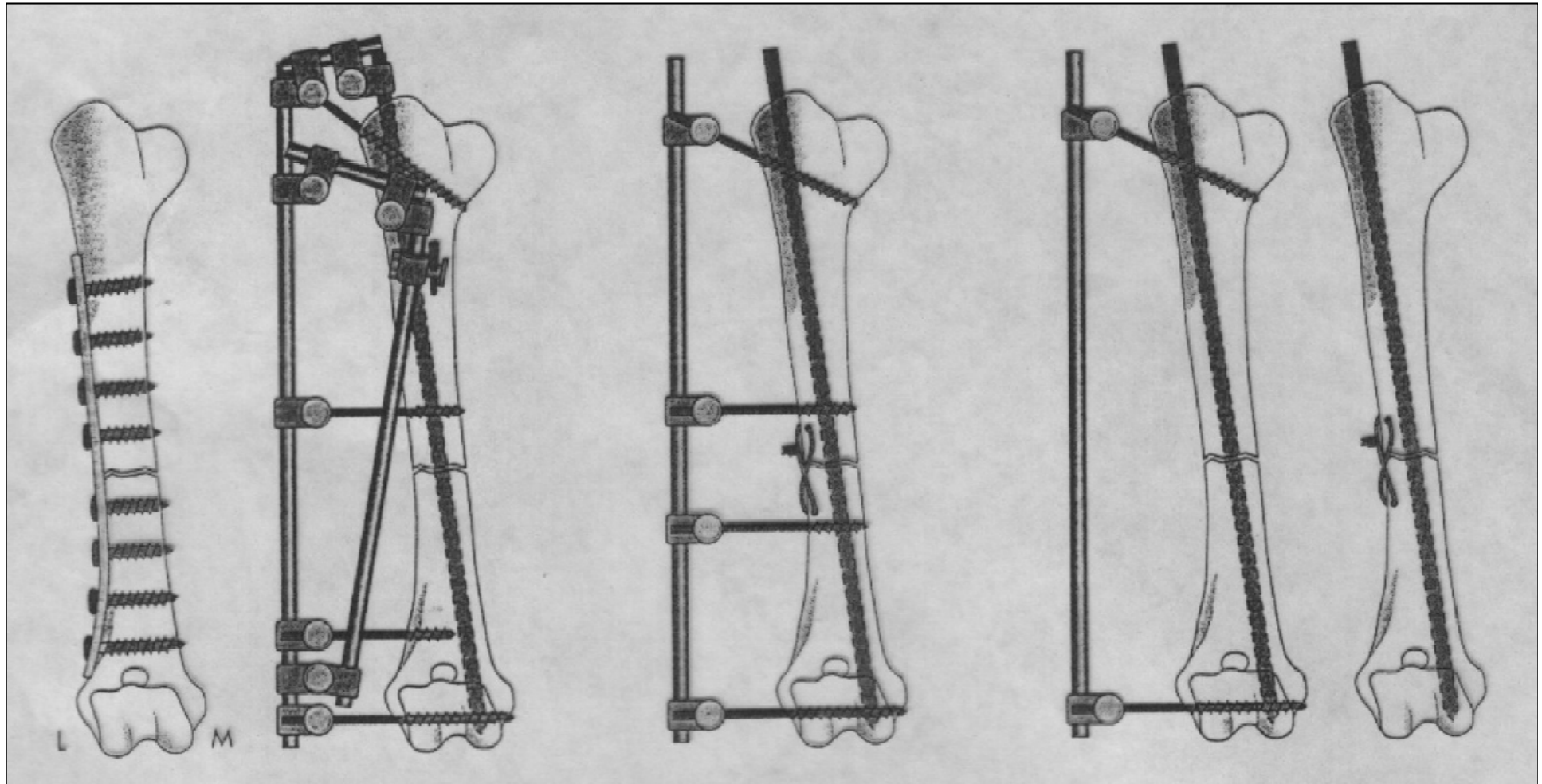
Κεφαλή



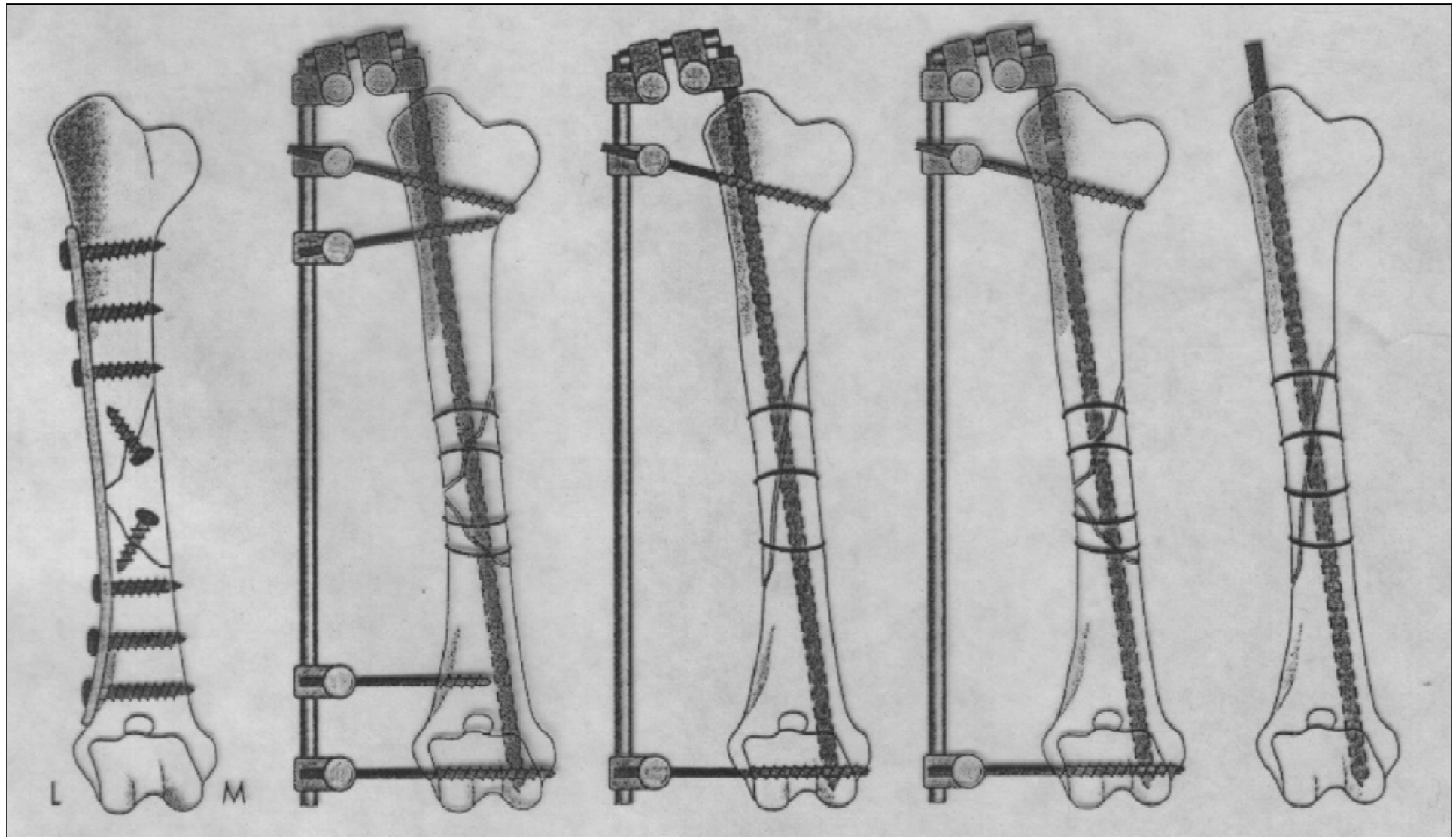
Κεντρική μετάφυση - διάφυση



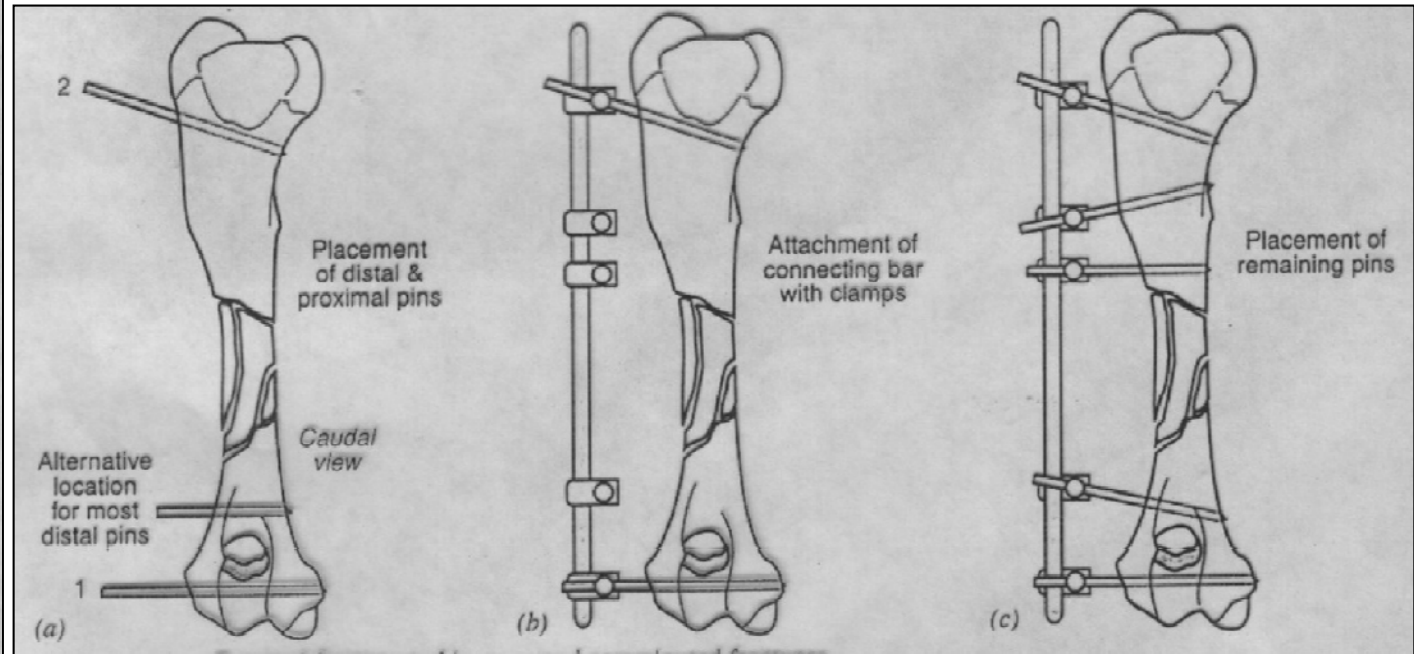
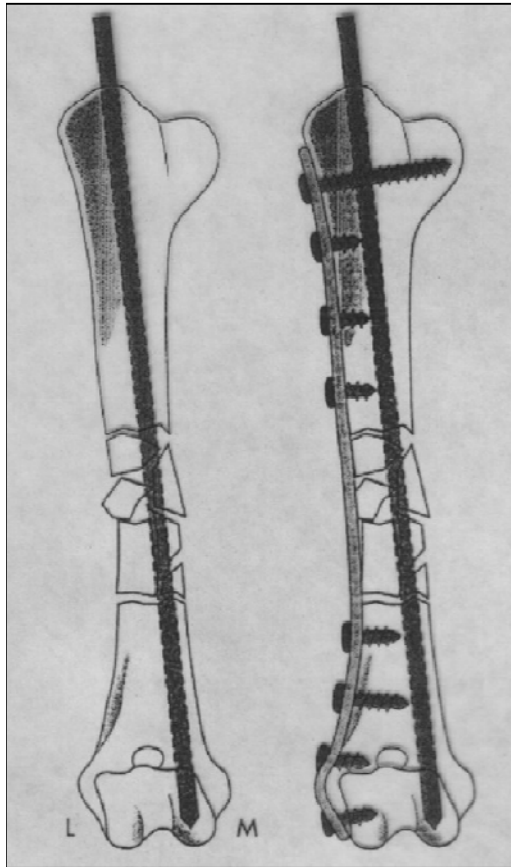
Διάφυση



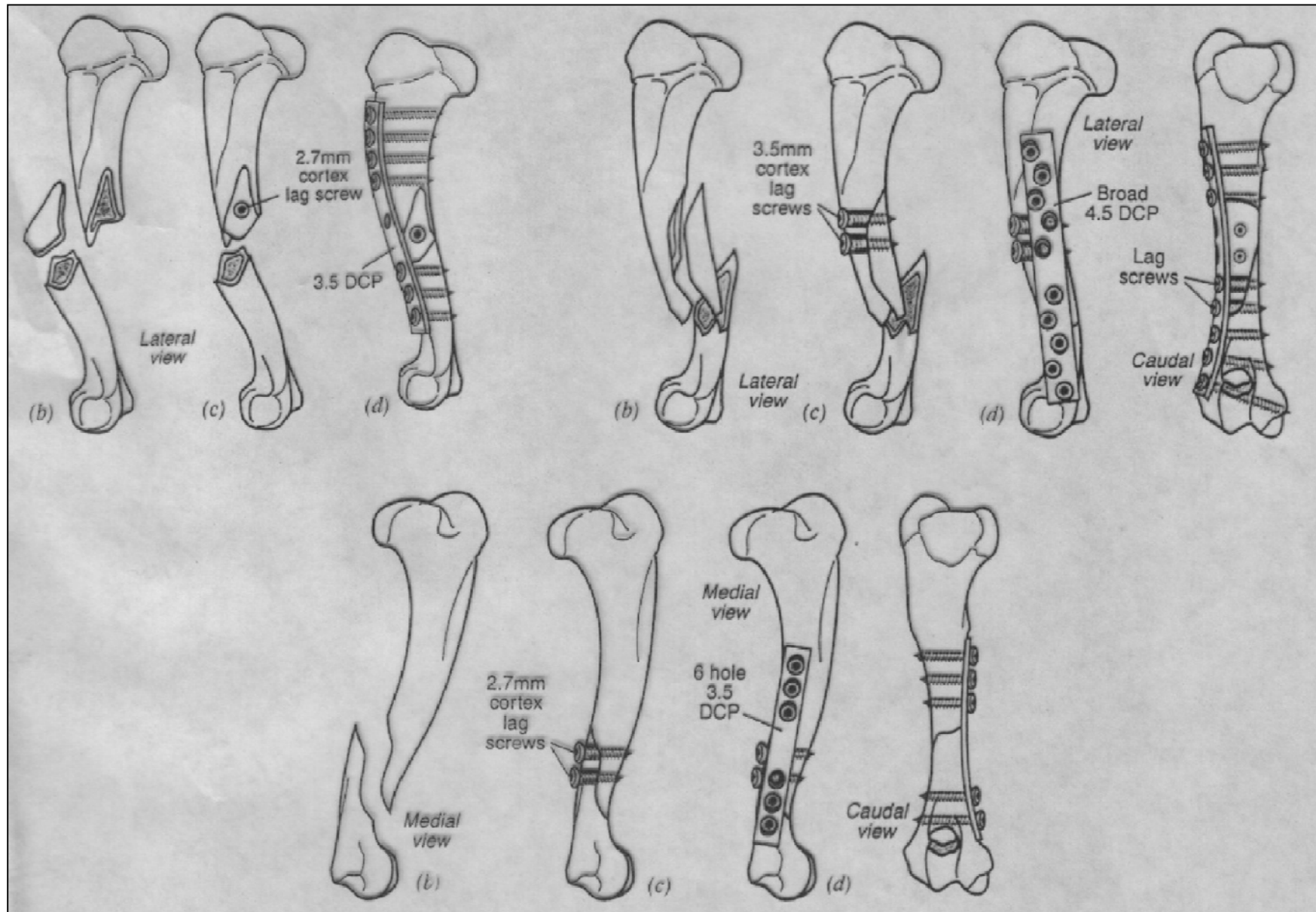
Διάφυση



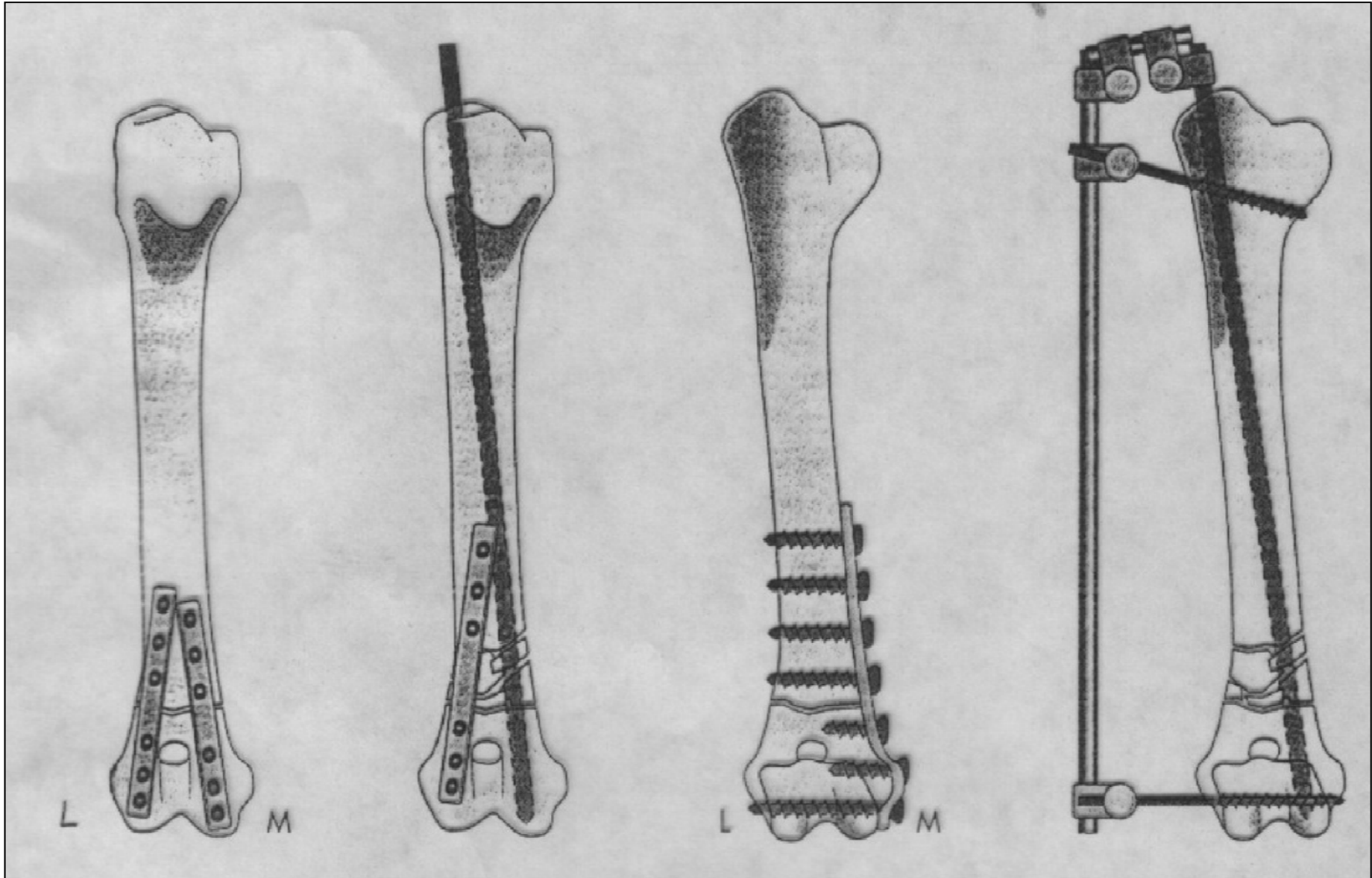
Διάφυση



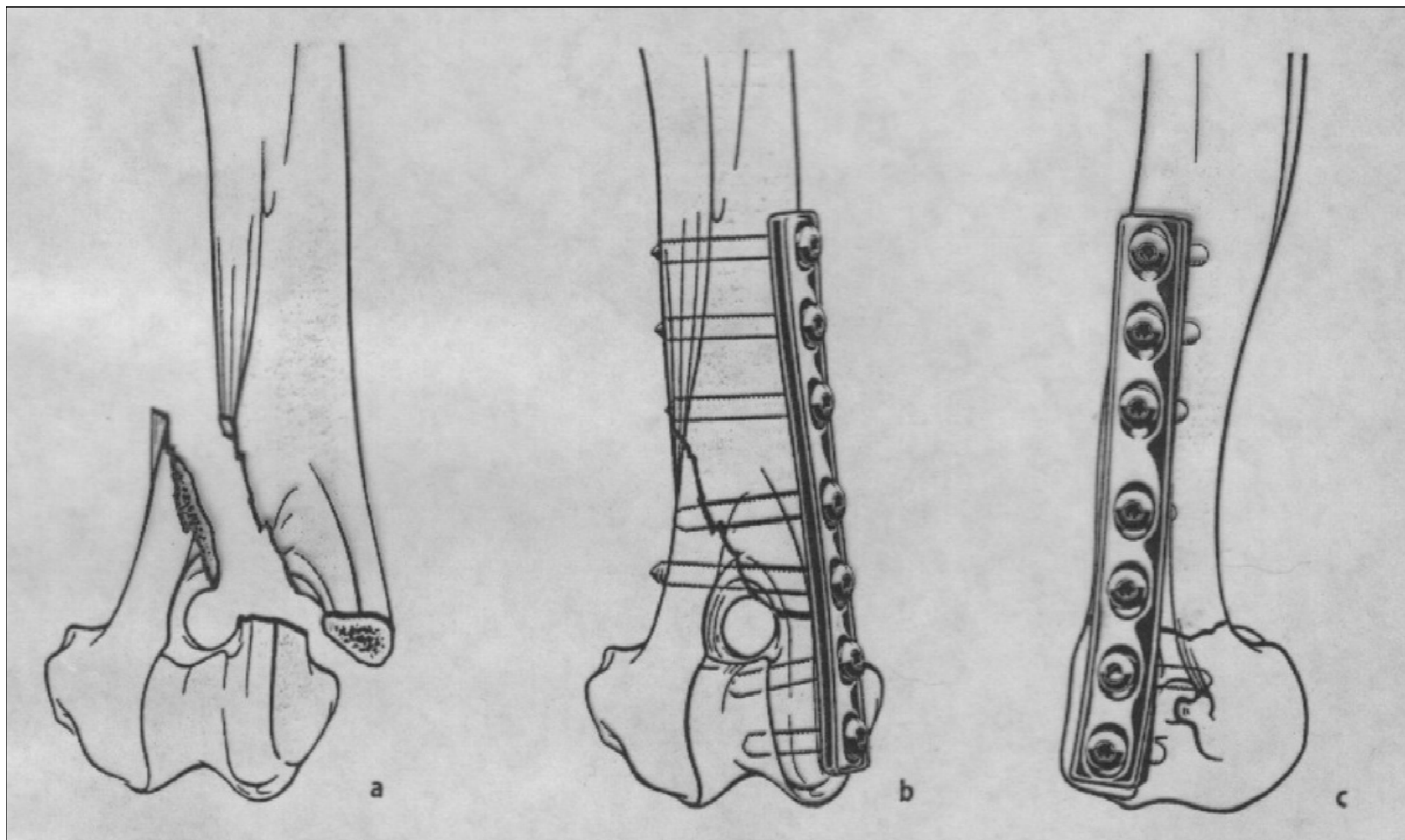
Διάφυση



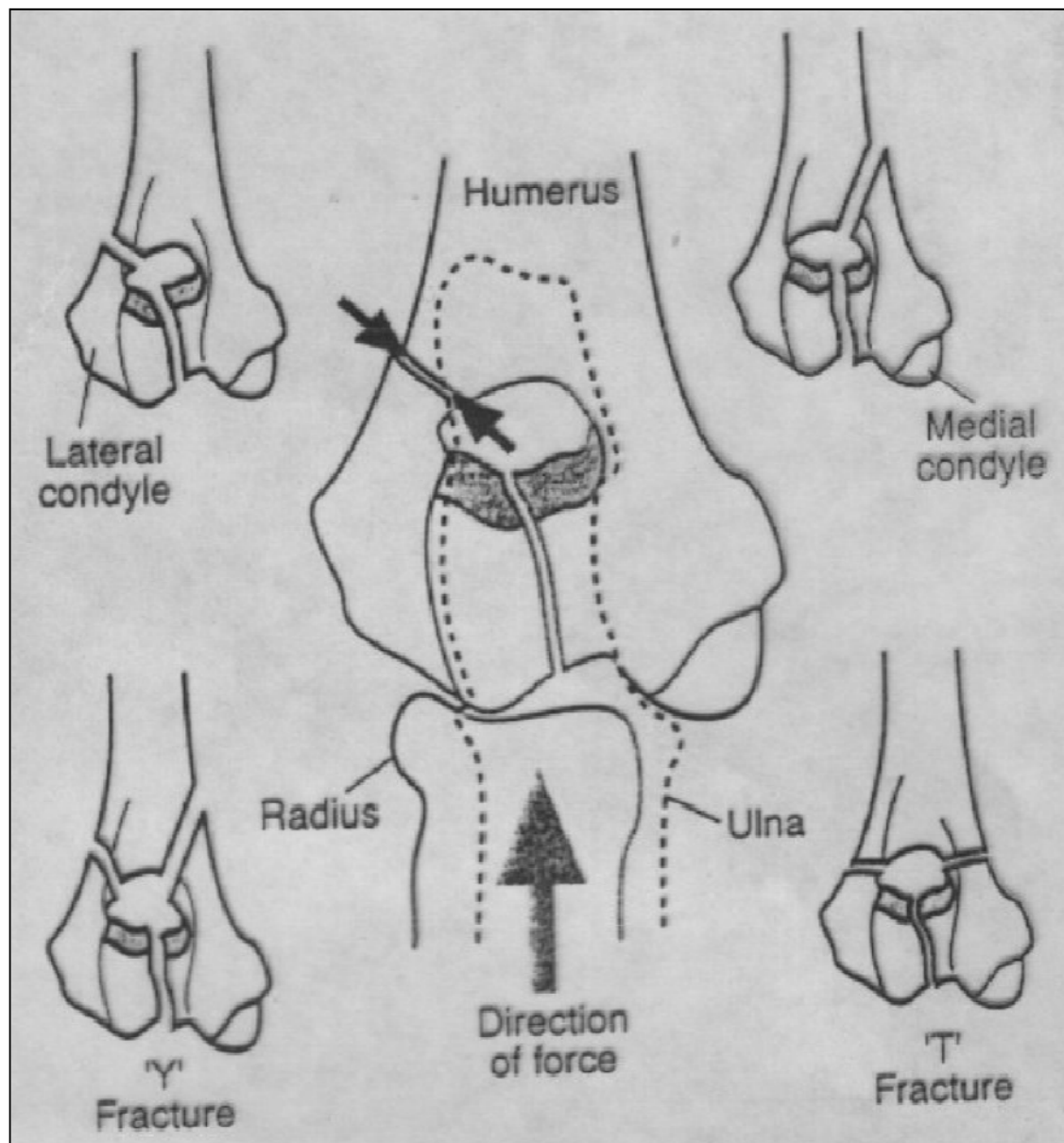
Περιφερική μετάφυση - διάφυση



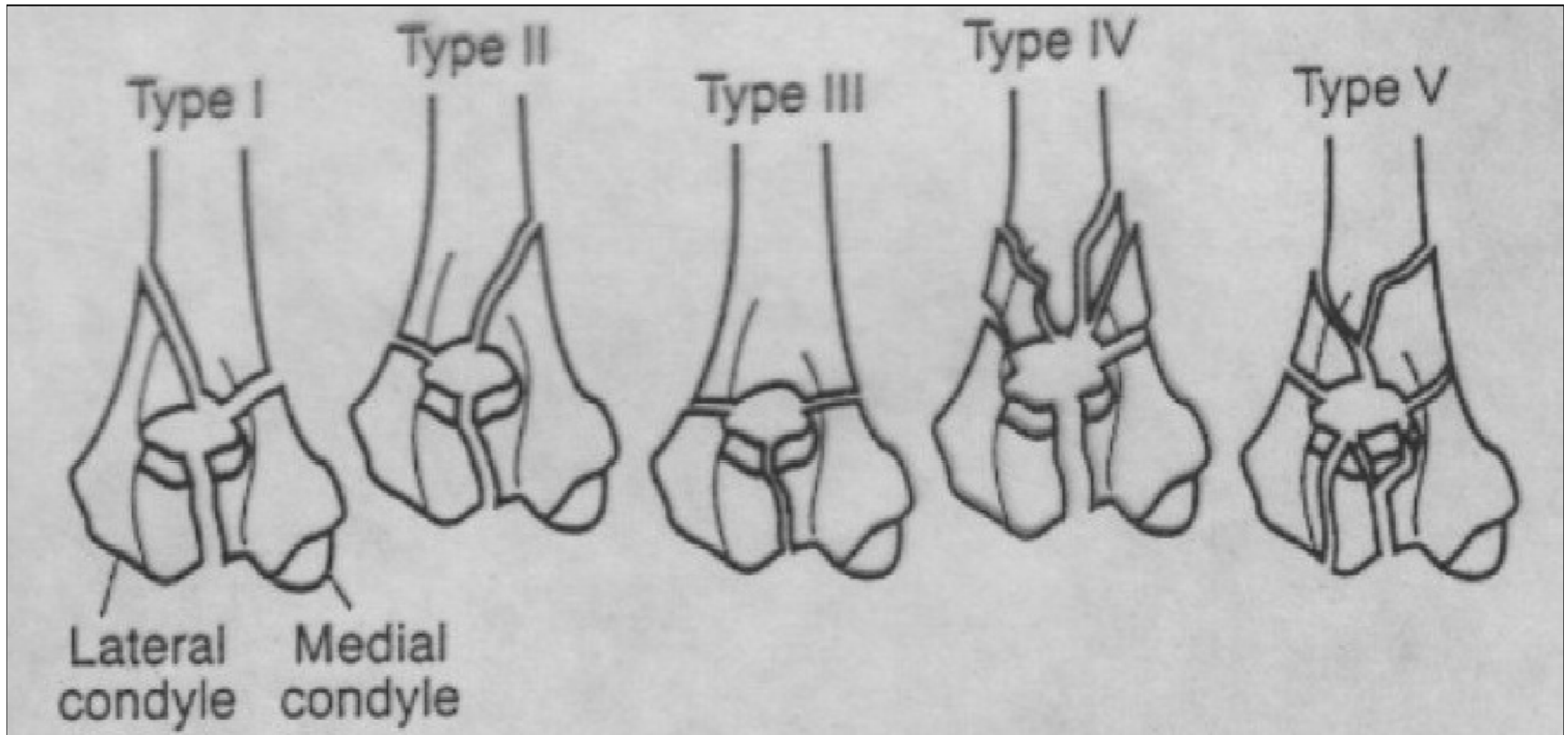
Περιφερική μετάφυση - διάφυση



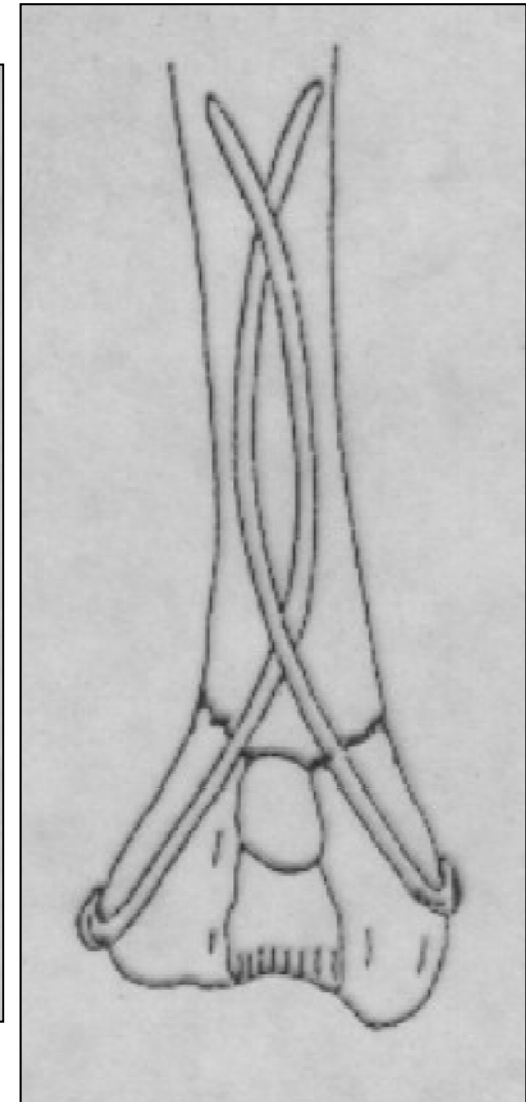
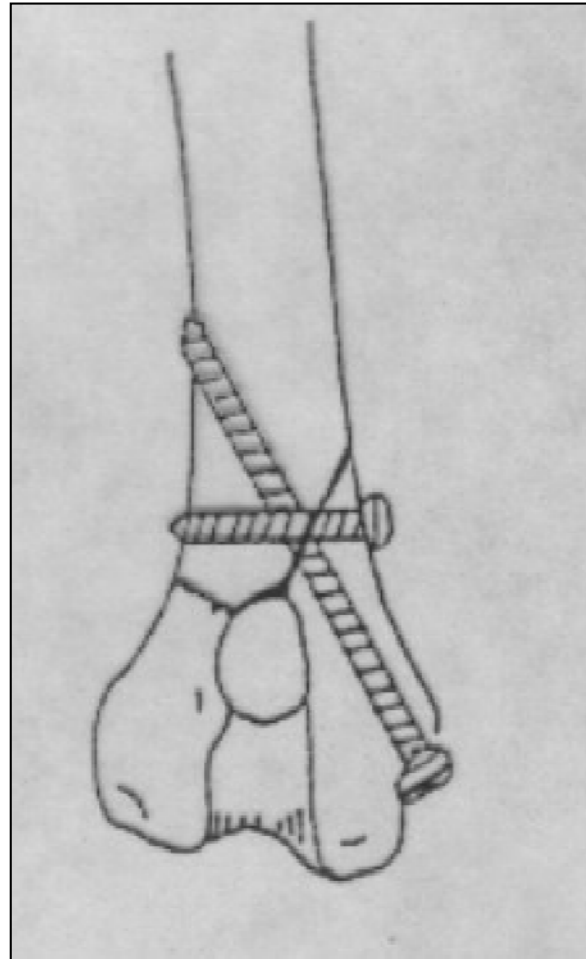
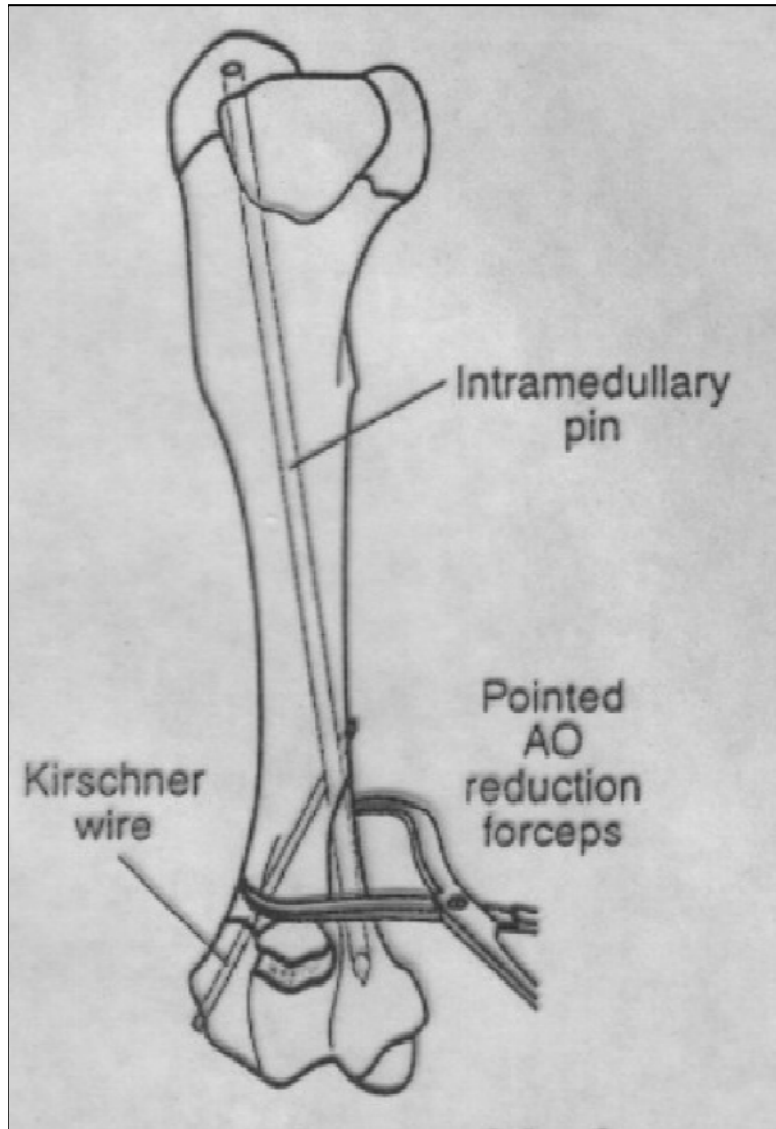
Υπερκονδύλια - μεσοκονδύλια κατάγματα



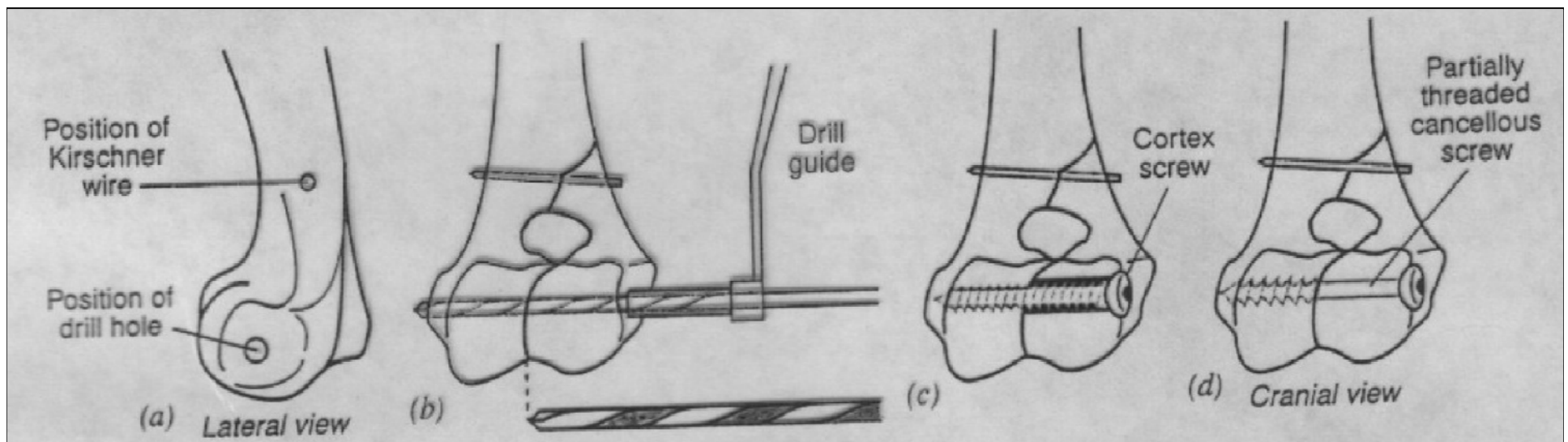
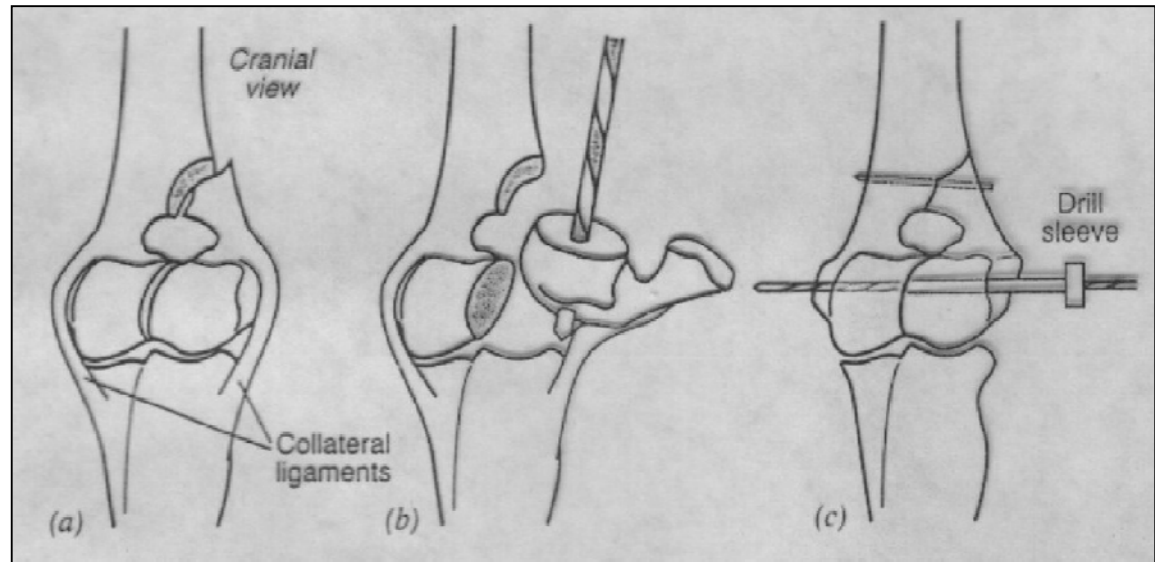
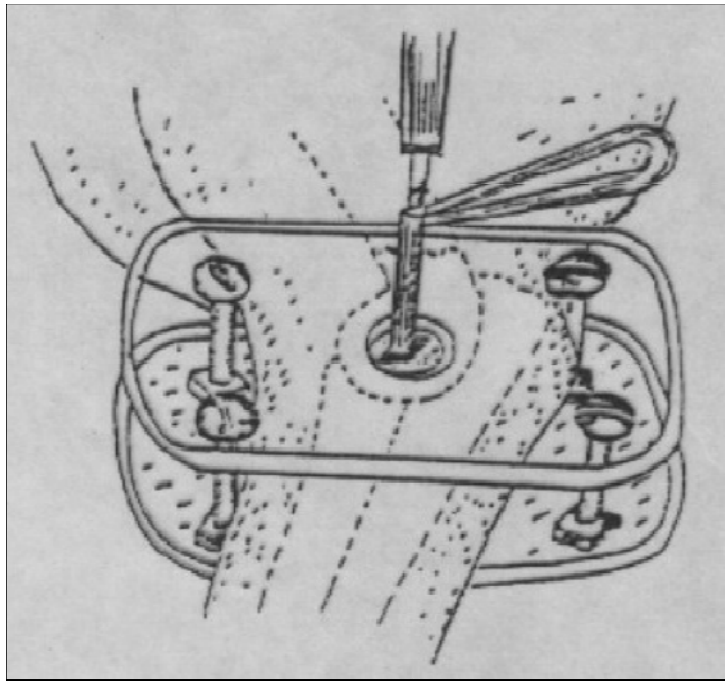
Υπερκονδύλια - μεσοκονδύλια κατάγματα



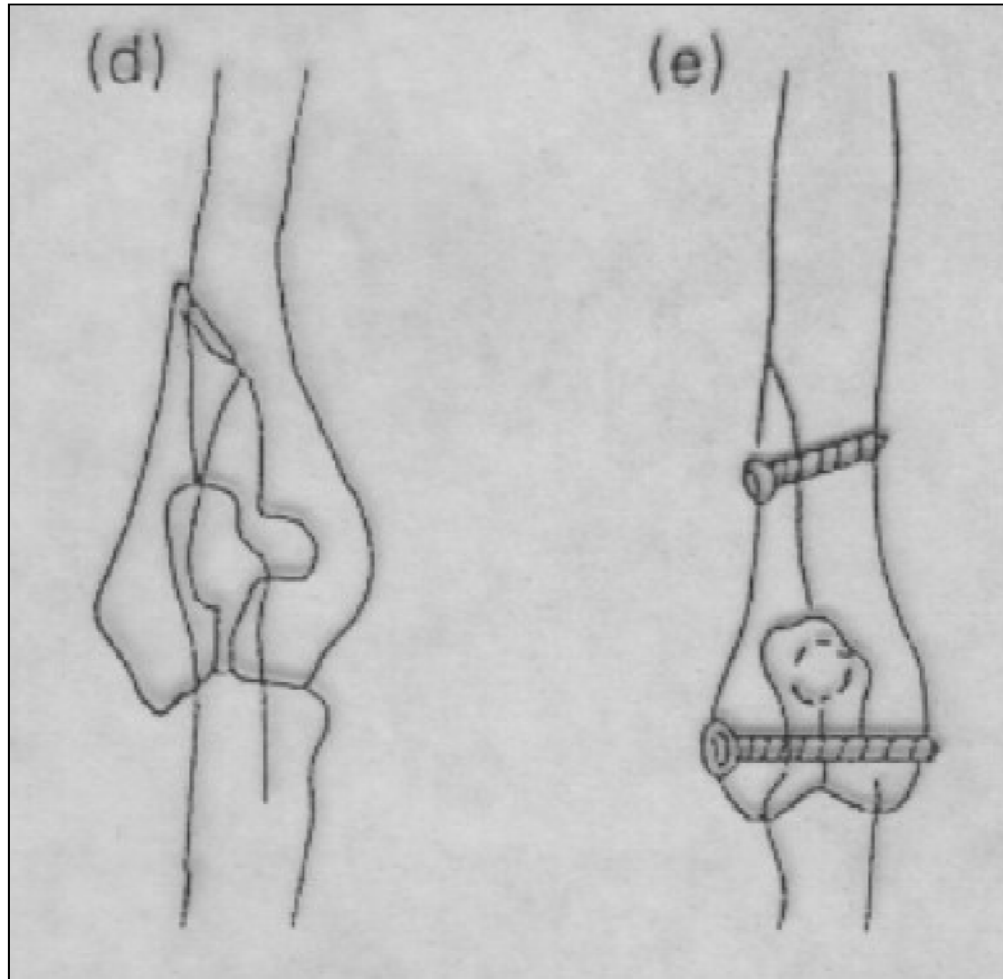
Υπερκονδύλιο κάταγμα



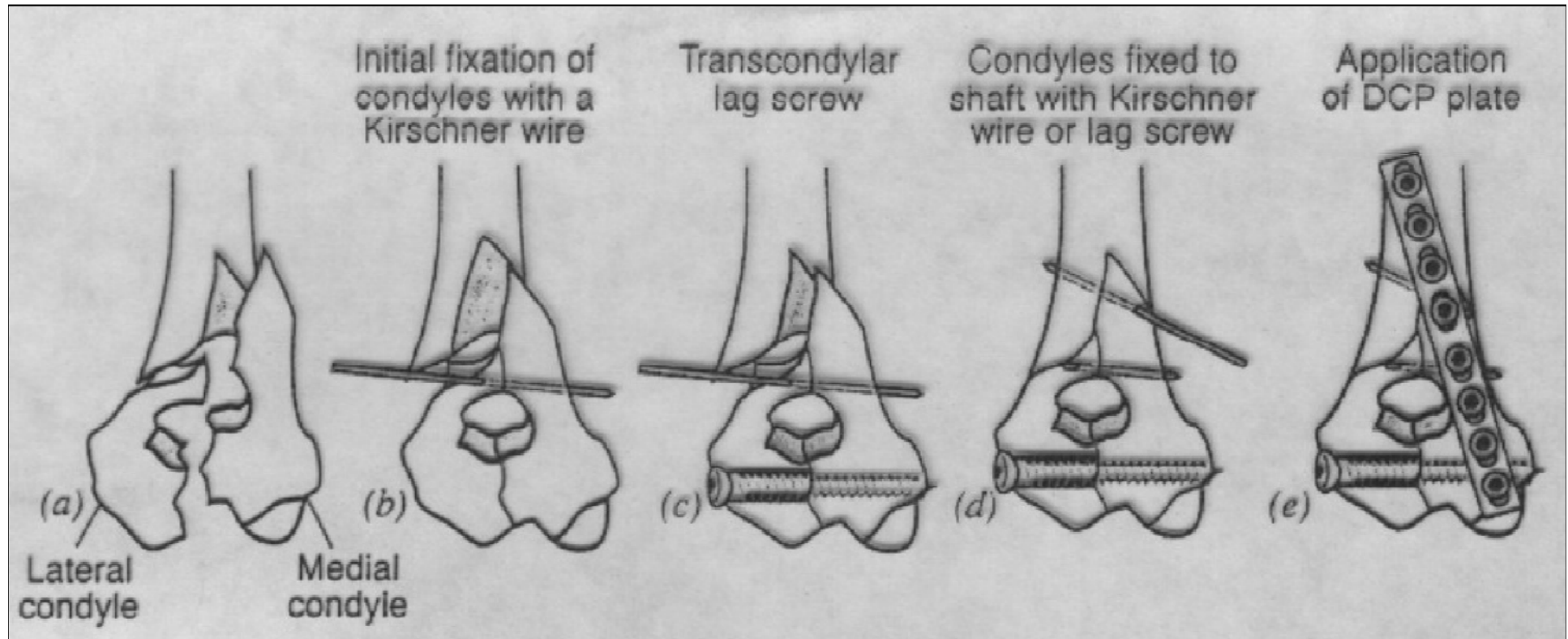
Μεσοκονδύλιο κάταγμα



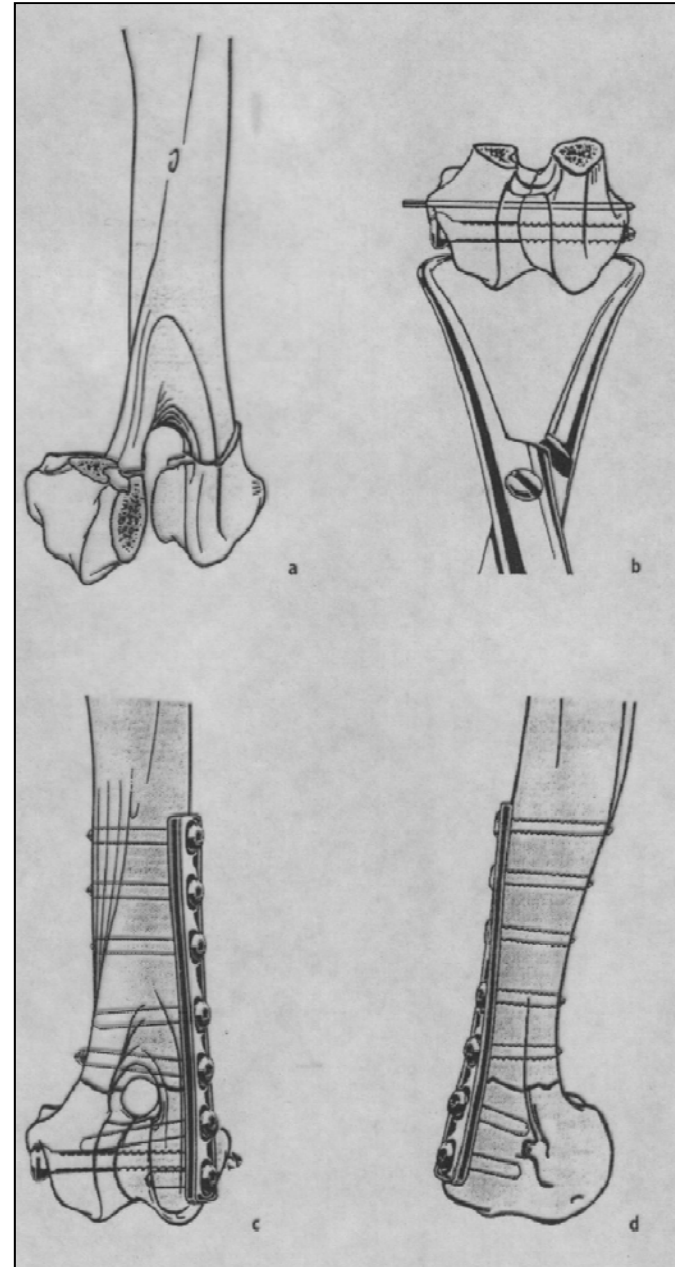
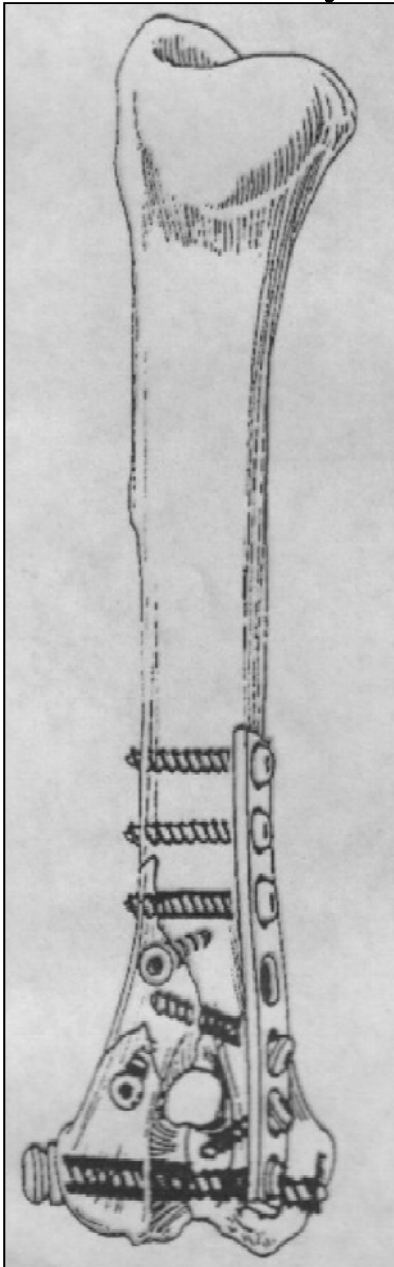
Μεσοκονδύλιο κάταγμα



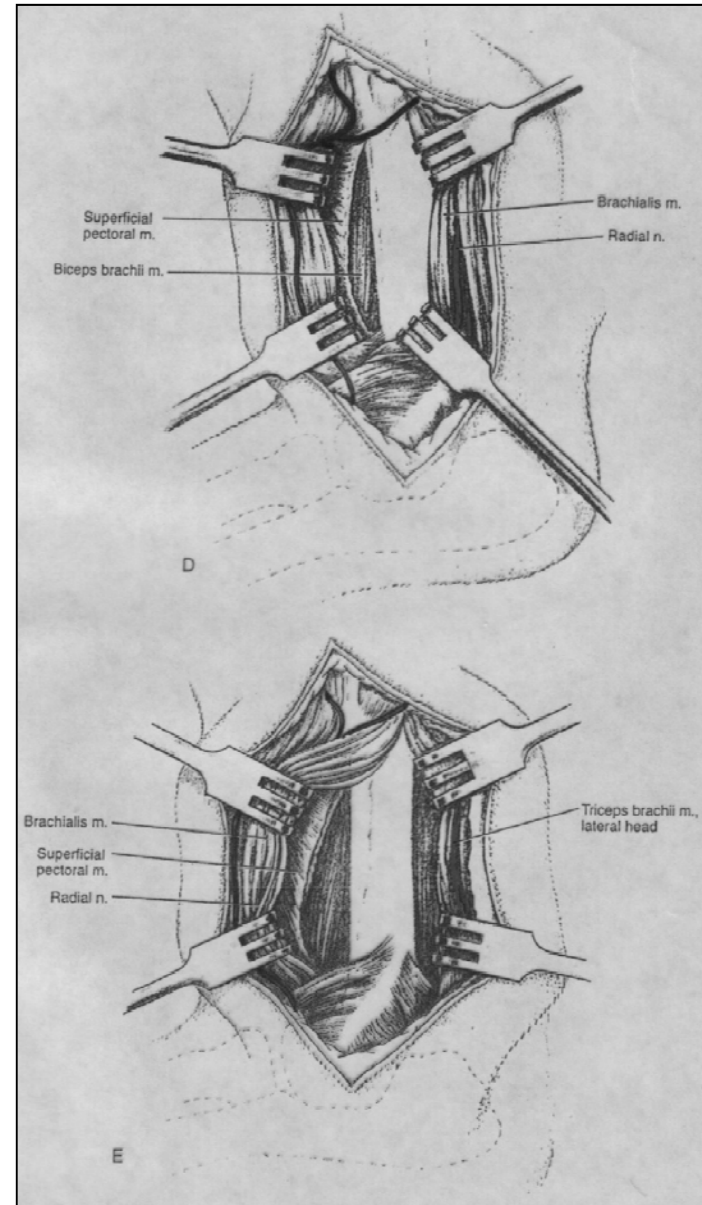
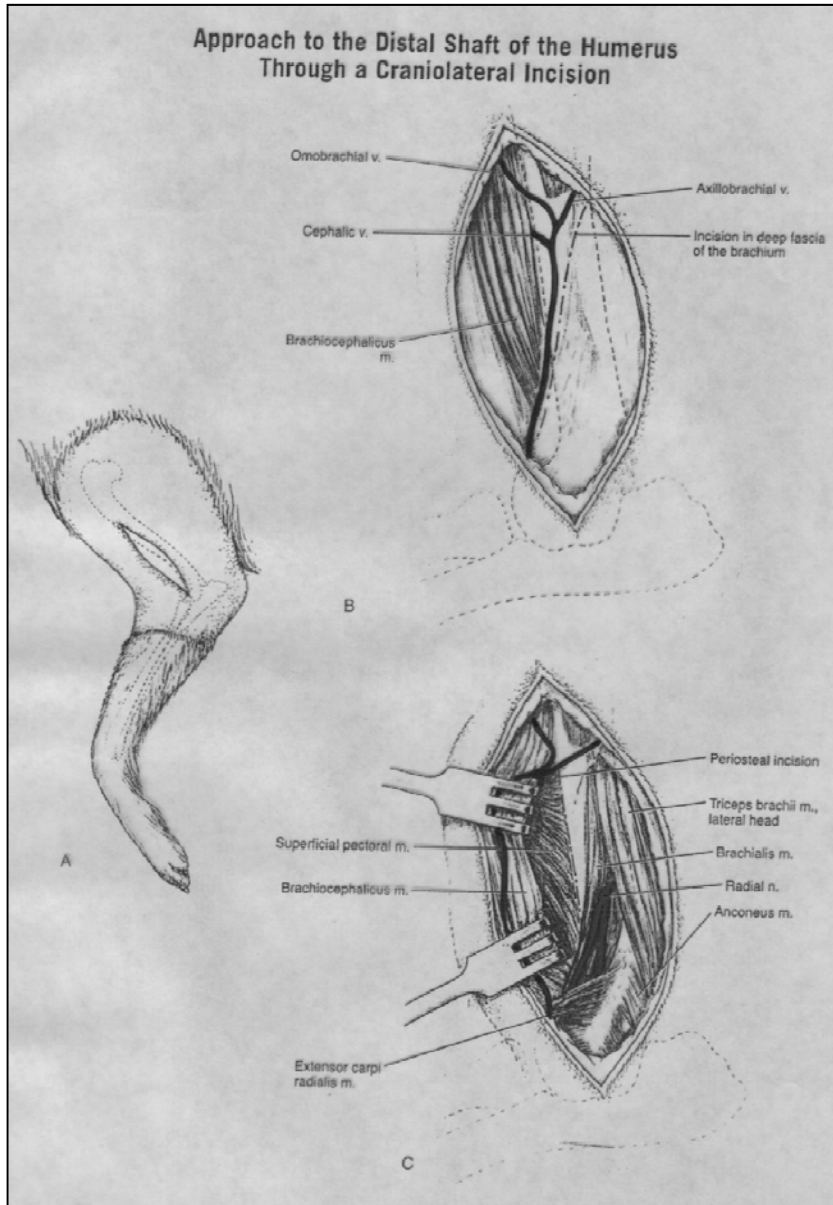
Υπερκονδύλιο - μεσοκονδύλιο κάταγμα



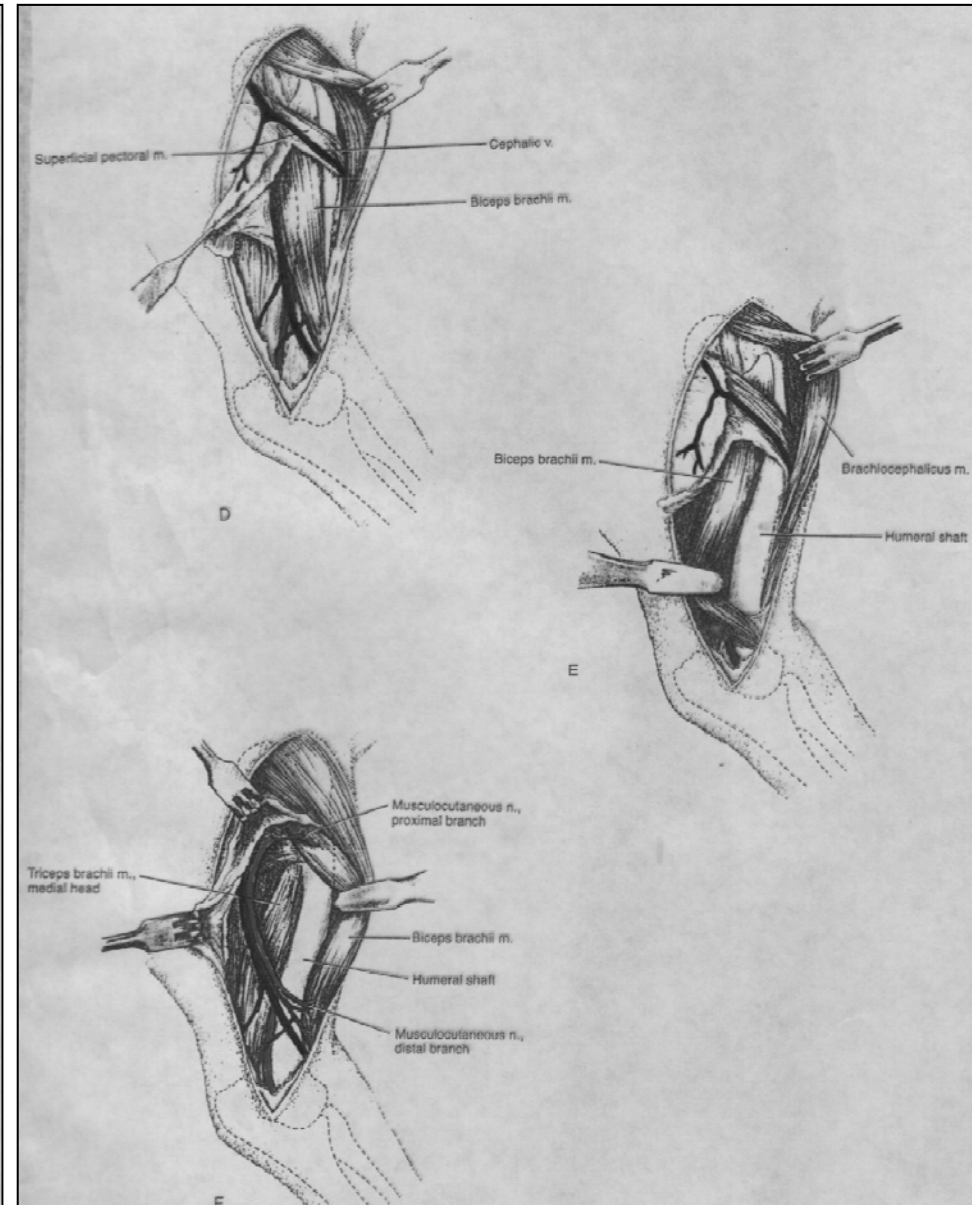
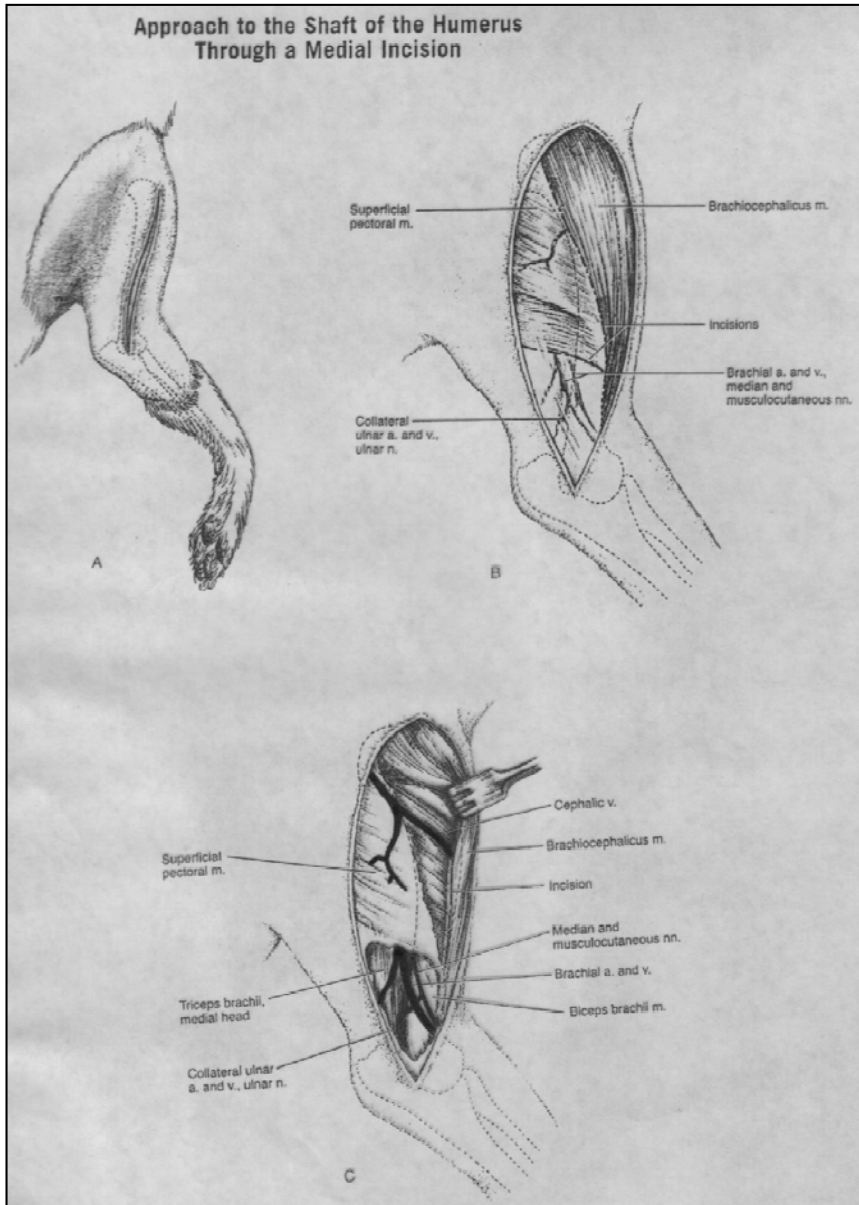
Υπερκονδύλιο - μεσοκονδύλιο κάταγμα



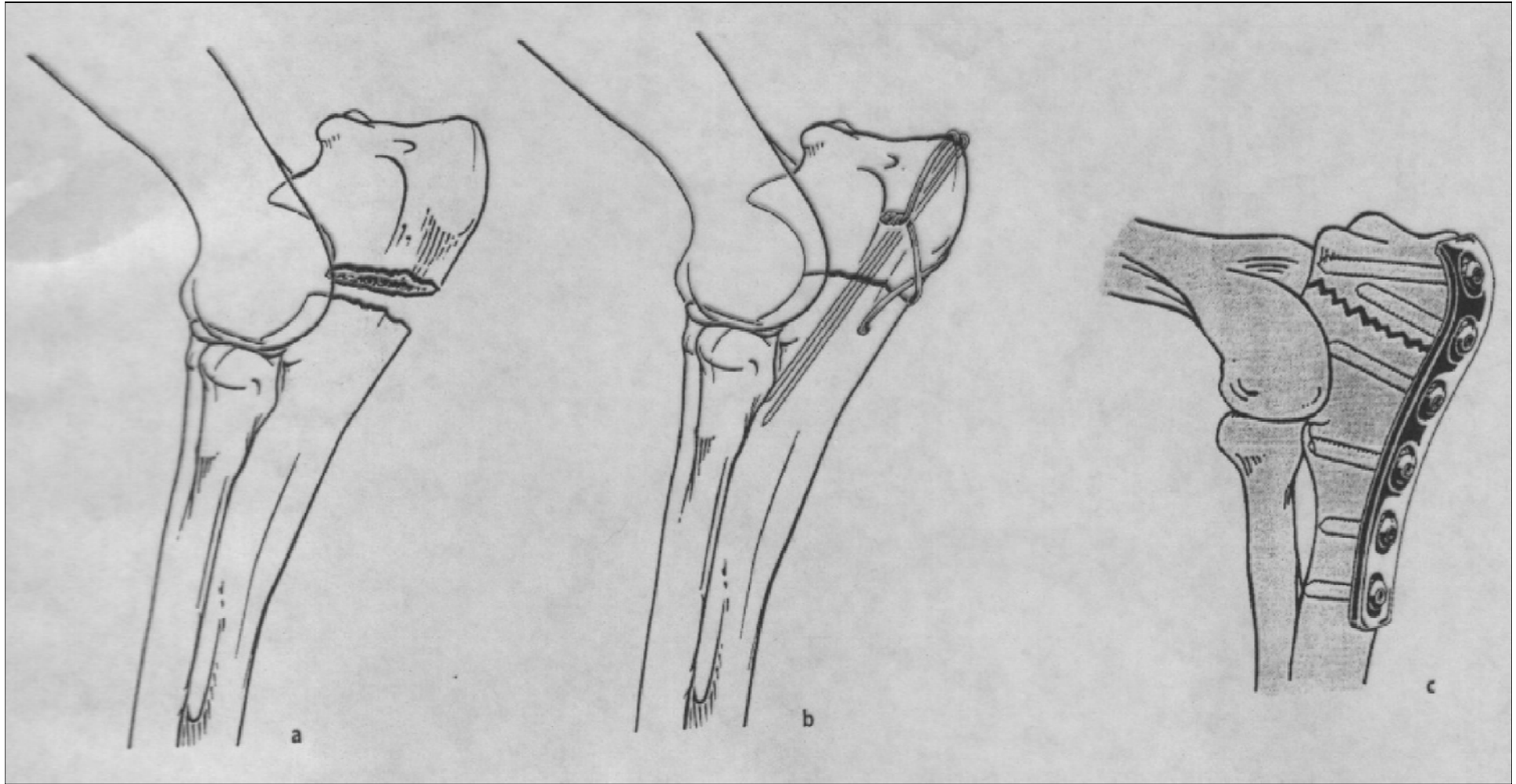
Προσπέλαση εξωτερικής περιφερικής διάφυσης



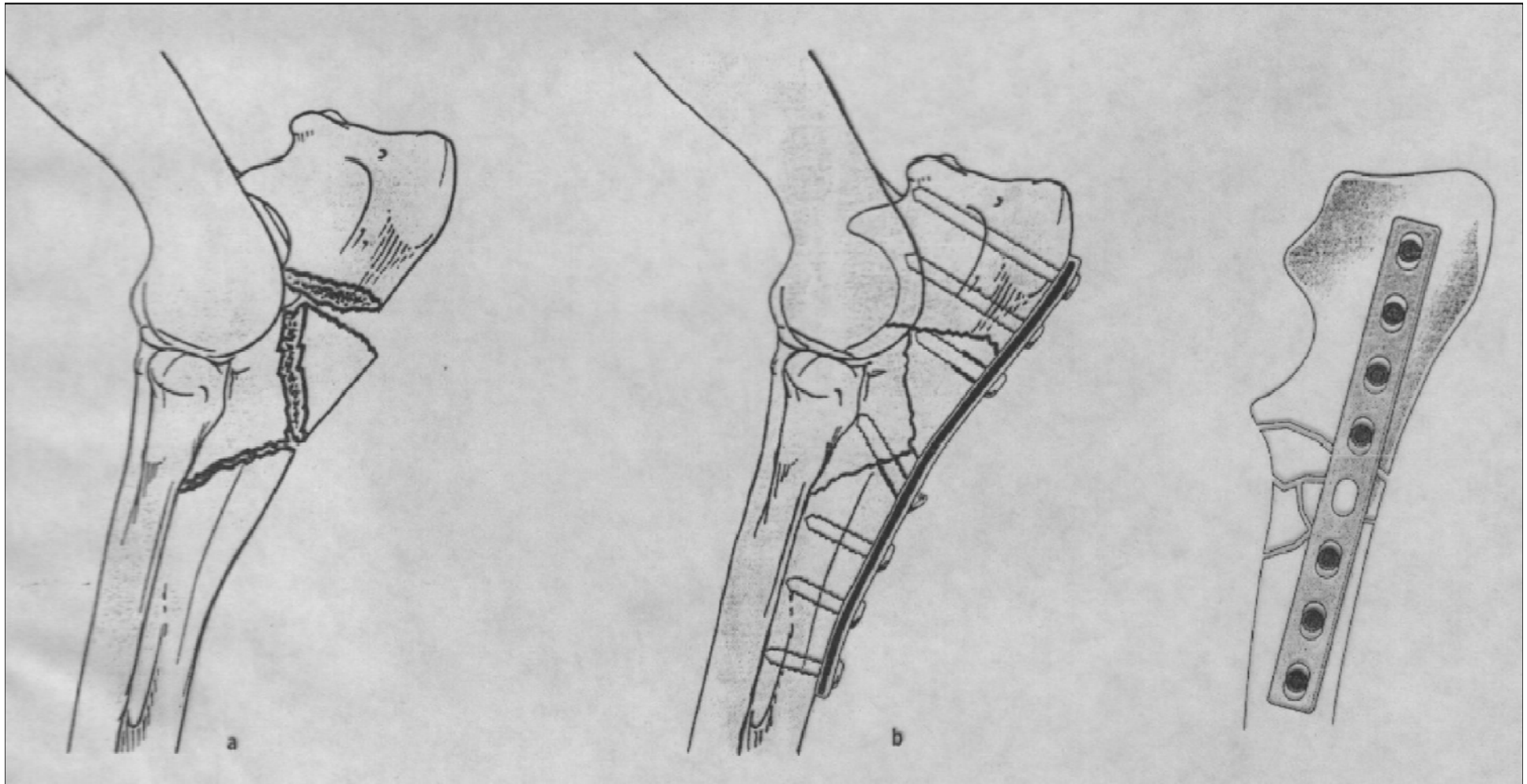
Προσπέλαση εσωτερικής περιφερικής διάφυσης



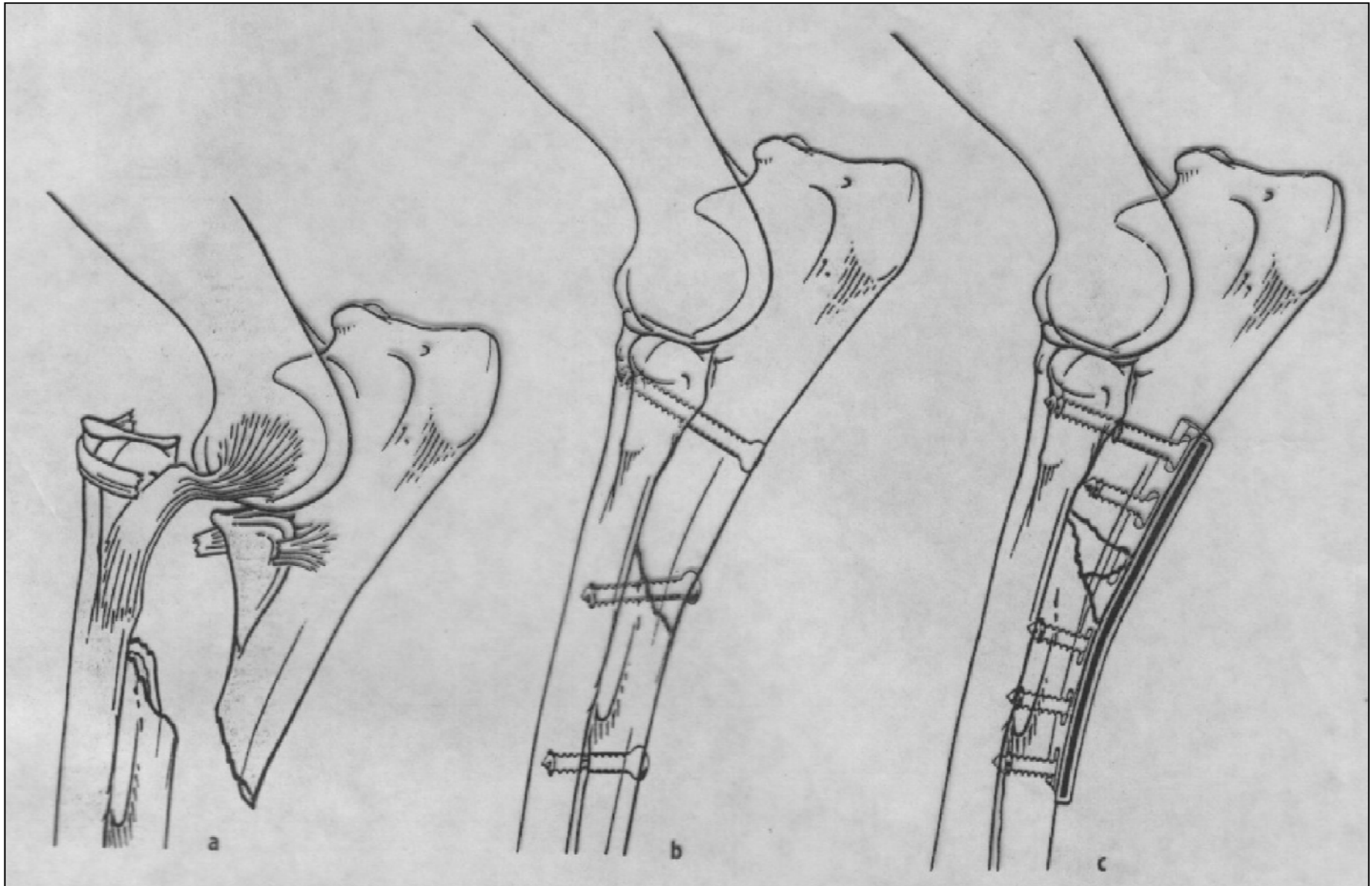
Ωλένη - Ωλέκραιο



Διάφυση

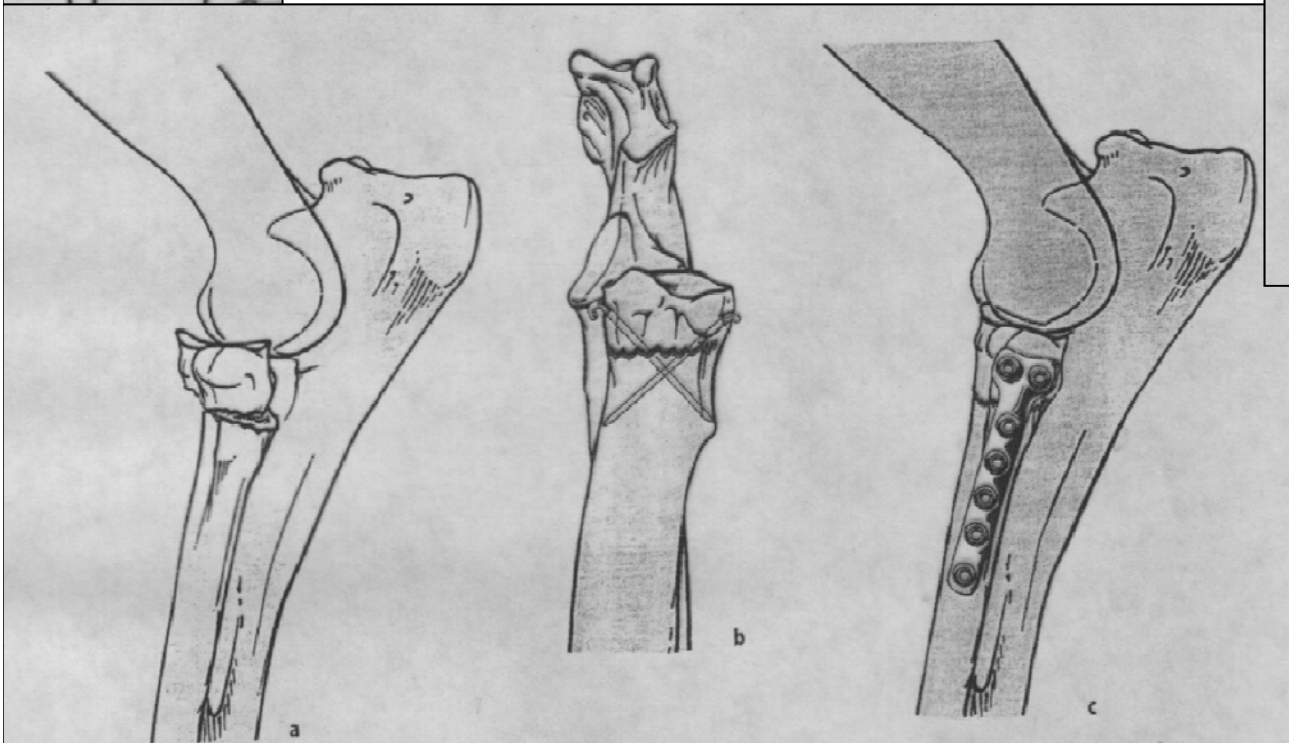
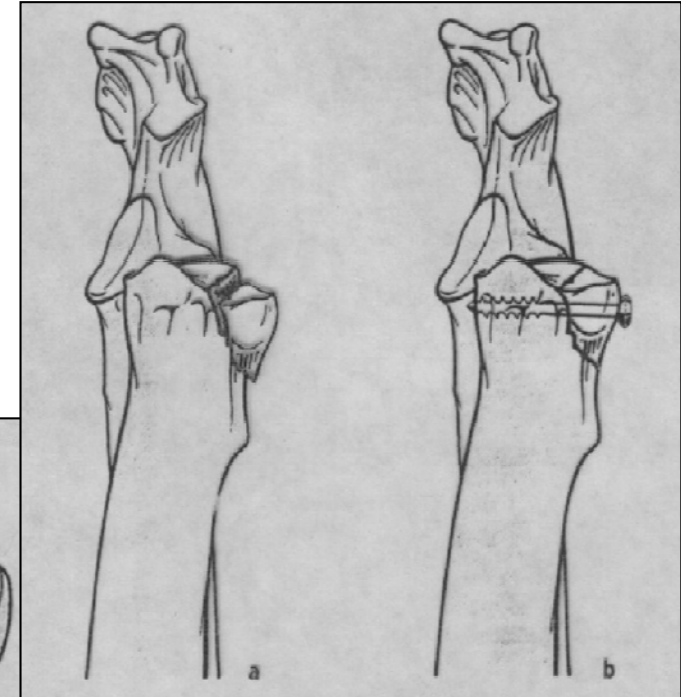
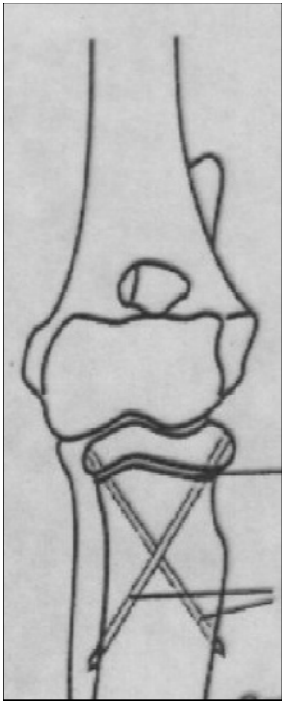


Κάταγμα Monteggia

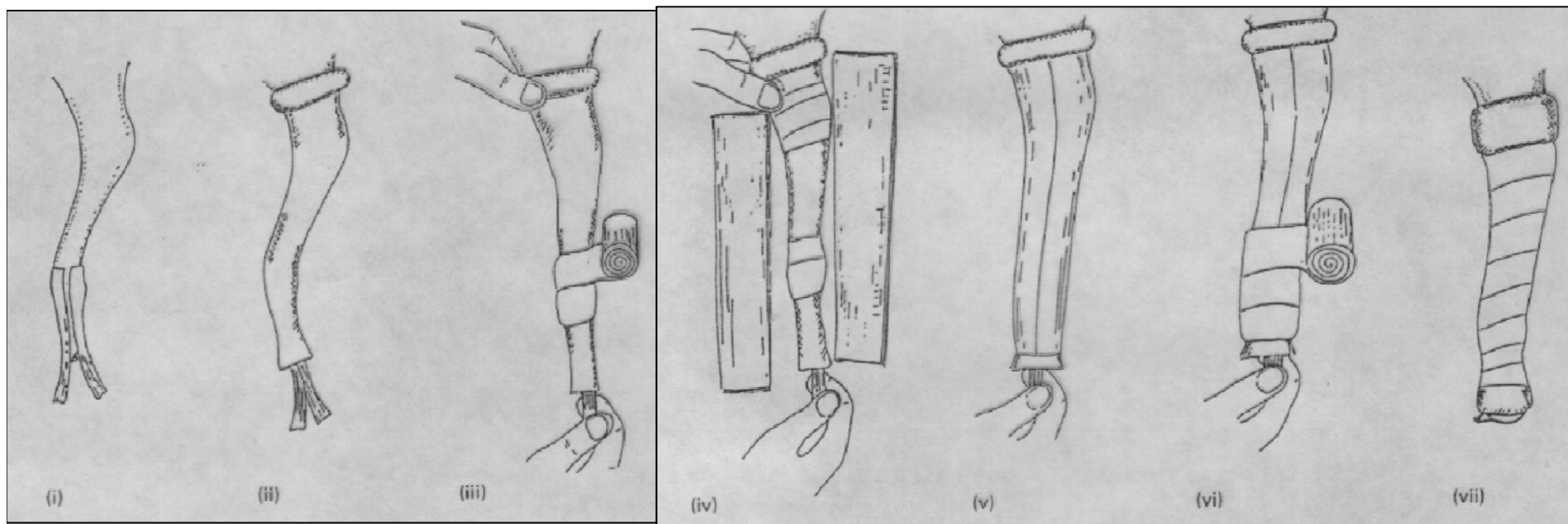


Κερκίδα

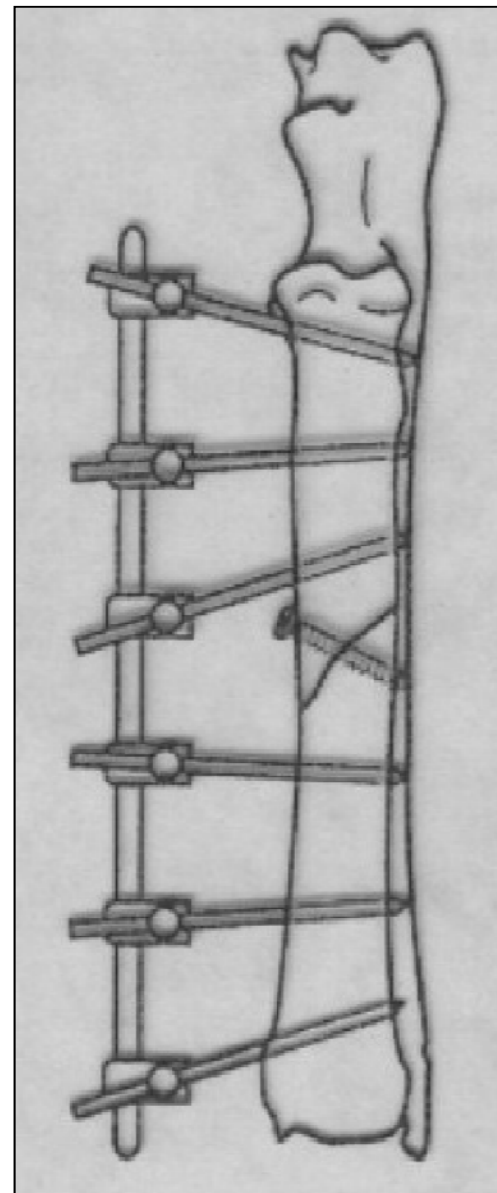
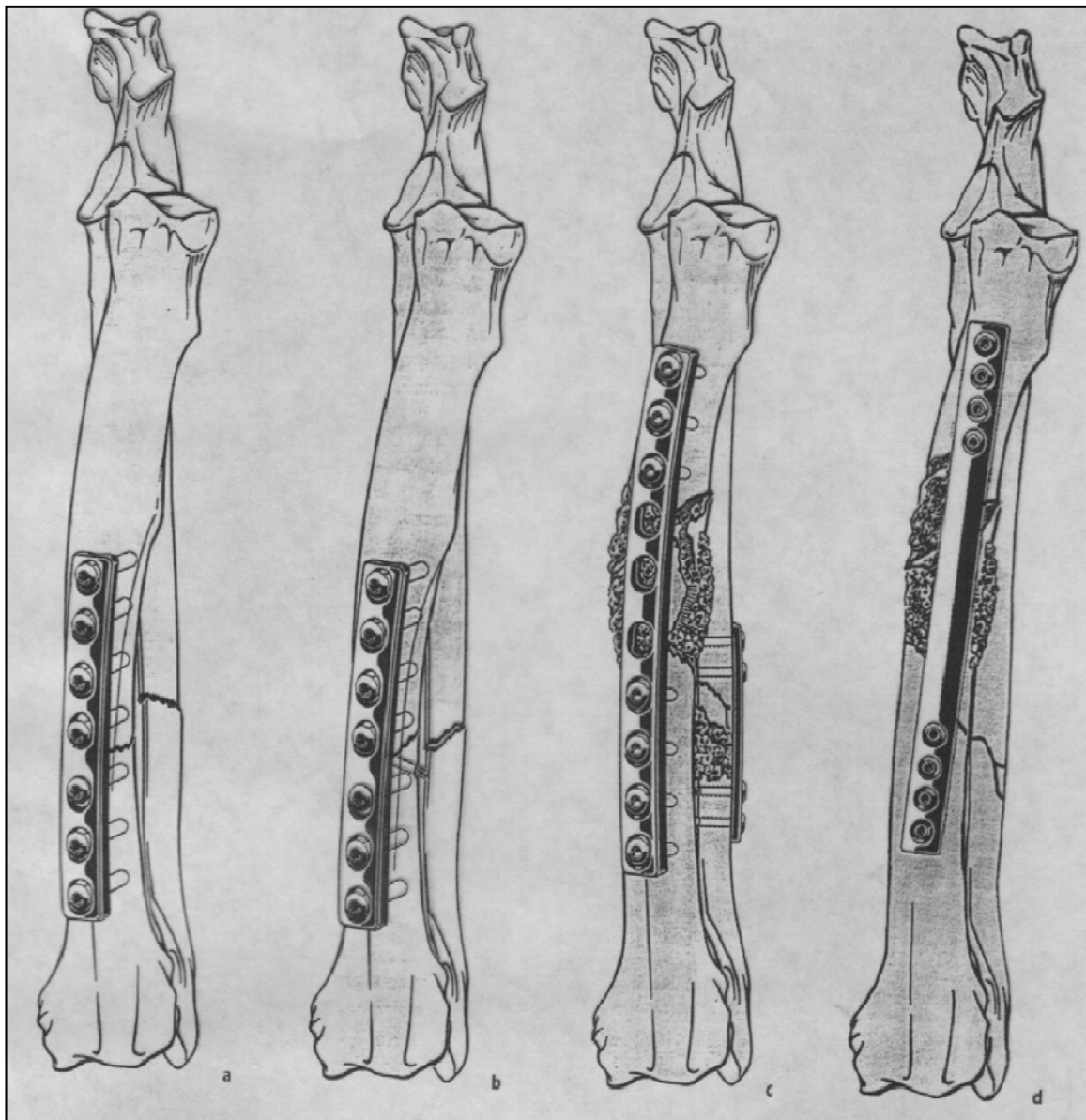
Κεντρική επίφυση - μετάφυση



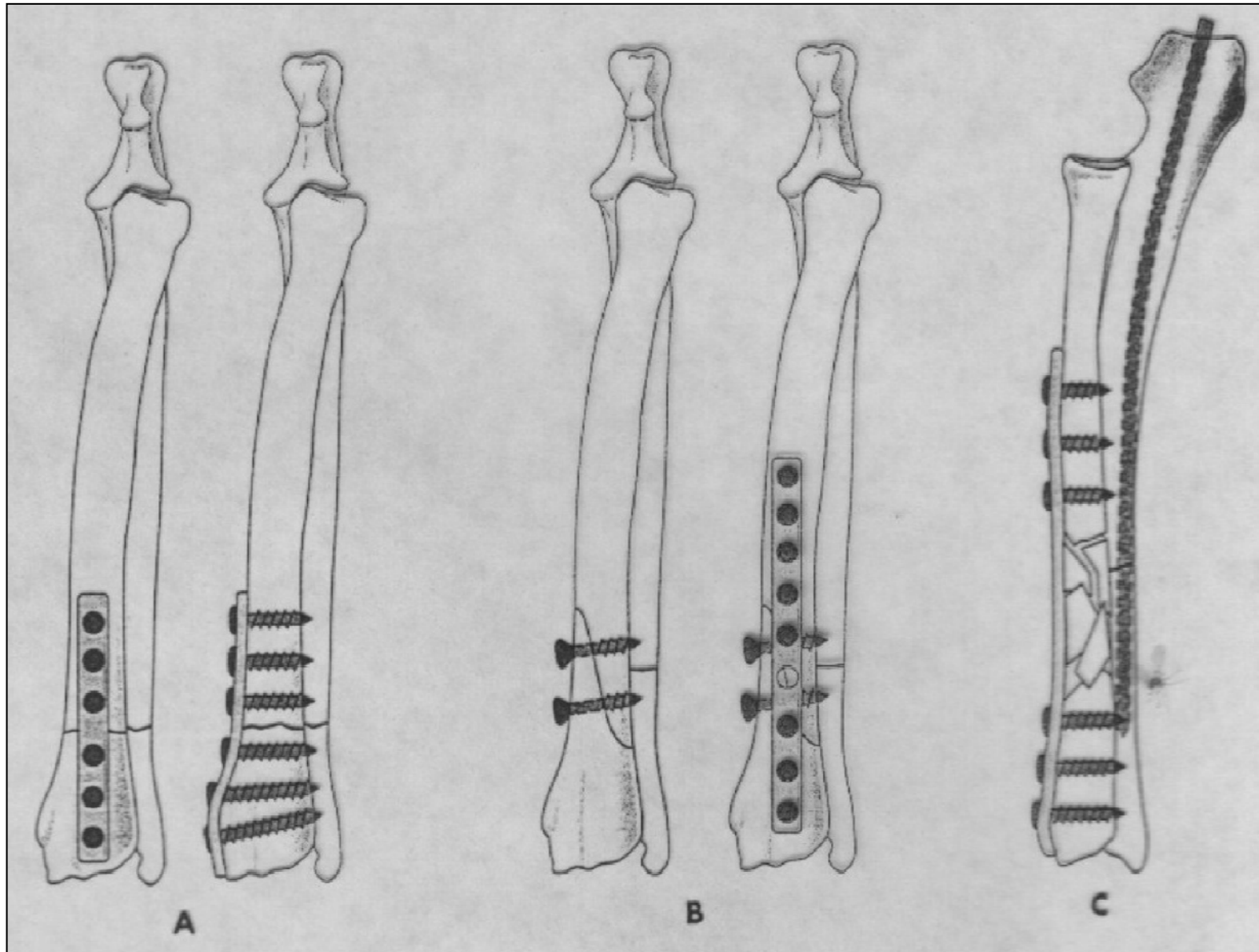
Διάφυση



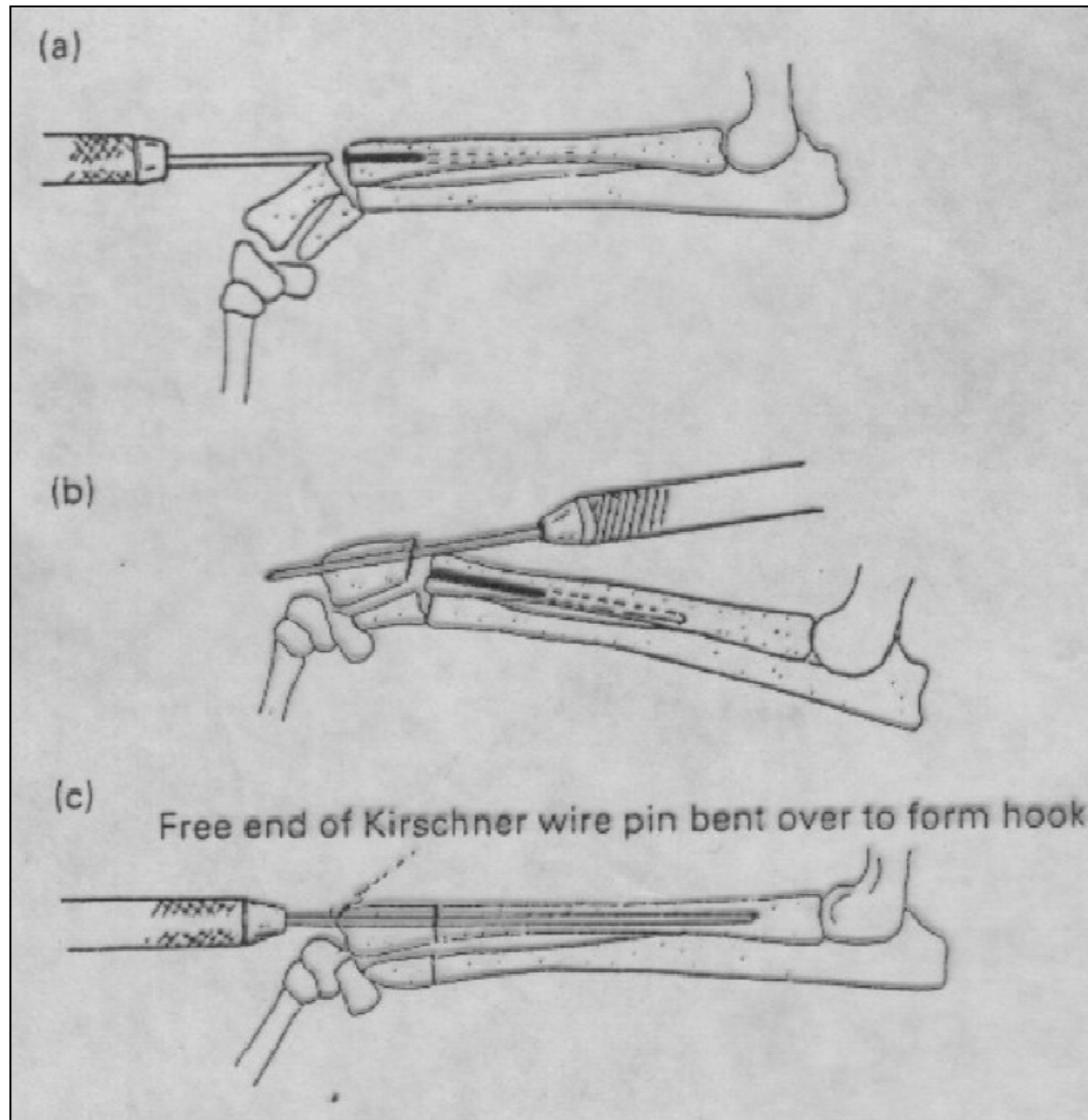
Διάφυση



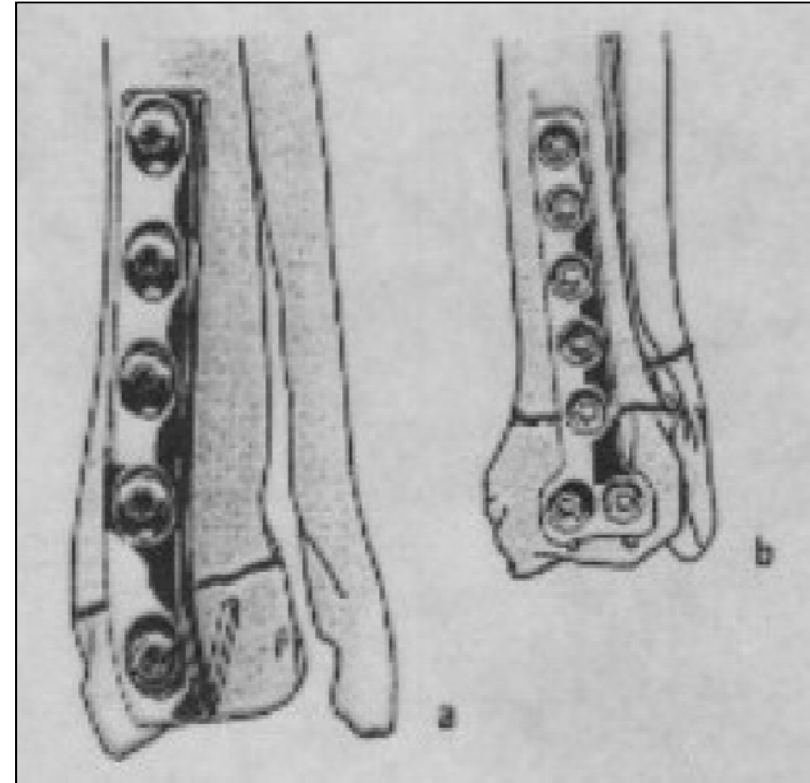
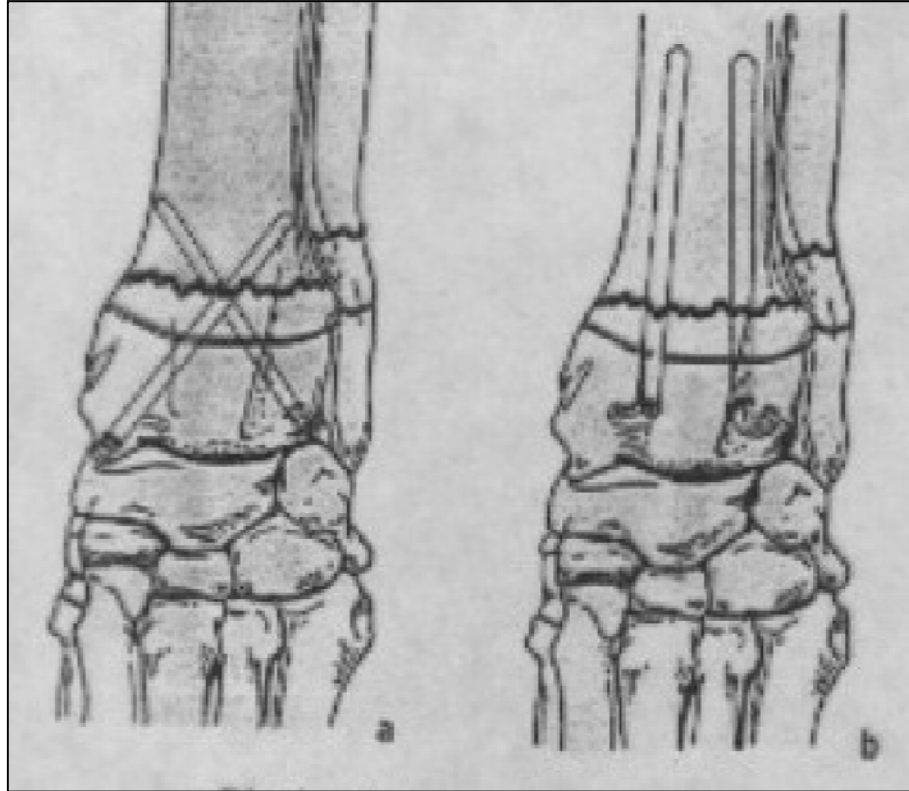
Περιφερική διάφυση



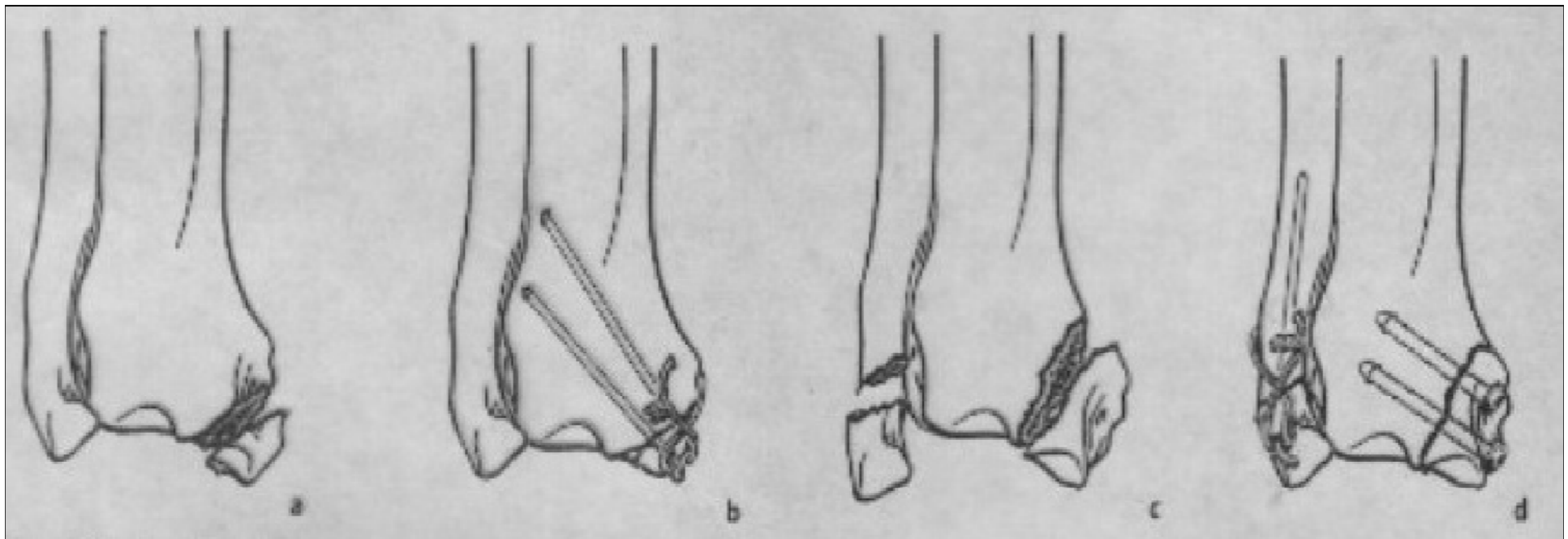
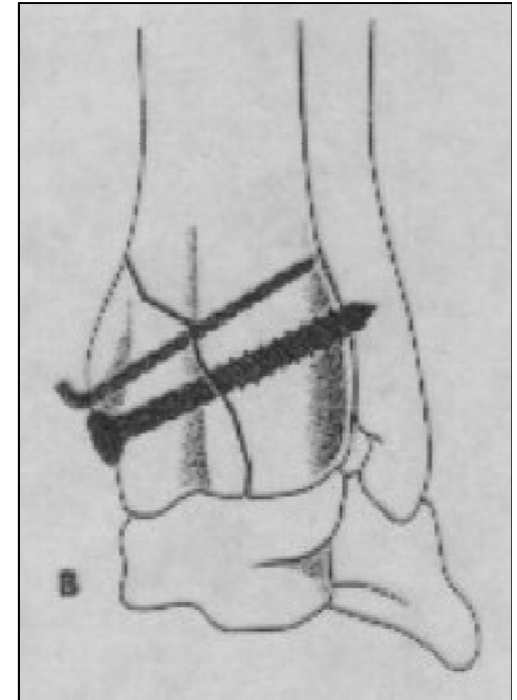
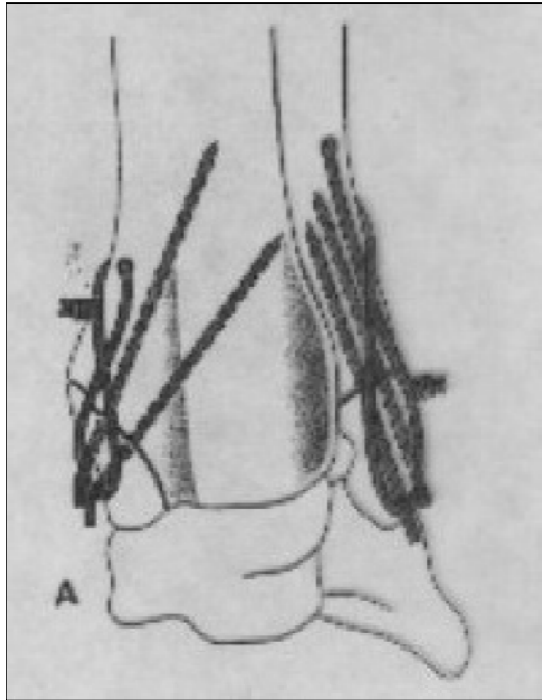
Περιφερική διάφυση



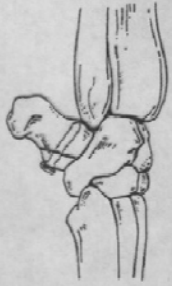Περιφερική μετάφυση



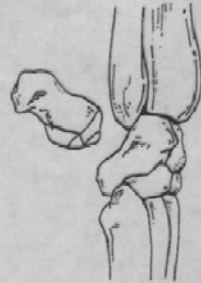Στυλοειδείς αποφύσεις



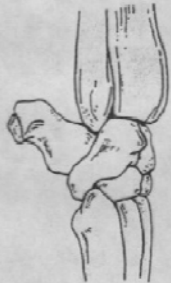
Καρπός - Πισοειδές οστό



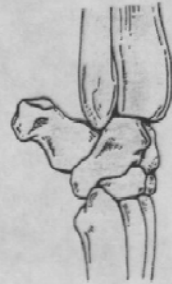Type 1A fracture of the accessory carpal bone. An intra-articular avulsion fracture of the origin of the accessero-ulnar ligament



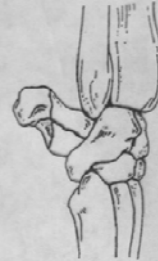Type 1B fracture of the accessory carpal bone has a medial intra-articular component



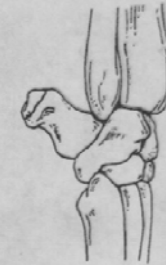Type III fracture of the accessory carpal bone. An avulsion fracture of the origin of the accessory carpal-metacarpal ligament



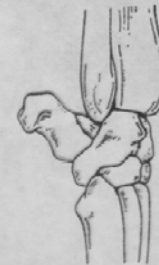Type IV fracture of the accessory carpal bone. Avulsion of insertion of flexor carpi ulnaris tendon



Type V fracture of the accessory carpal bone. A comminuted fracture

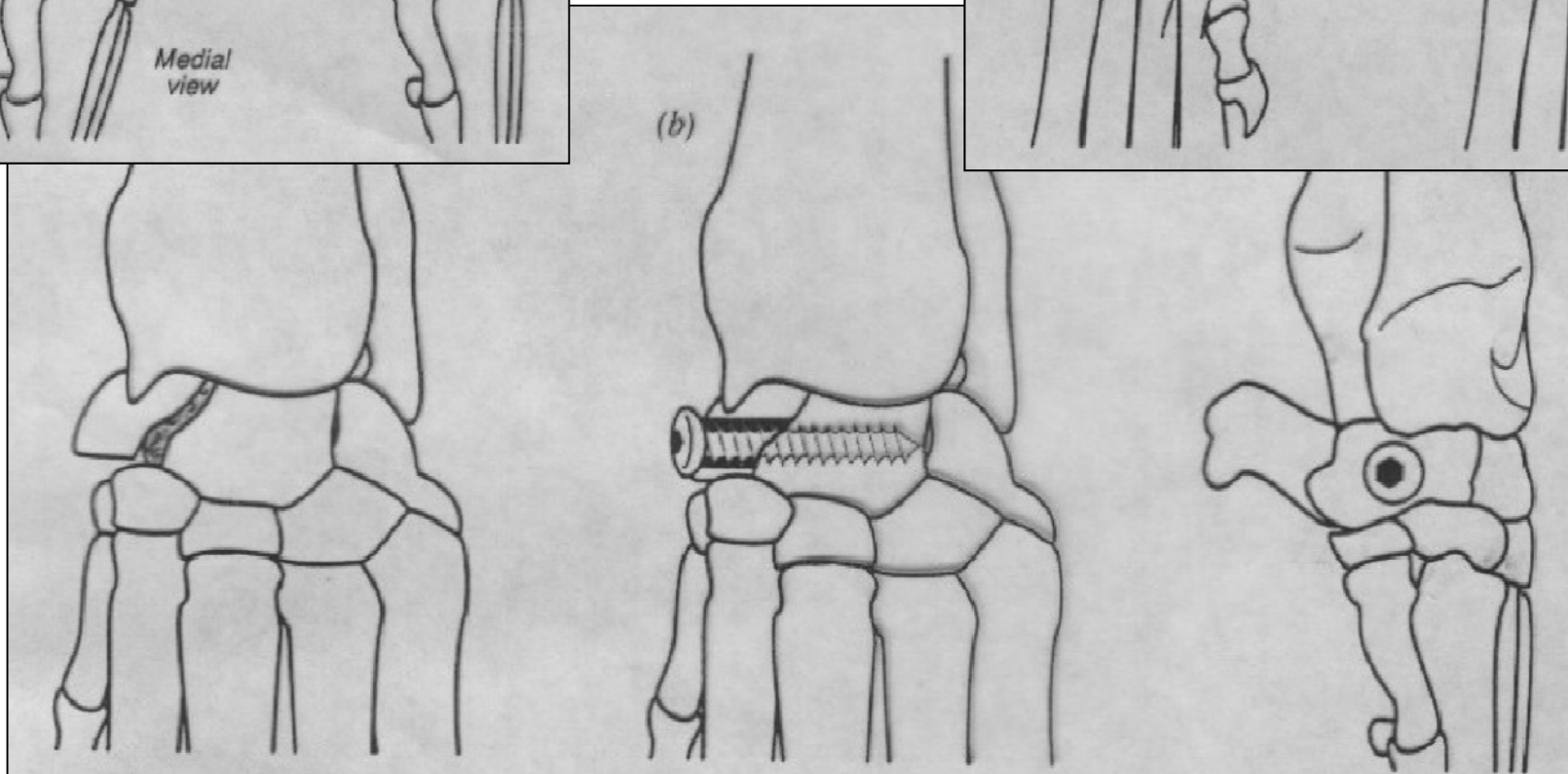
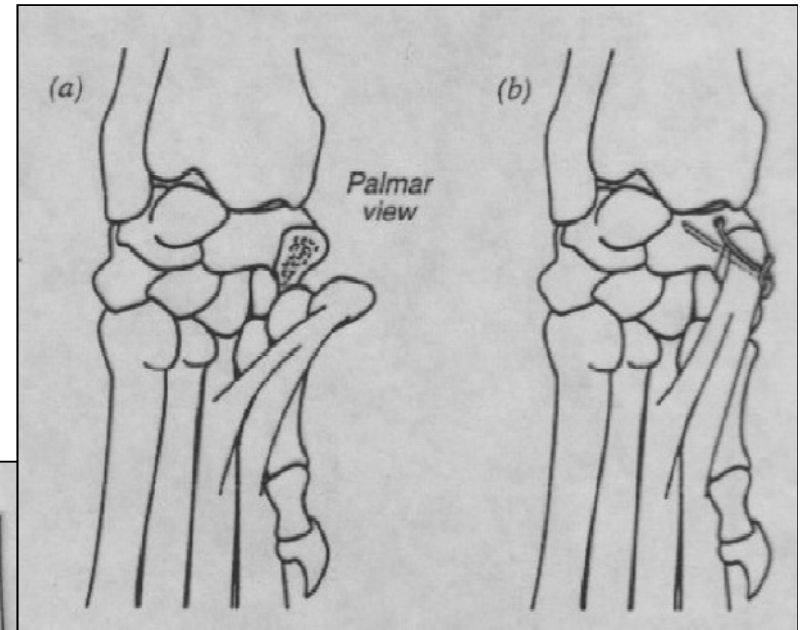
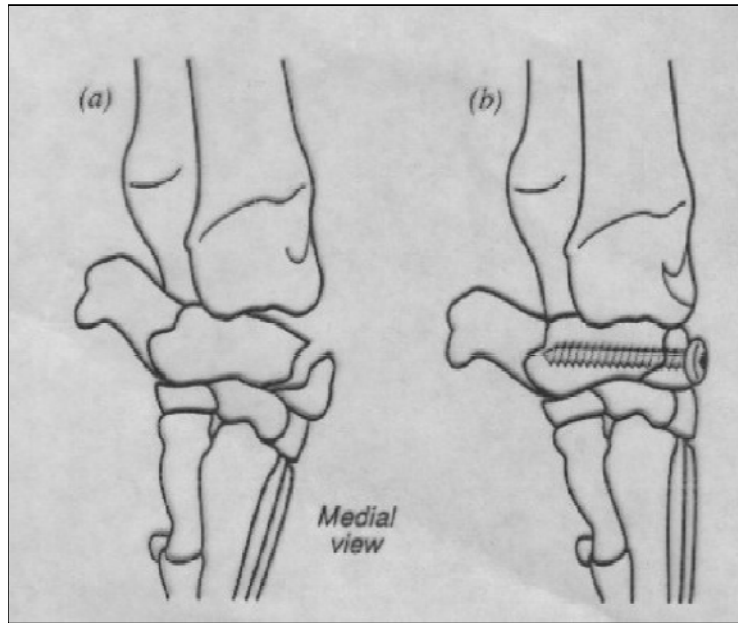


Type VI fracture of the accessory carpal bone. Avulsion of growth plate of the accessory carpal bone

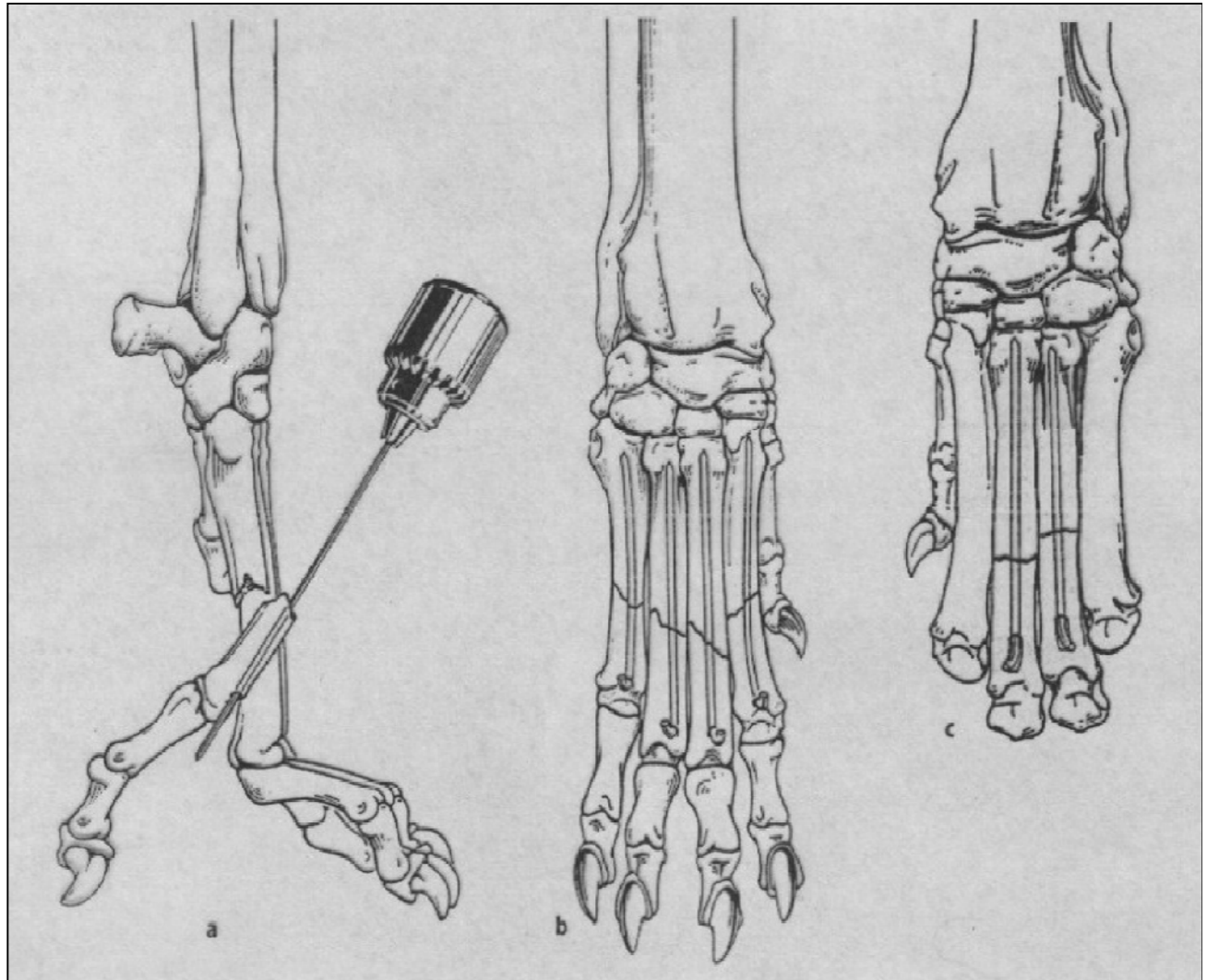
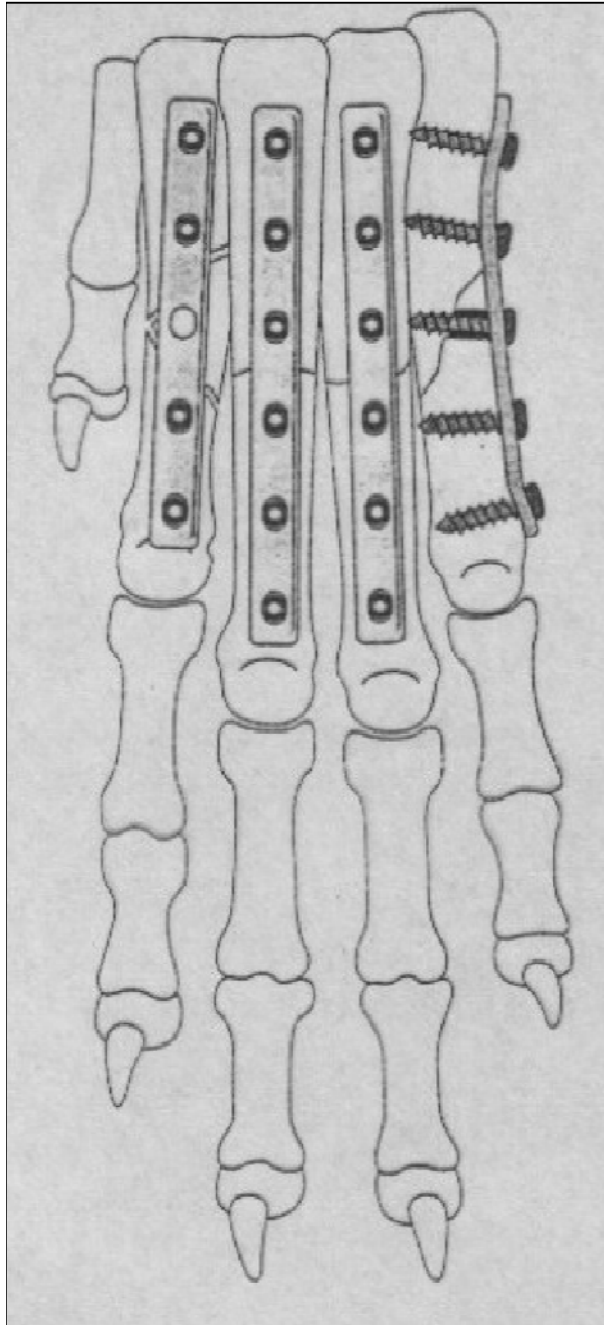


Type II fracture of the accessory carpal bone. An intra-articular fracture of the accessory carpal bone that involves the proximal portion of the base

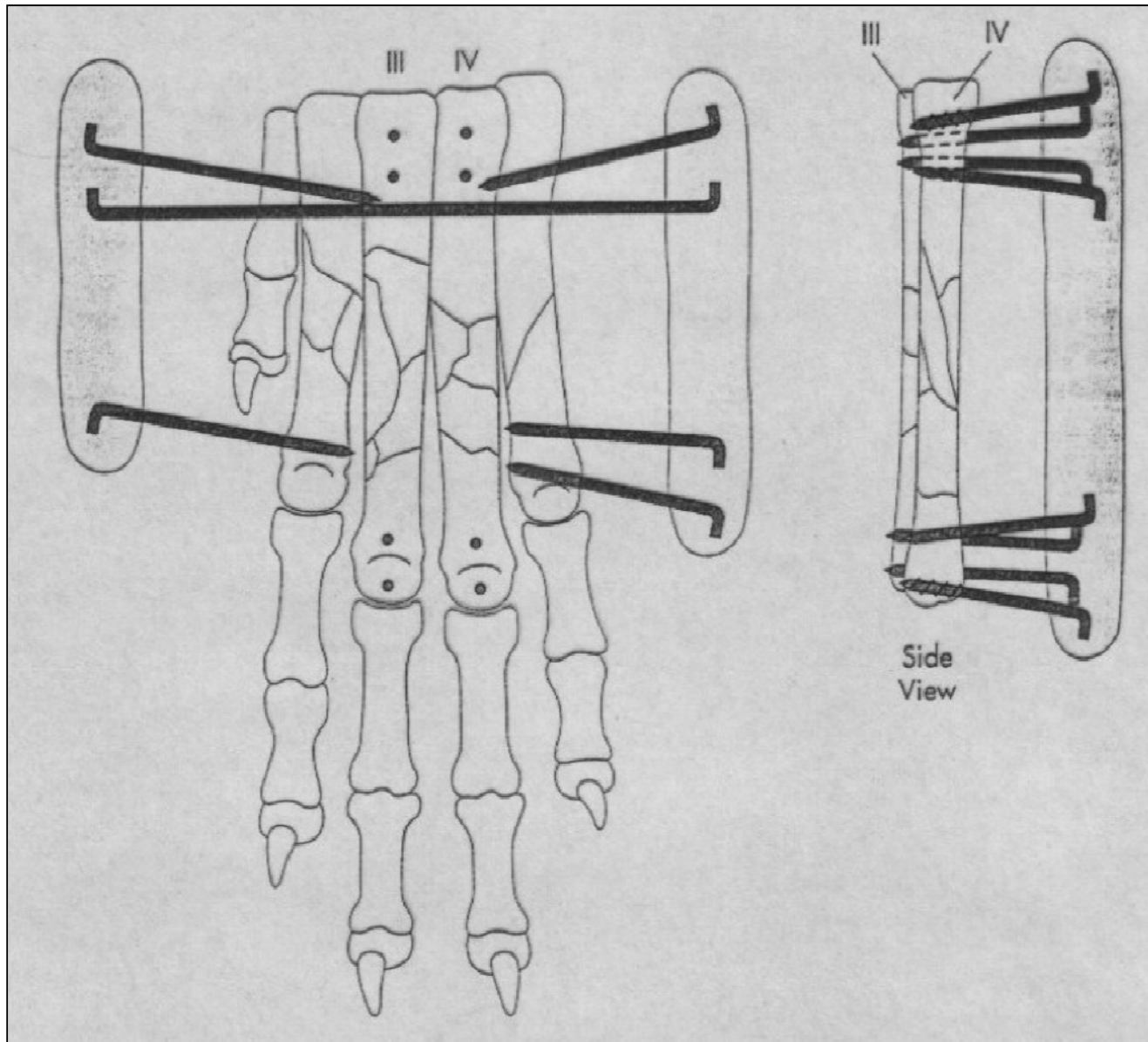
Σκαφομηνοειδές οστό



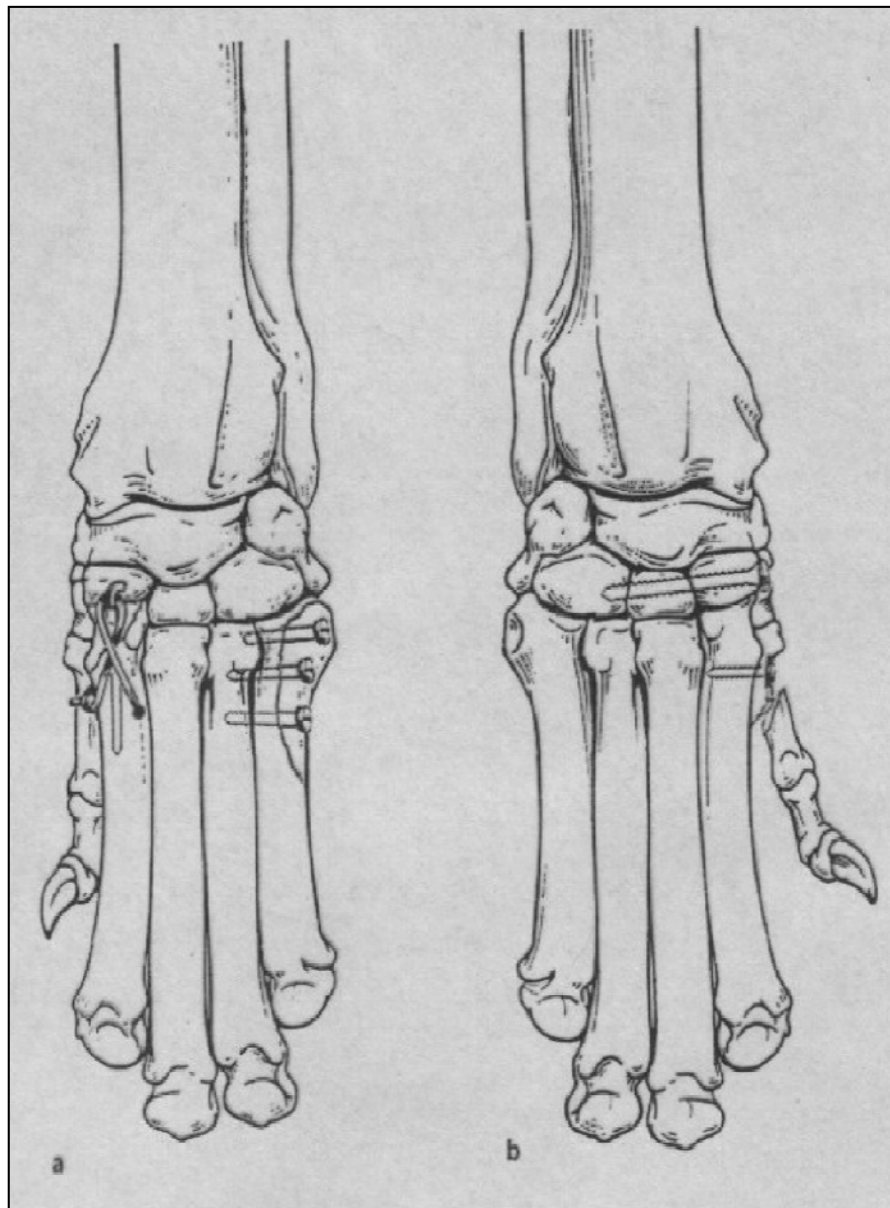
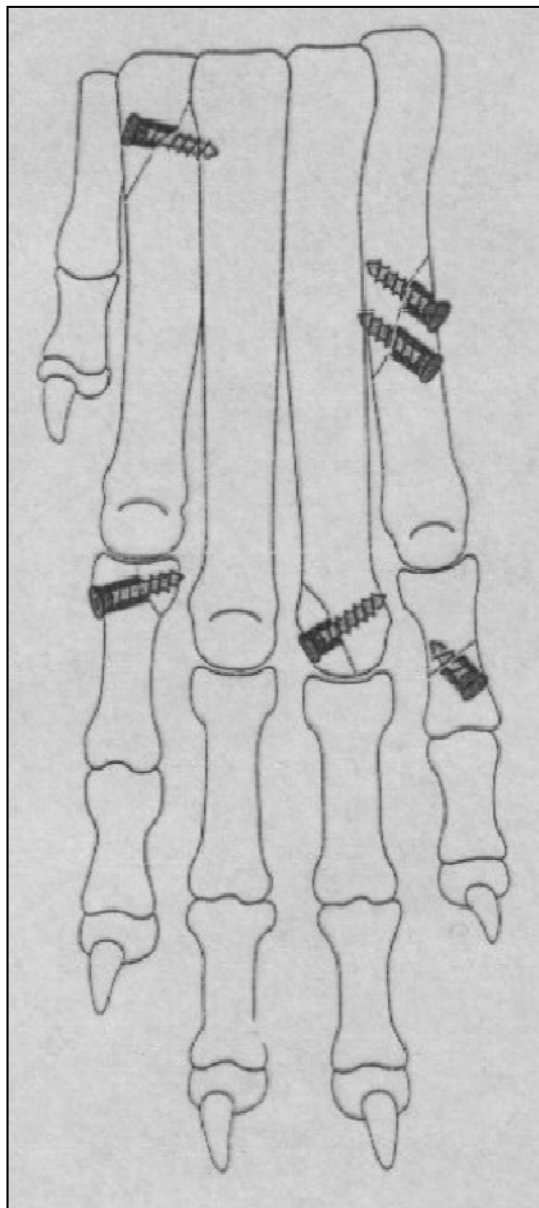
Μετακάρπια



Μετακάρπια



Μετακάρπια



Φαλάγγες

