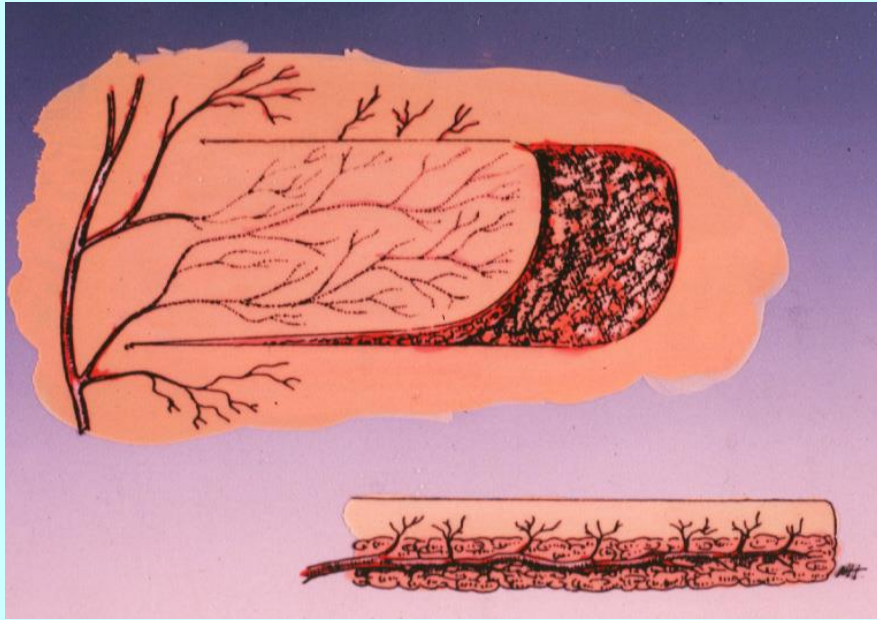


Κρημνοί υποχοριοειδούς πλέγματος

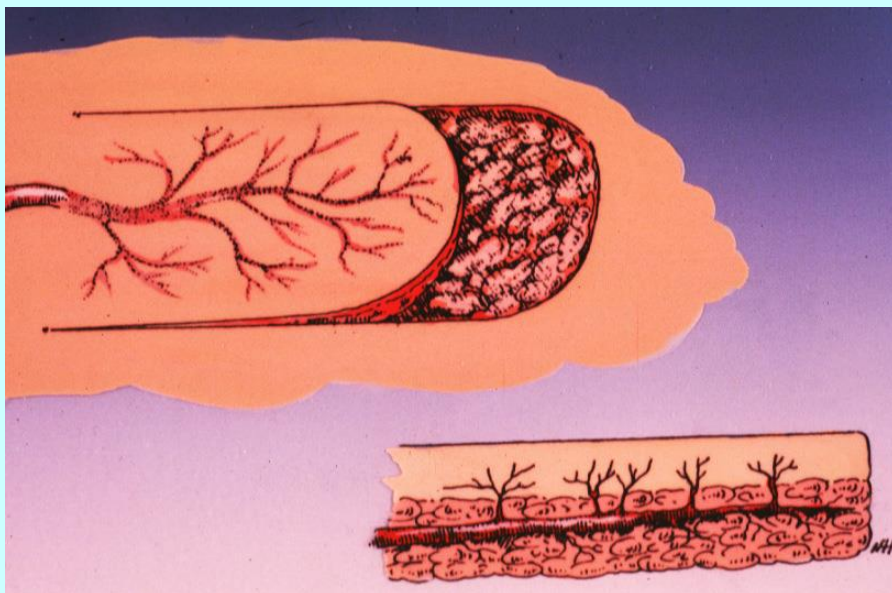
*Λυσίμαχος Παπάζογλου
Τμήμα Κτηνιατρικής ΑΠΘ*



Ouch! I think you'd better see a tailor...



Κρημνός
υποχωριοειδούς
πλέγματος



Αξονικός κρημνός

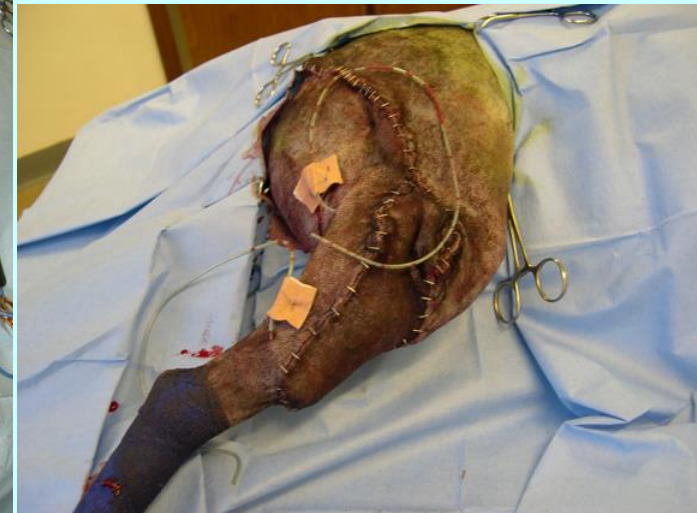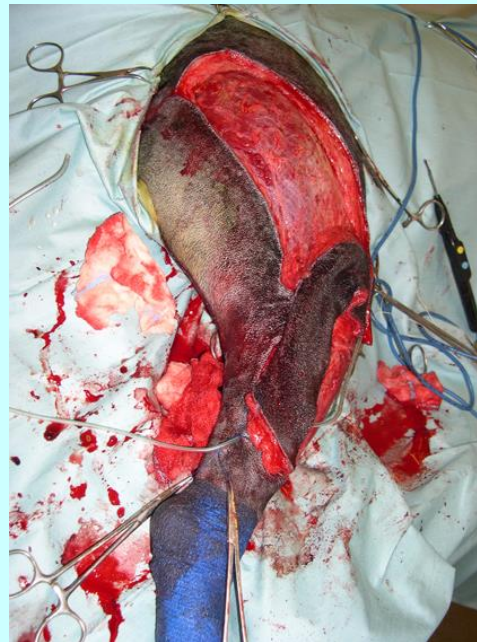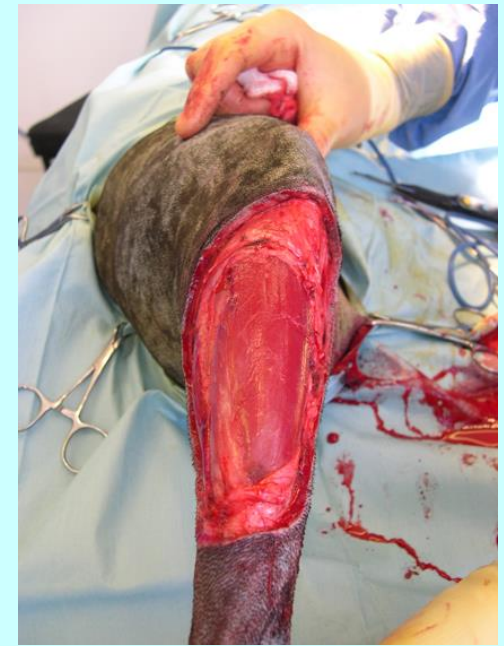Ταξινόμηση

- Μεταθετικός
- Περιστροφικός
- Προωθητικός

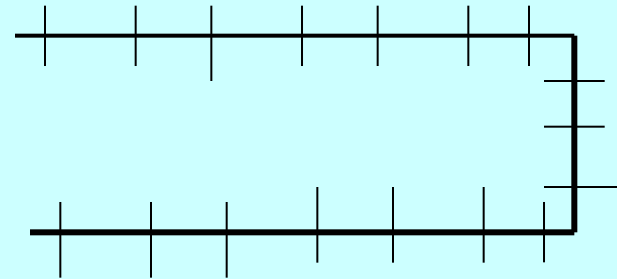
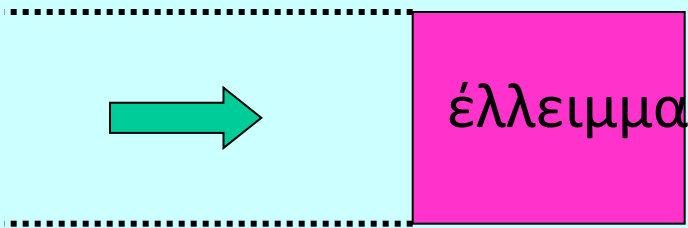
- Απομακρυσμένος κρημνός

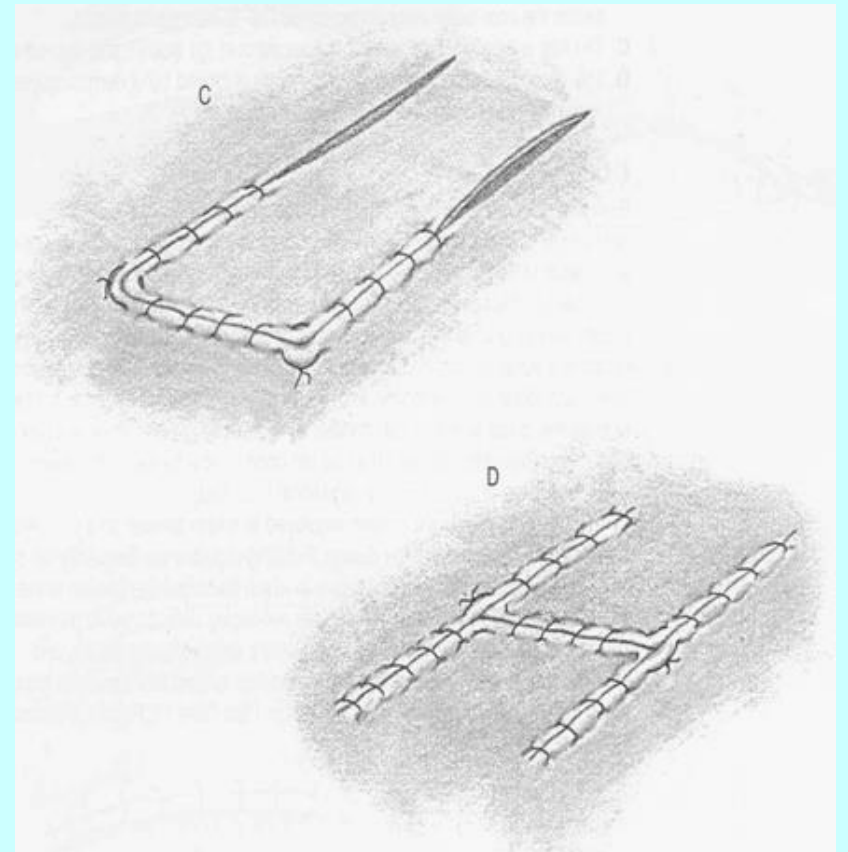
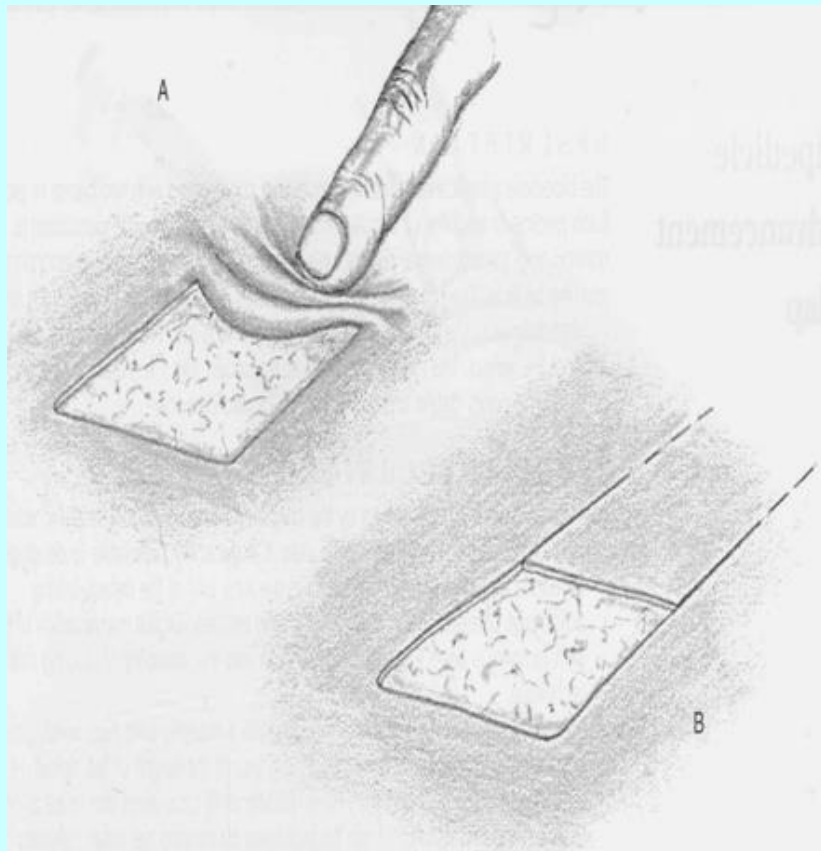
6 βήματα για την δημιουργία του κρημνού

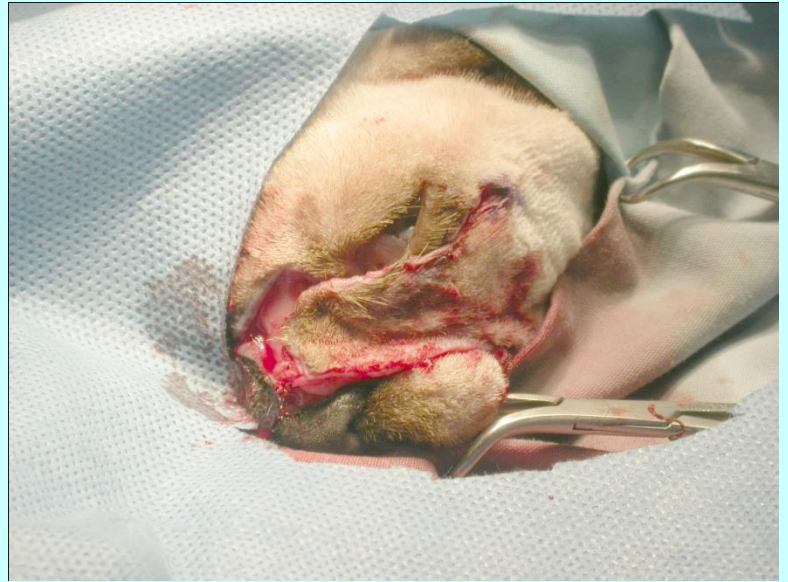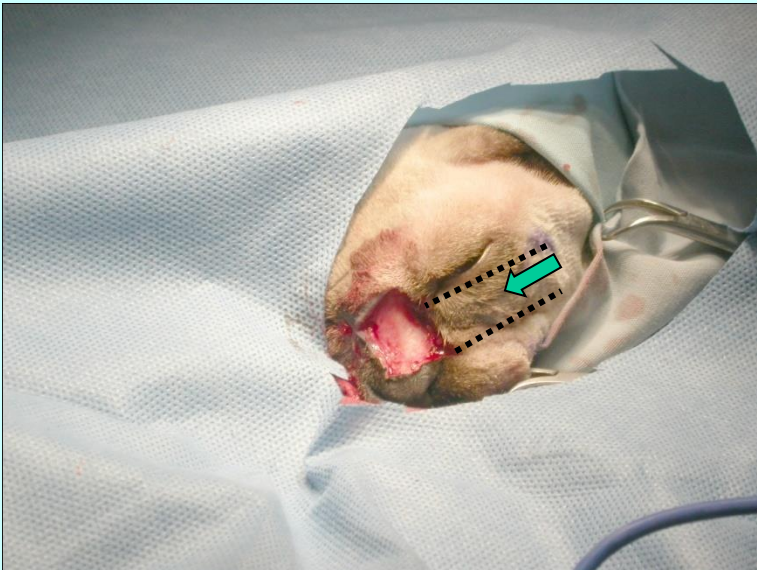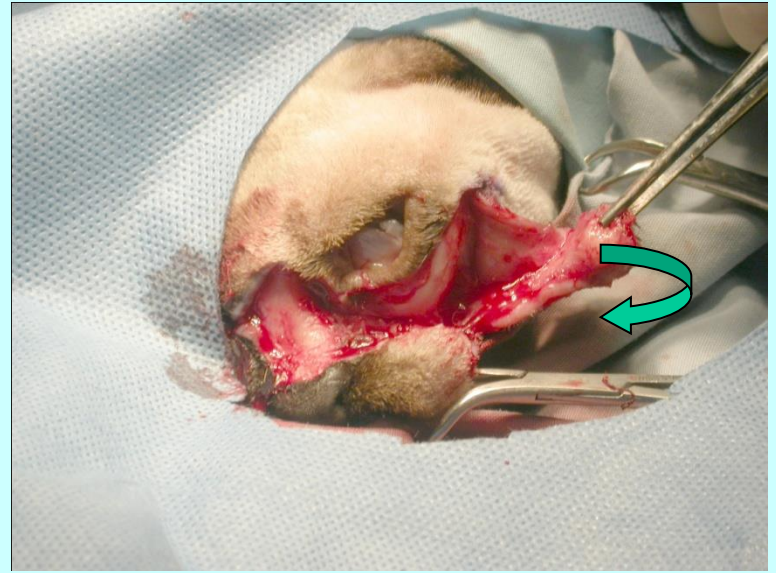
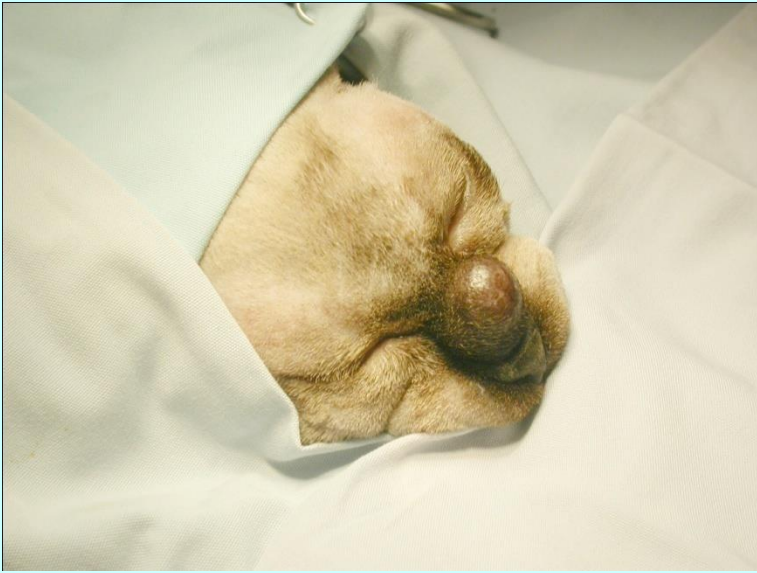- Σχεδιασμός
- Διατομή
- Ανάσπαση
- Μεταφορά
- Καθήλωση
- Παροχέτευση

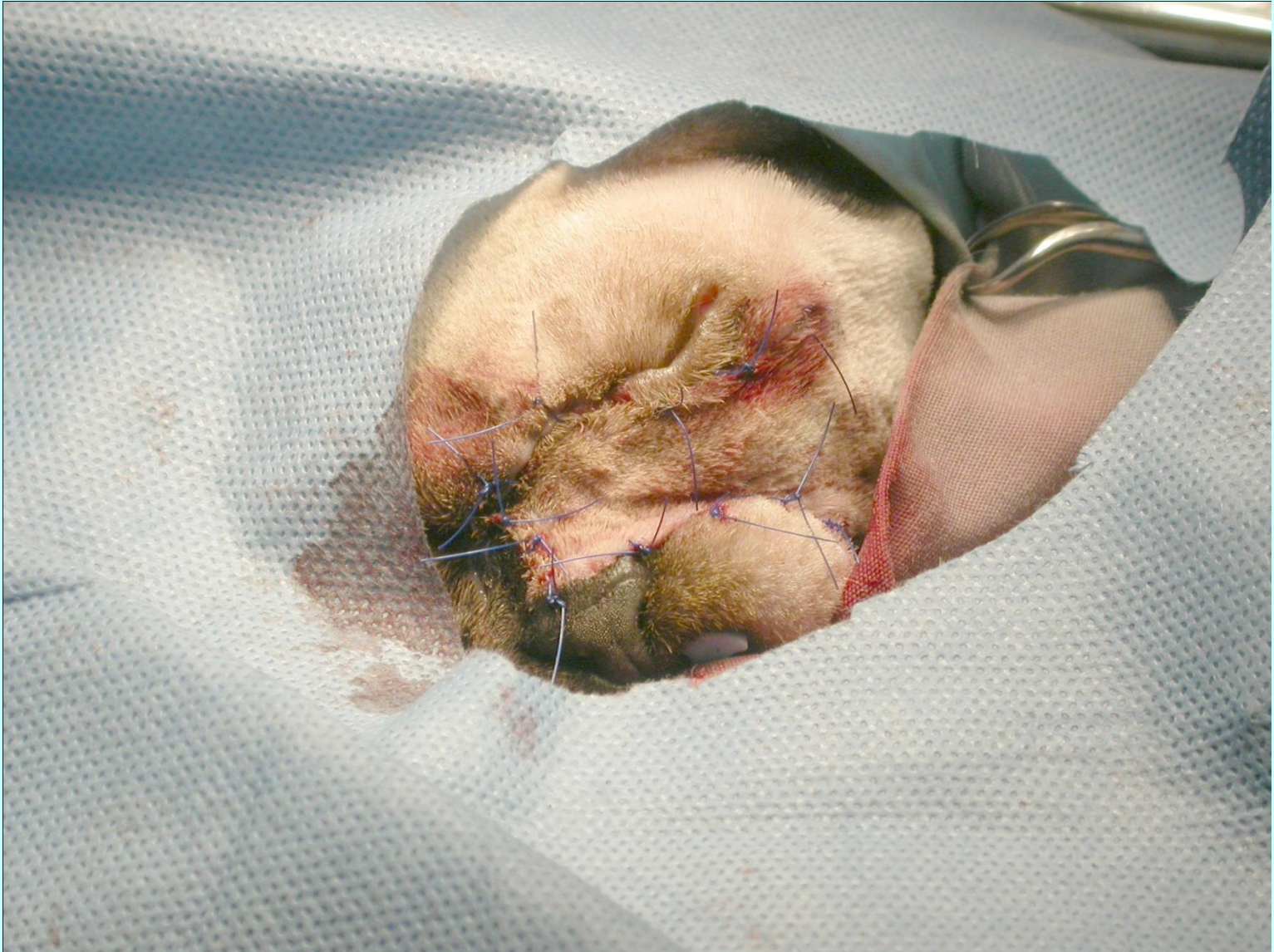


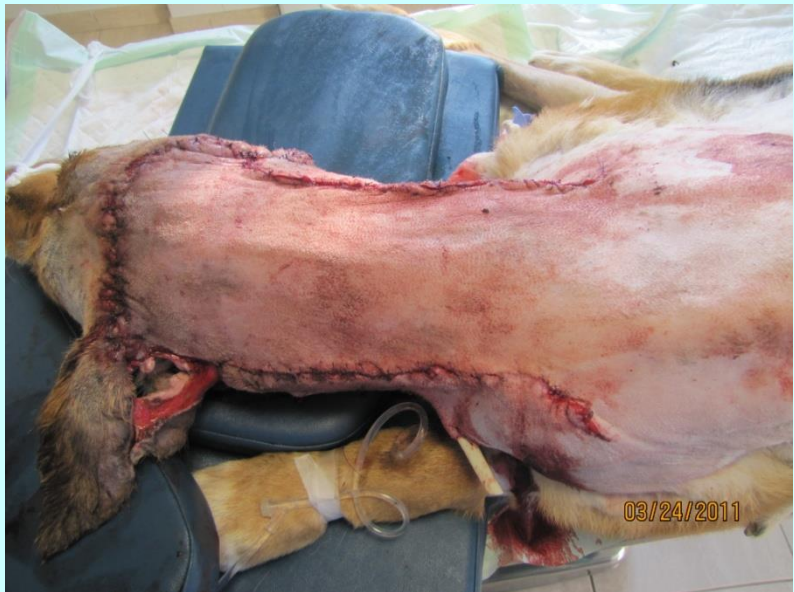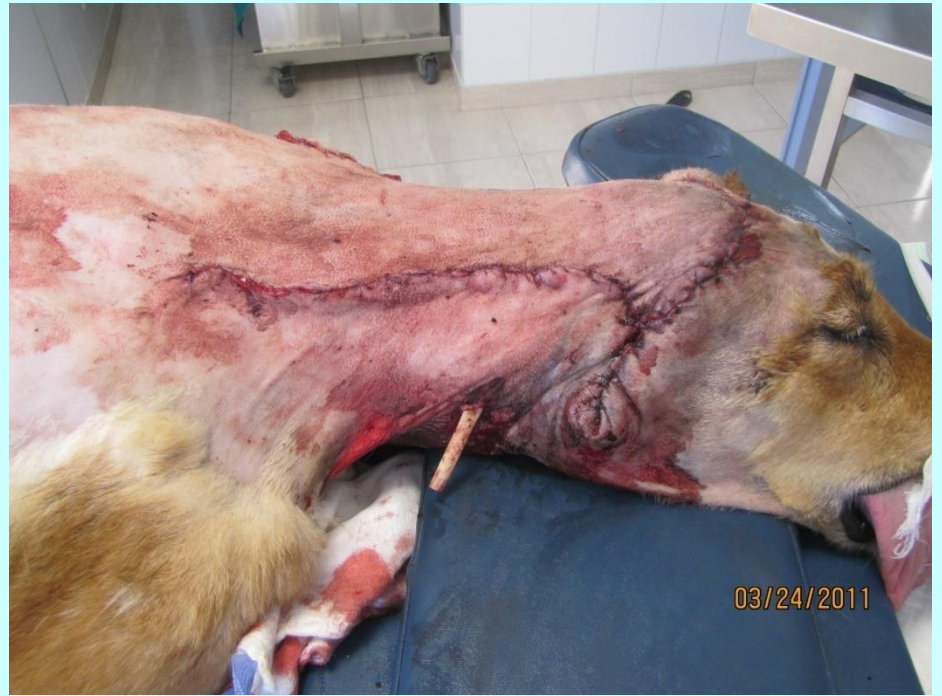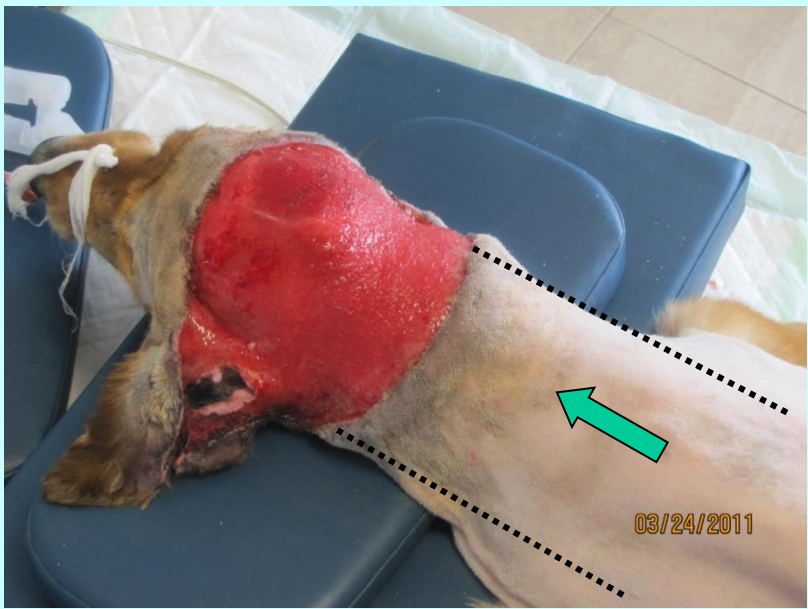
Πρωθητικός κρημνός με ένα μίσχο

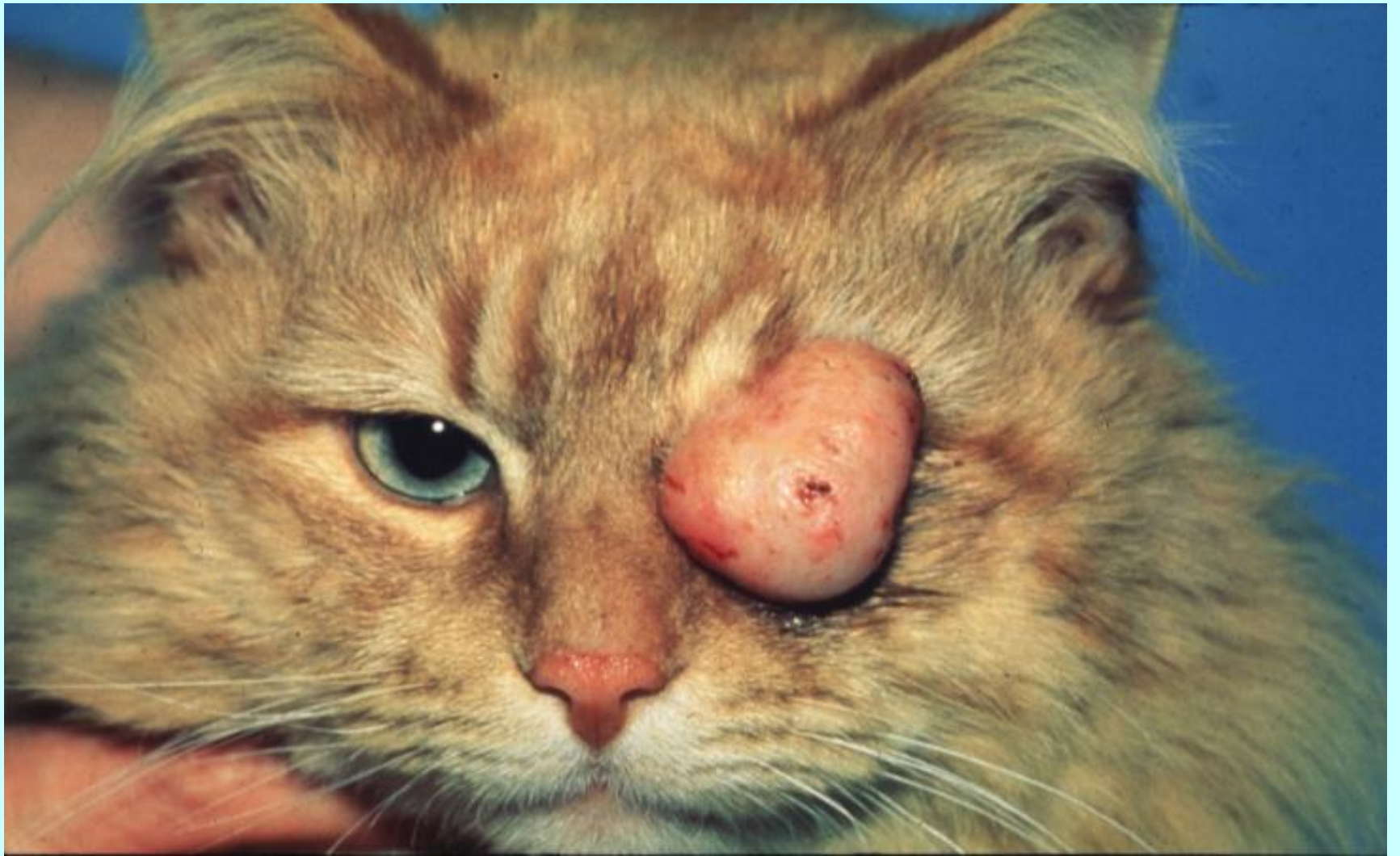

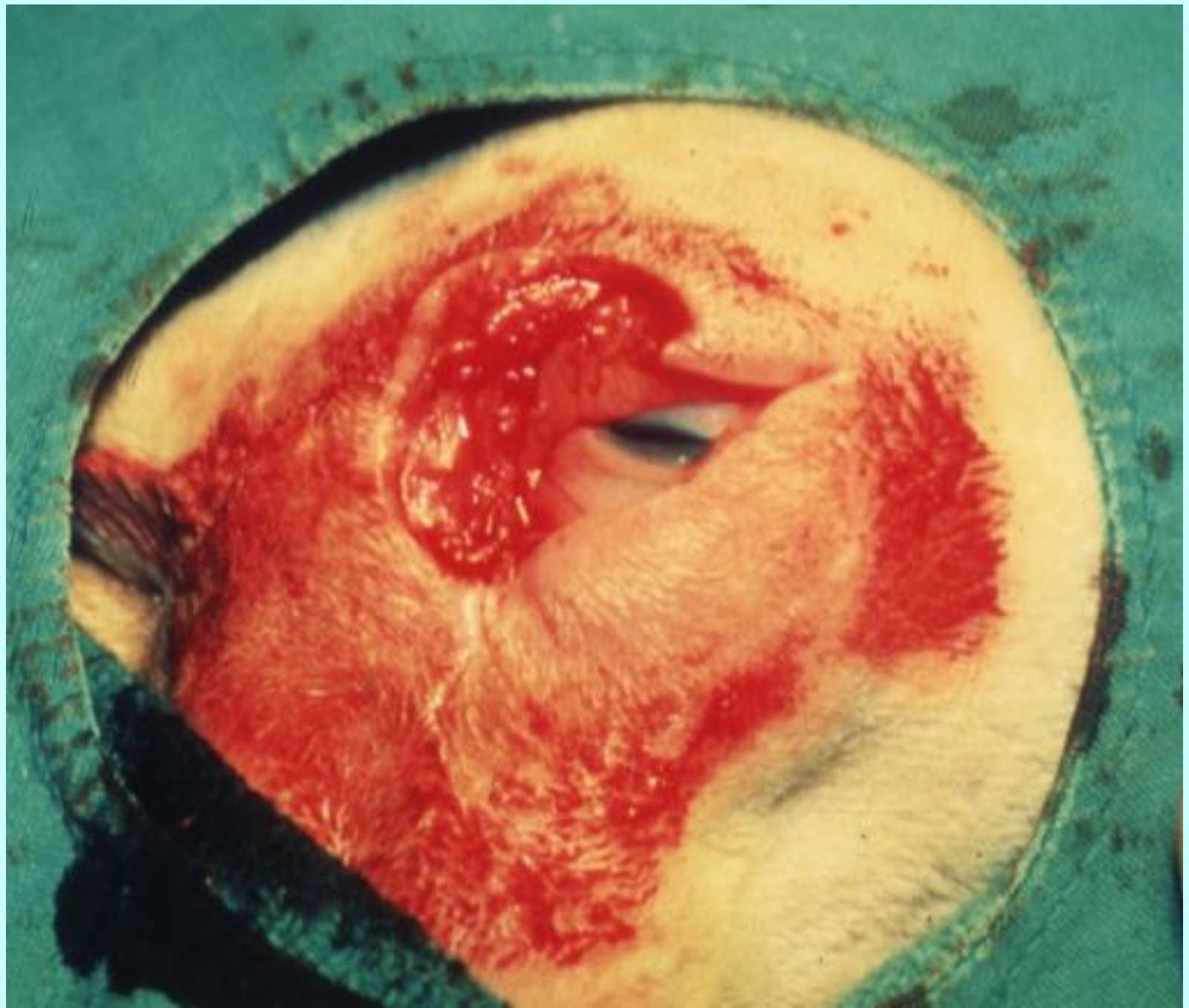


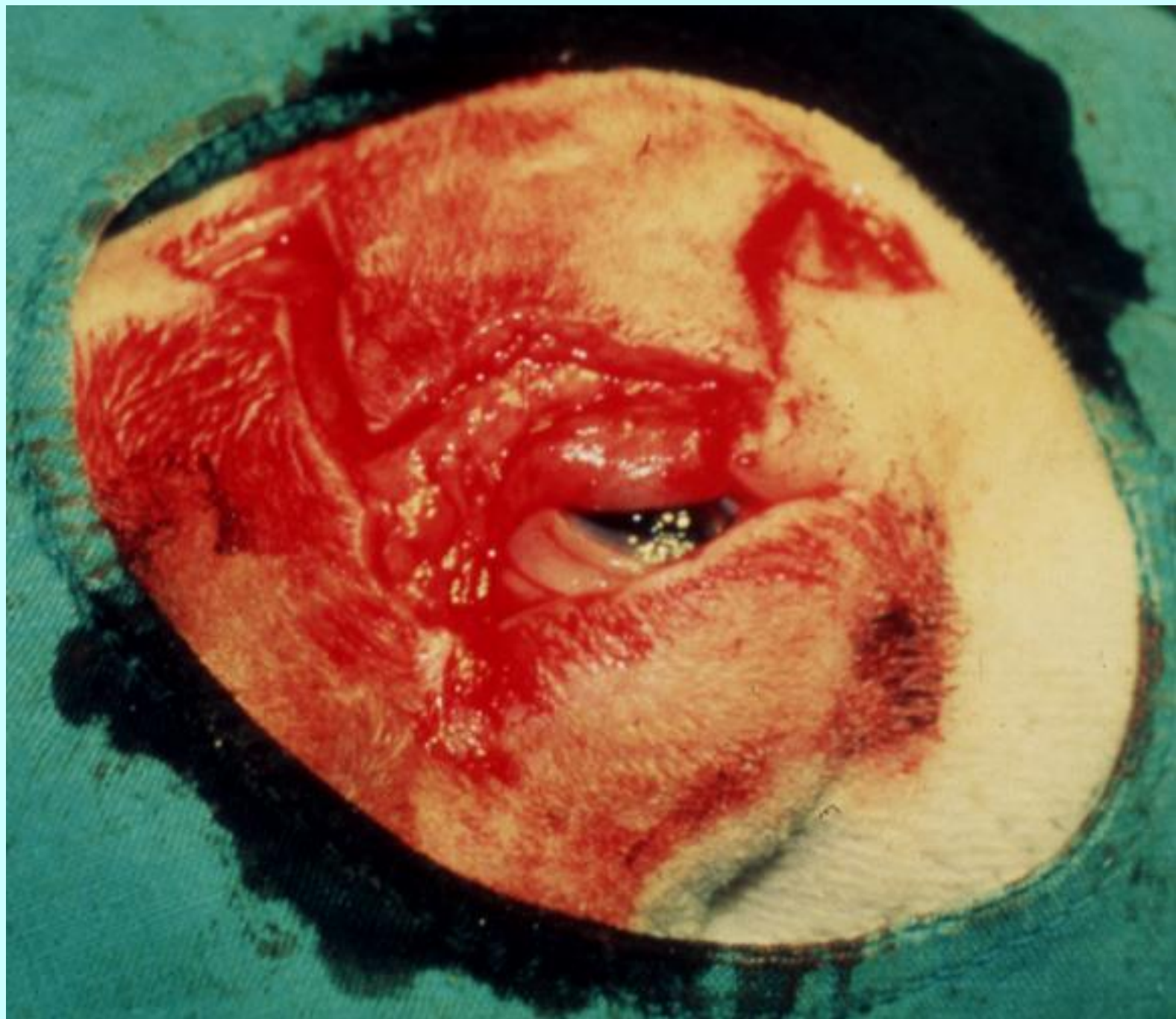


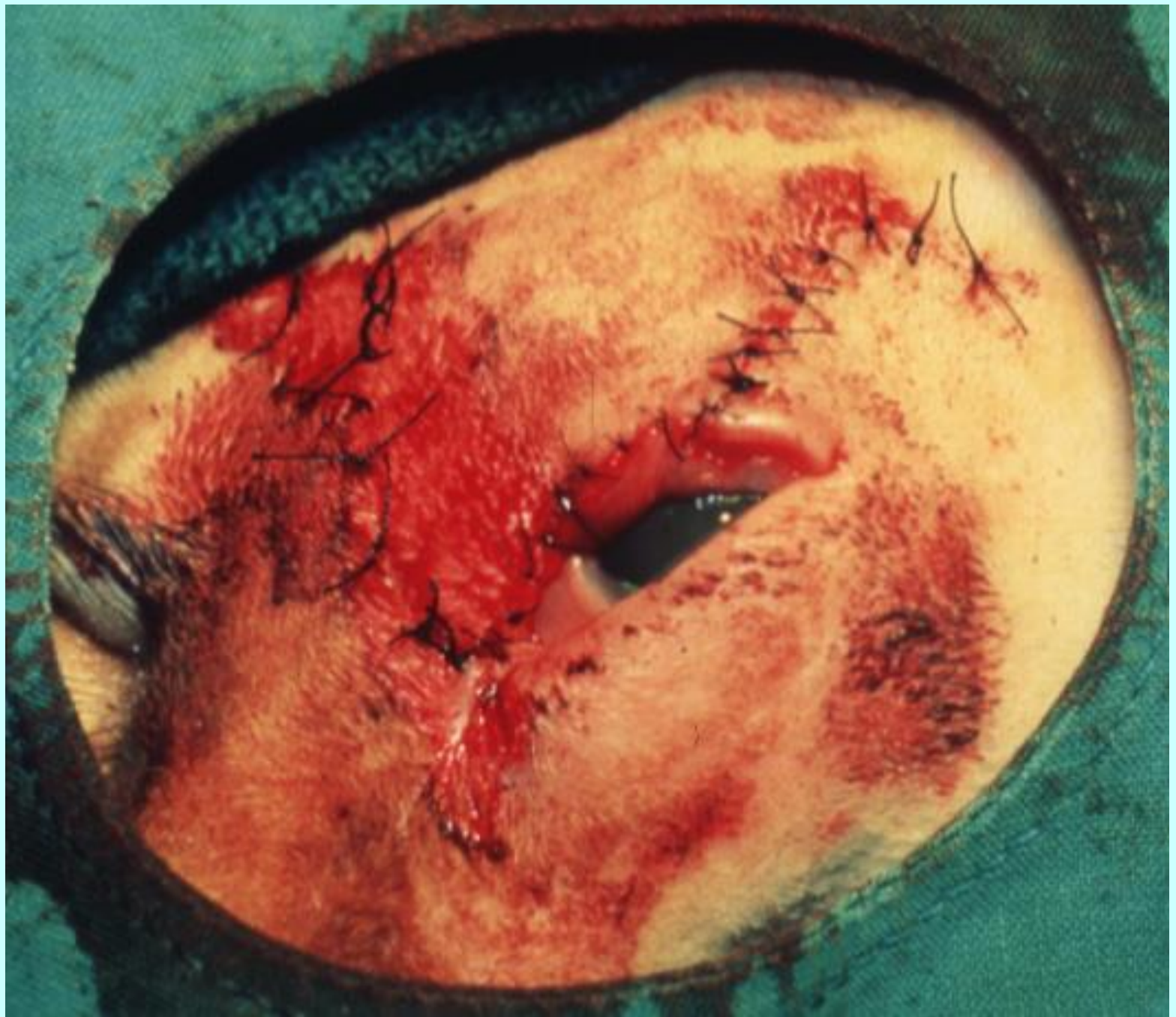



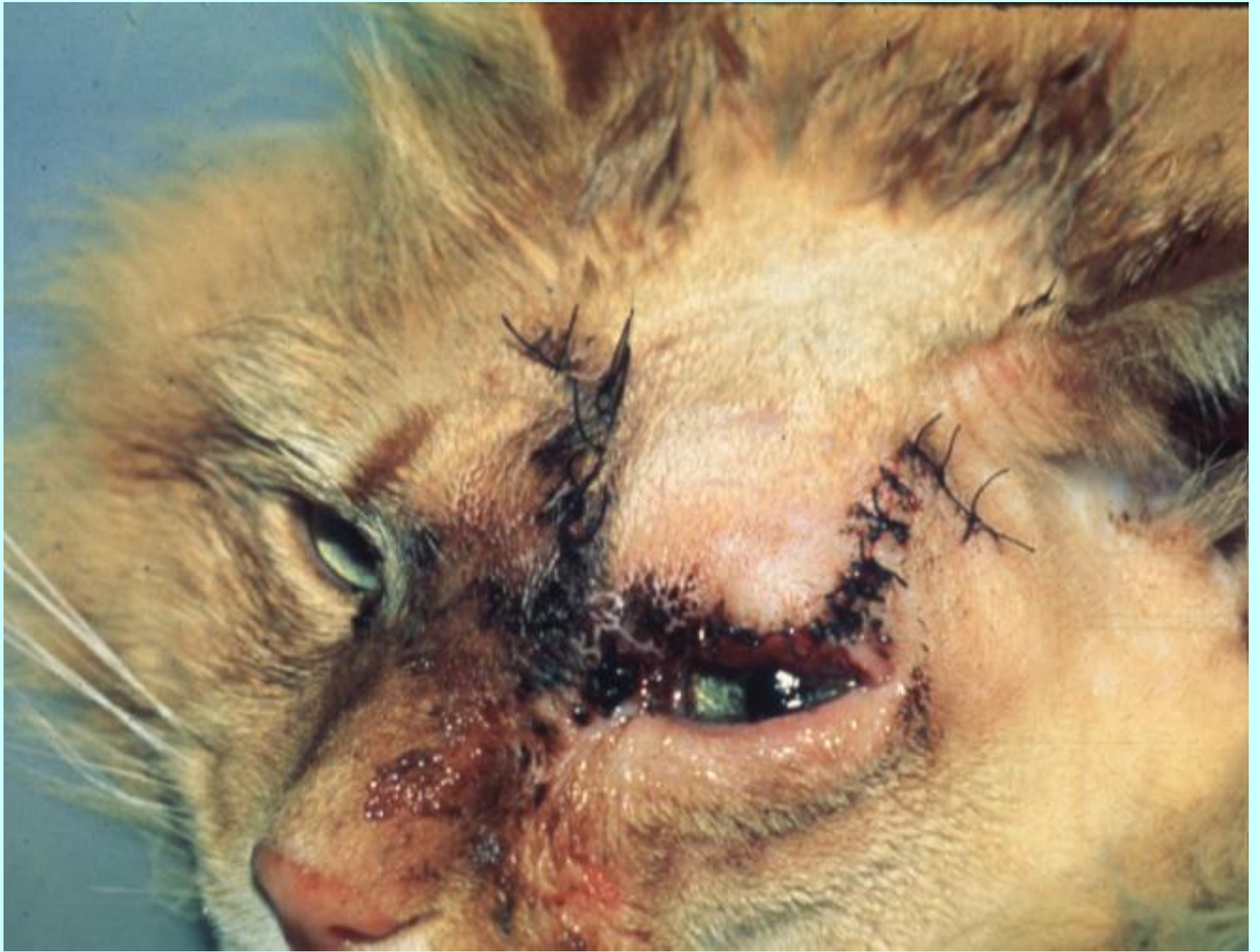




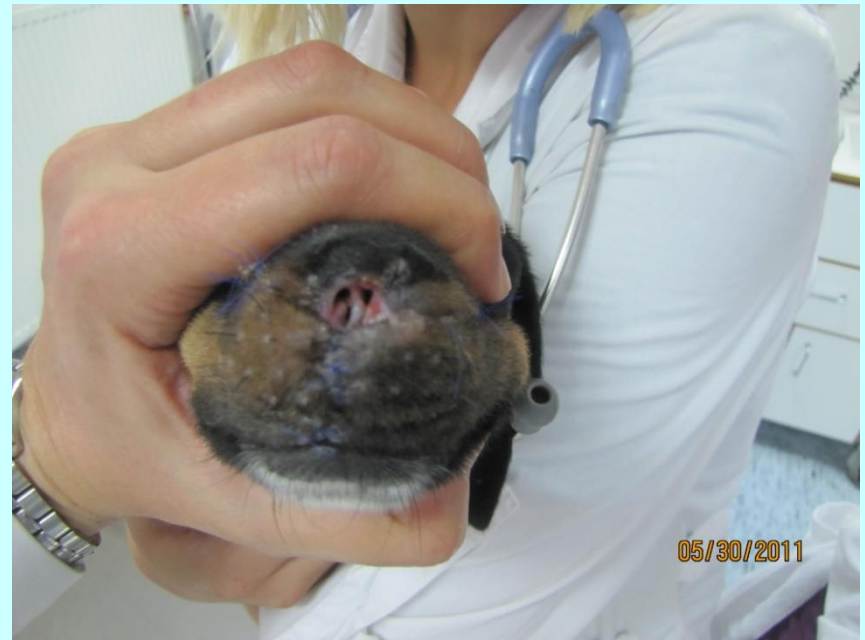
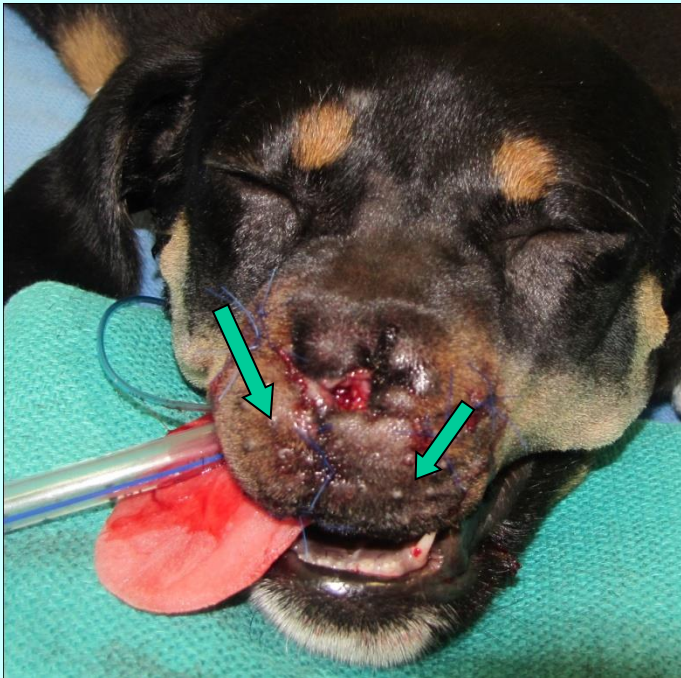
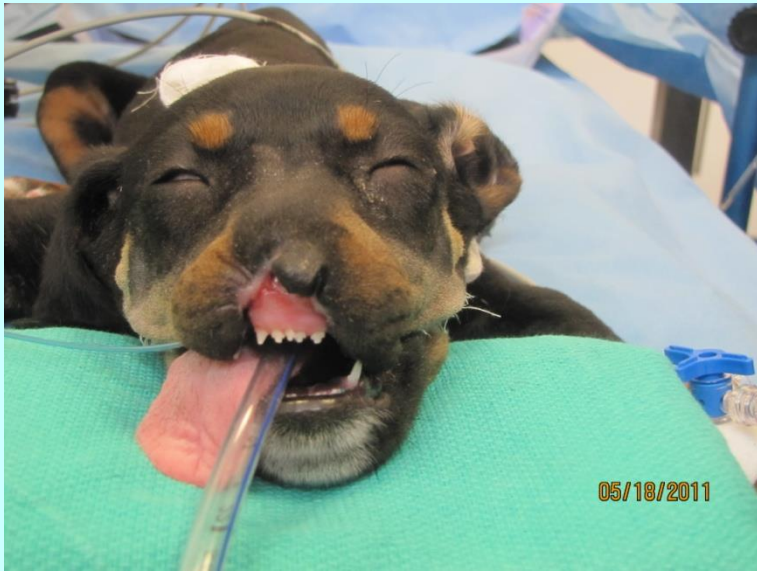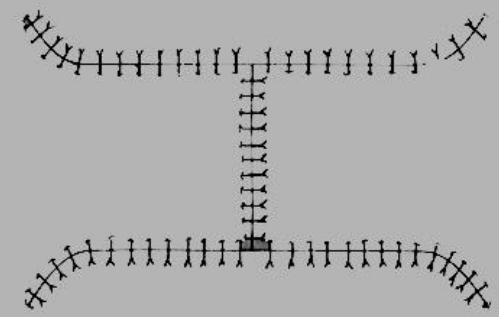
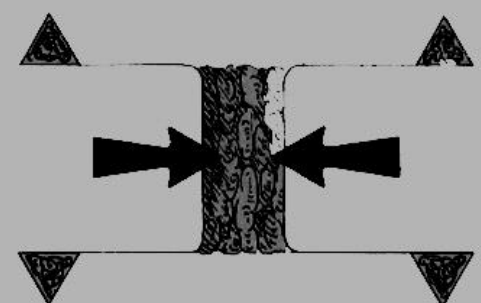

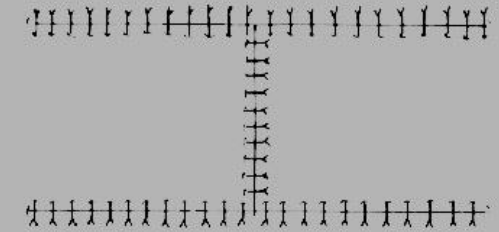




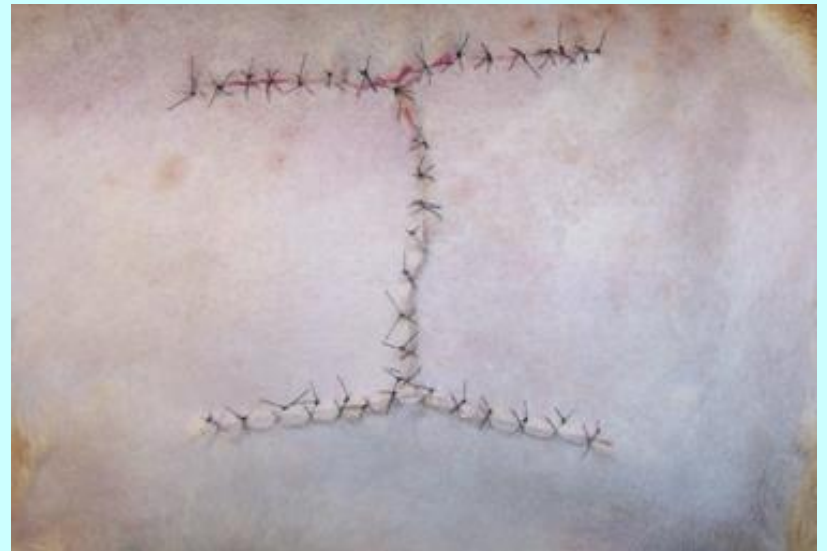
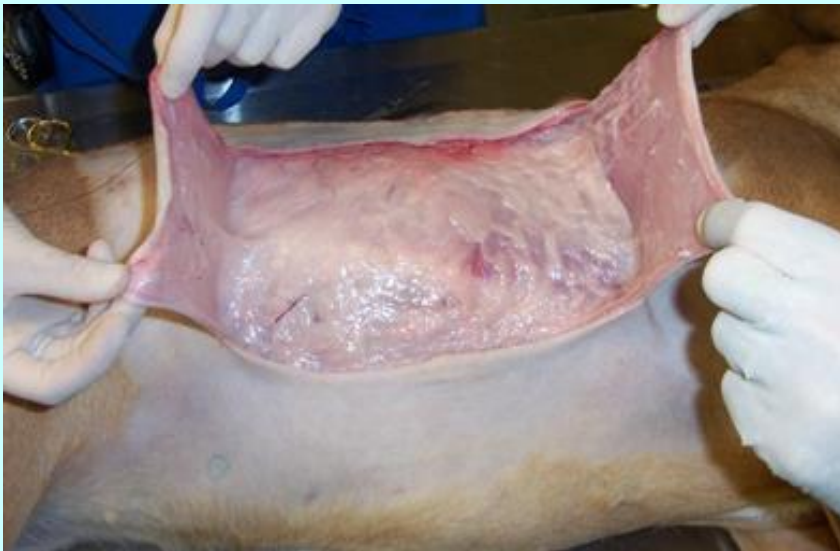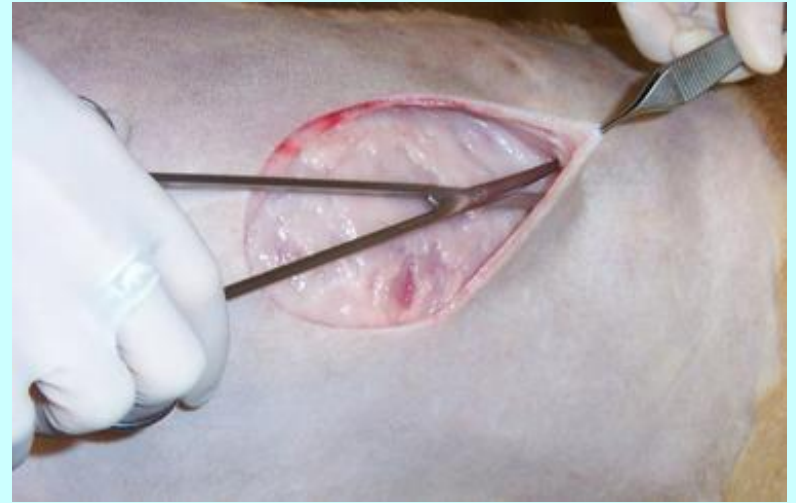


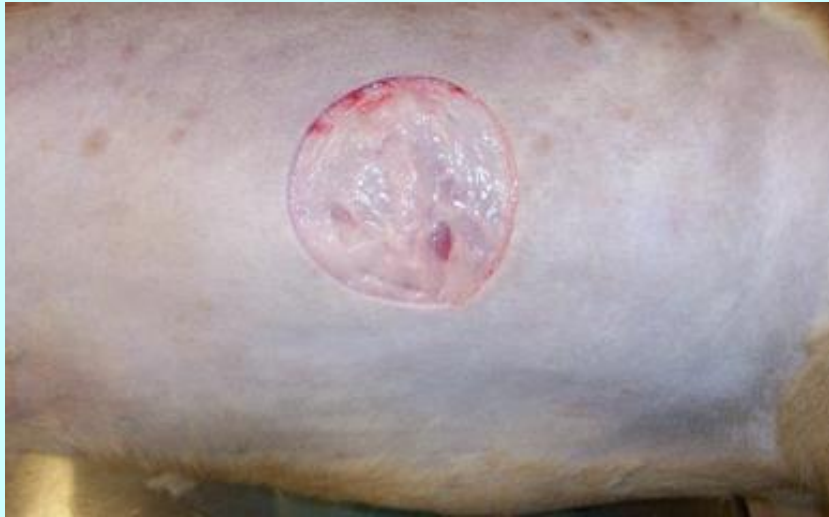Πρωθητικός κρημνός με δύο μίσχους-πλαστική Η



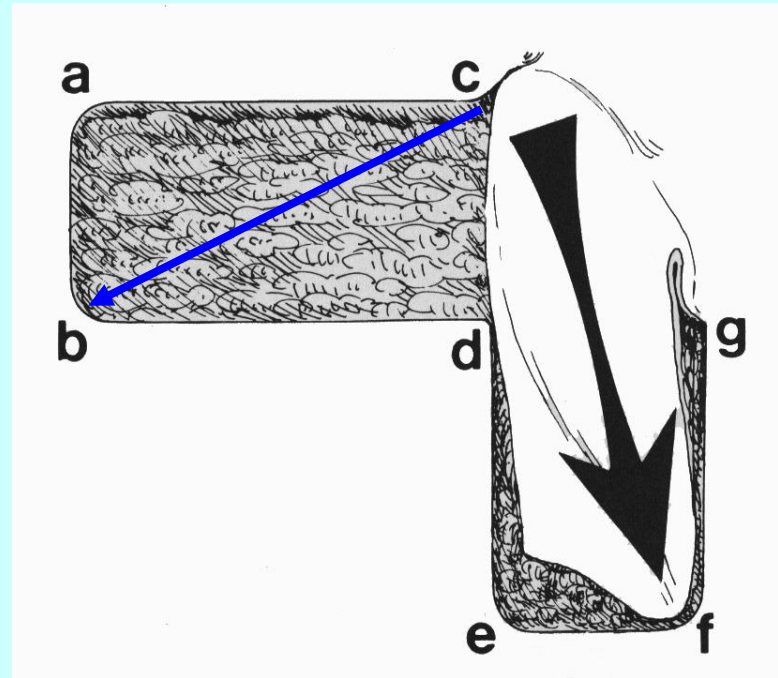
12 days postop

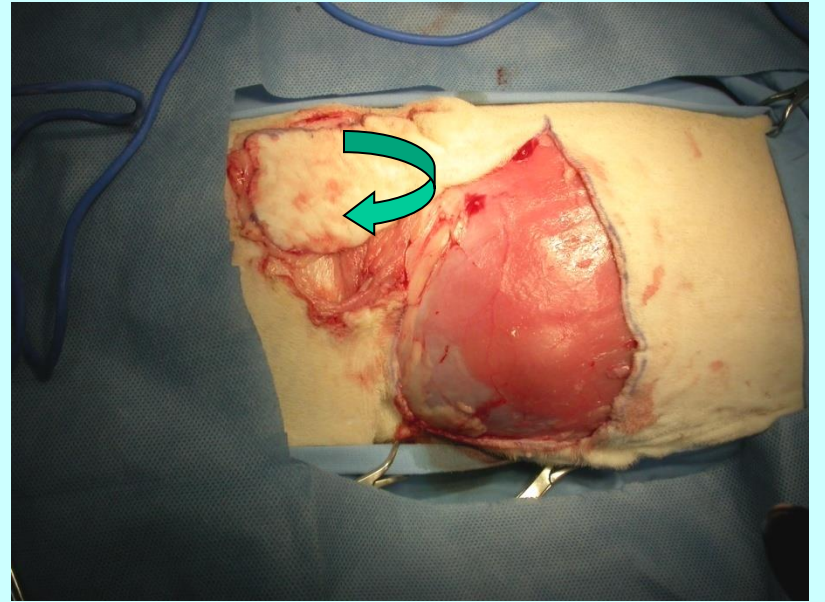
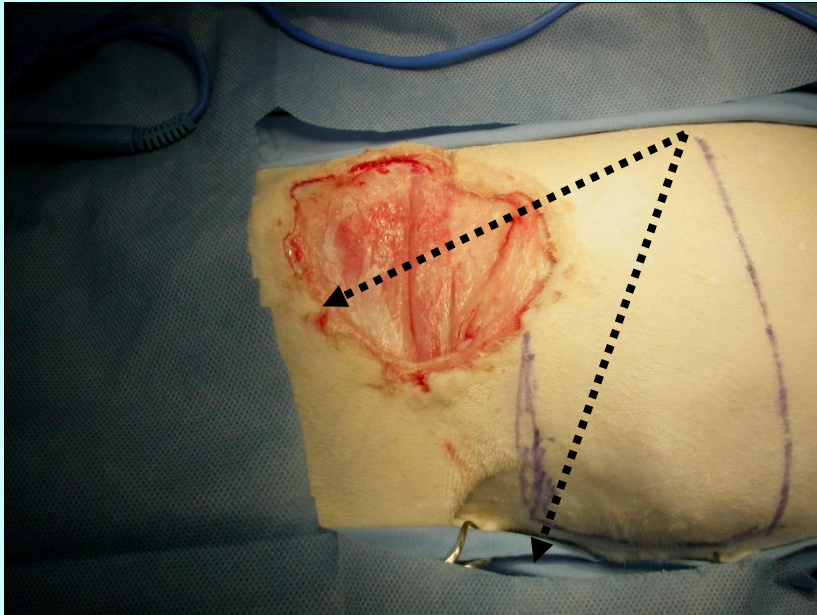
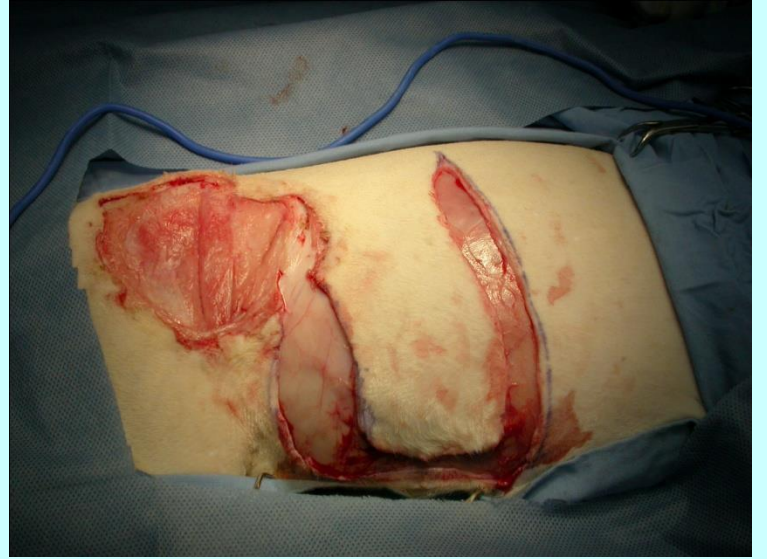
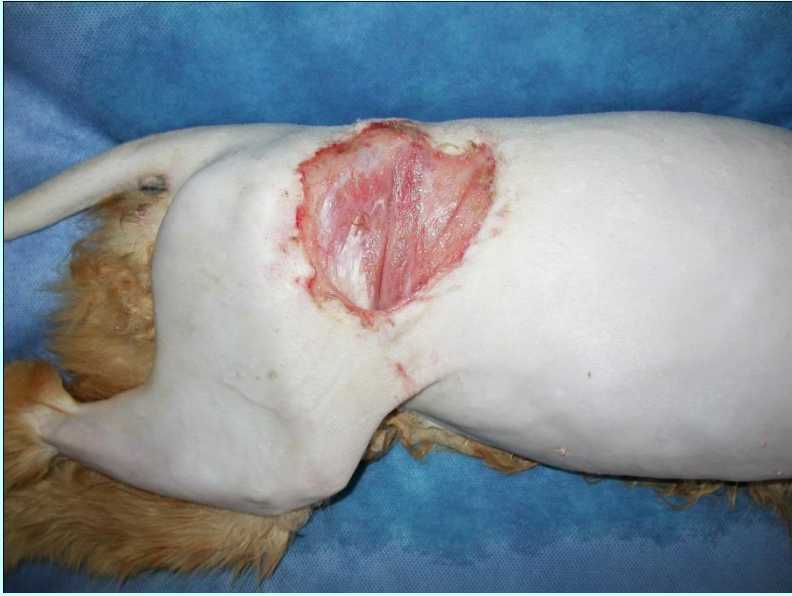


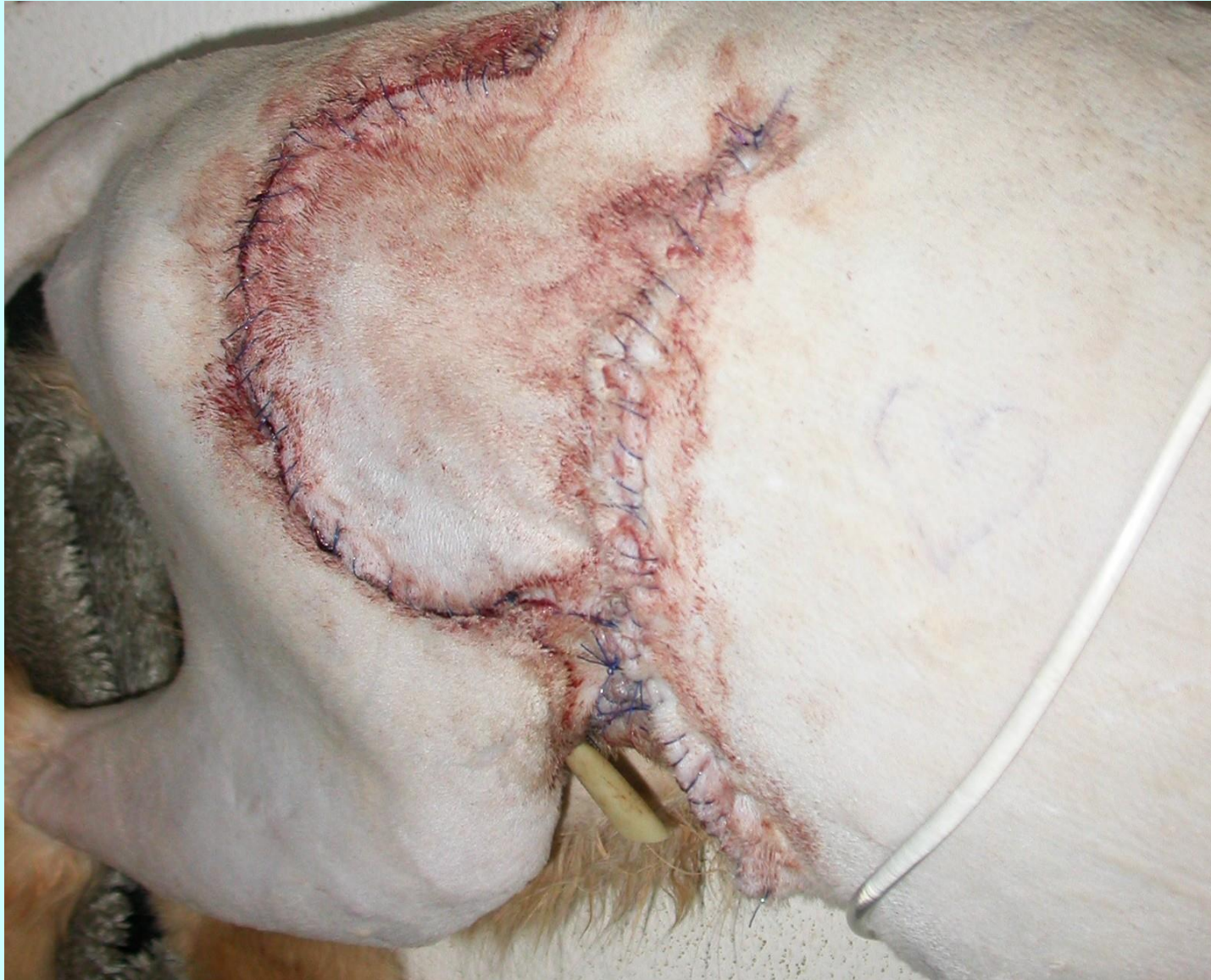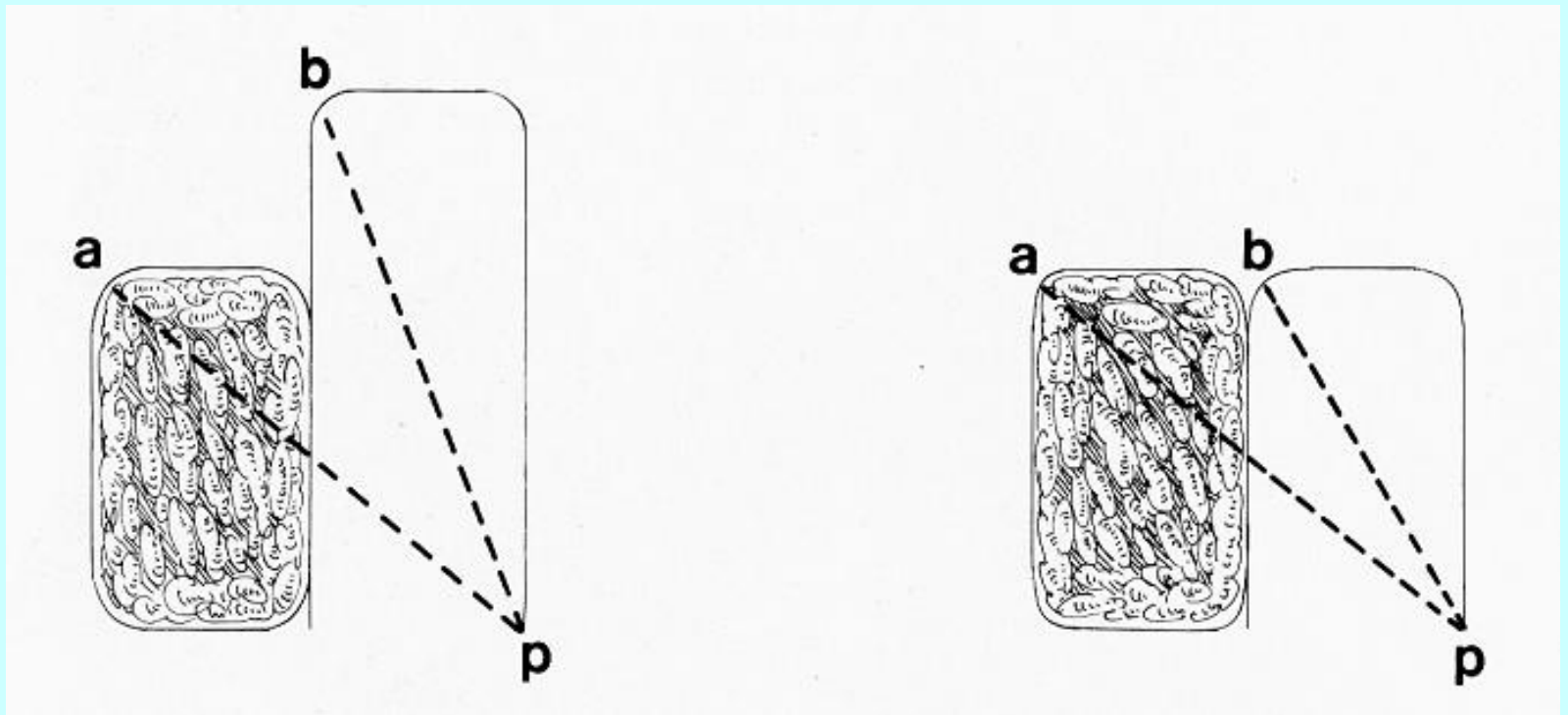
Μεταθετικός κρημνός

$cd=dg$
 $cb=cf$
 $bg > 2 \times cd$



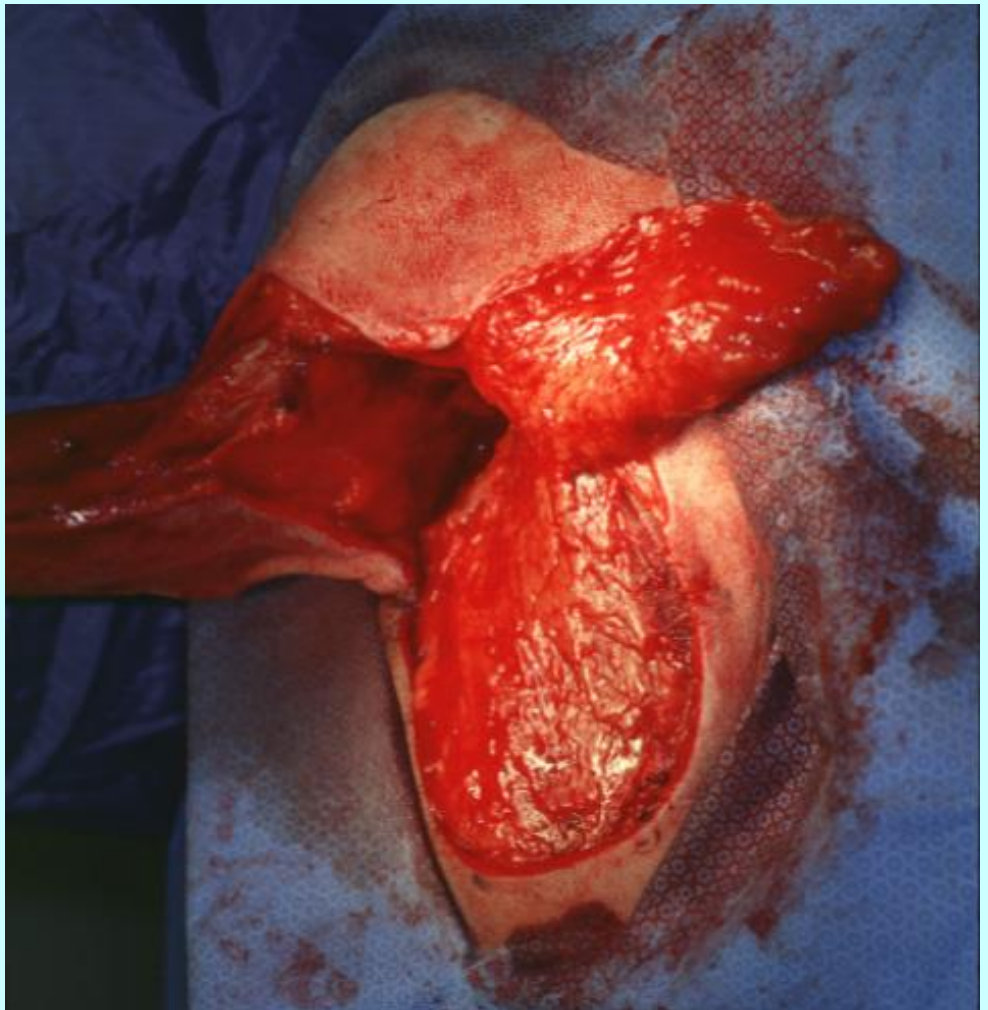
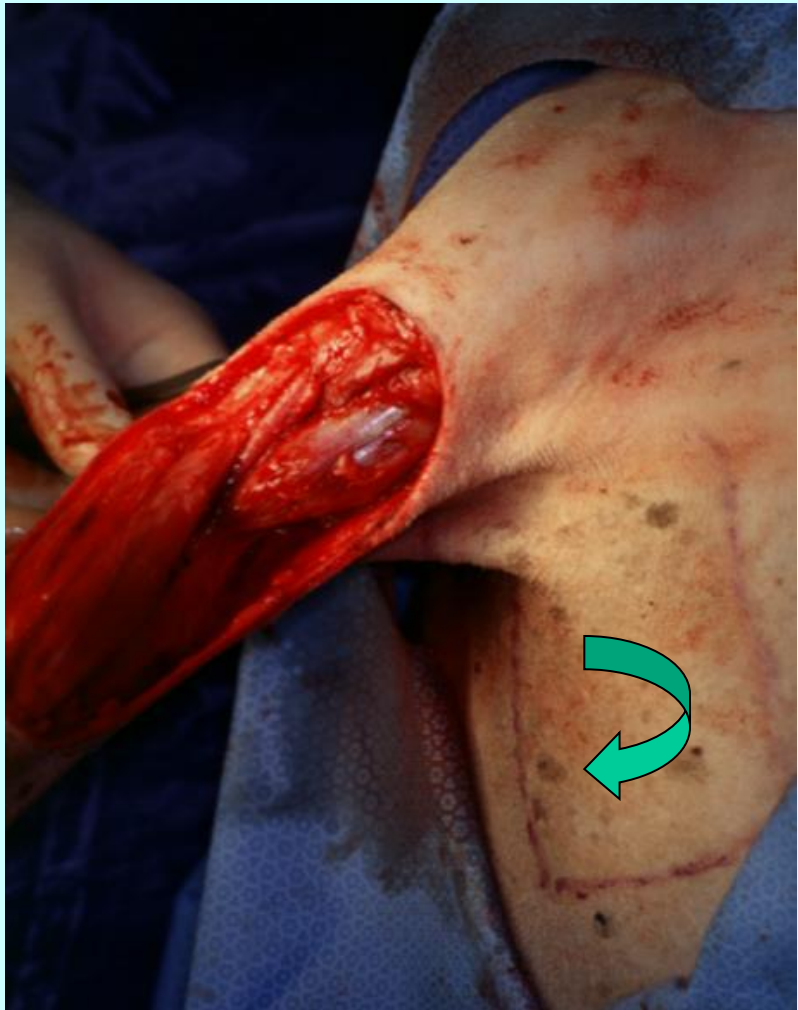


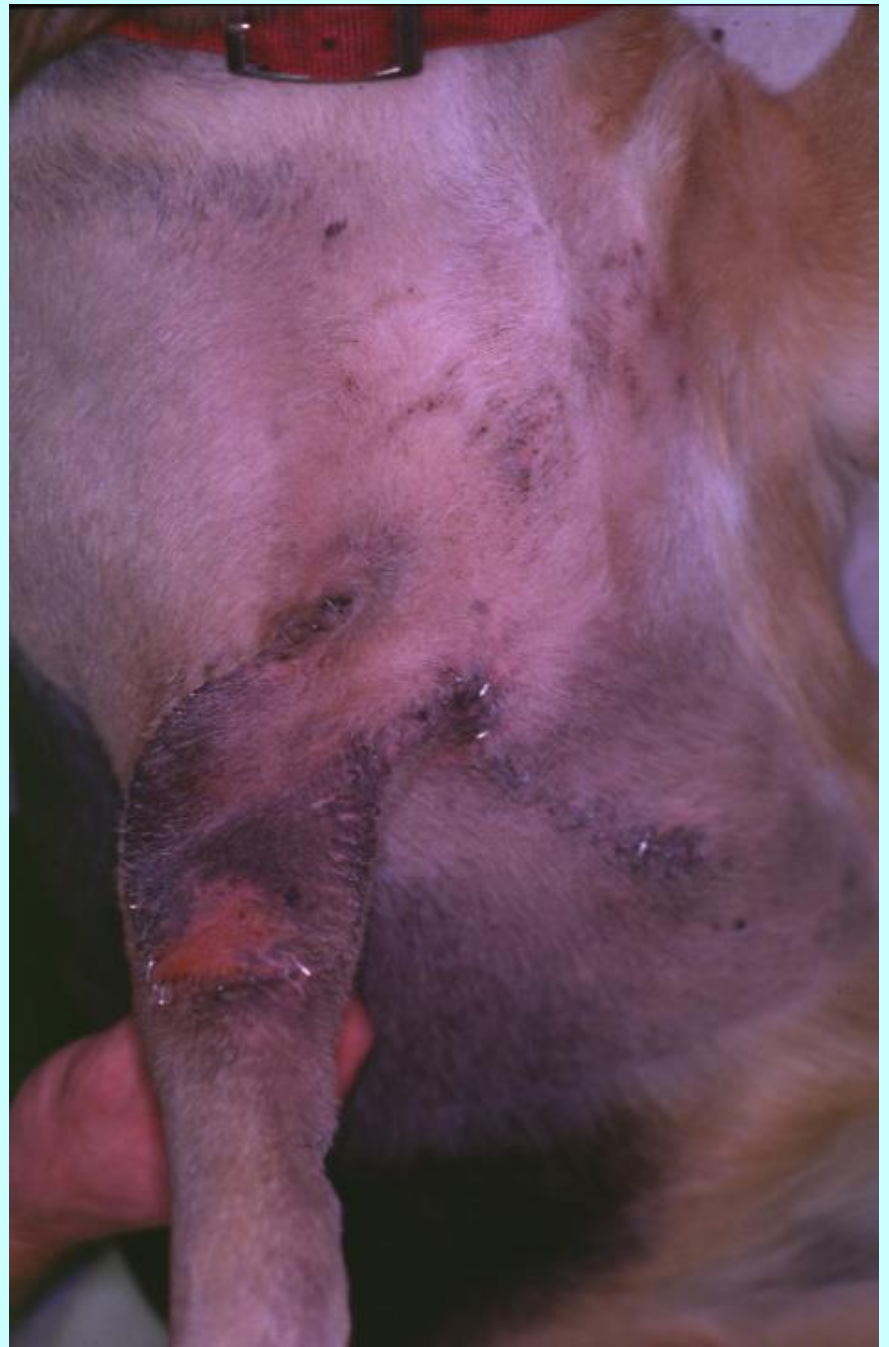
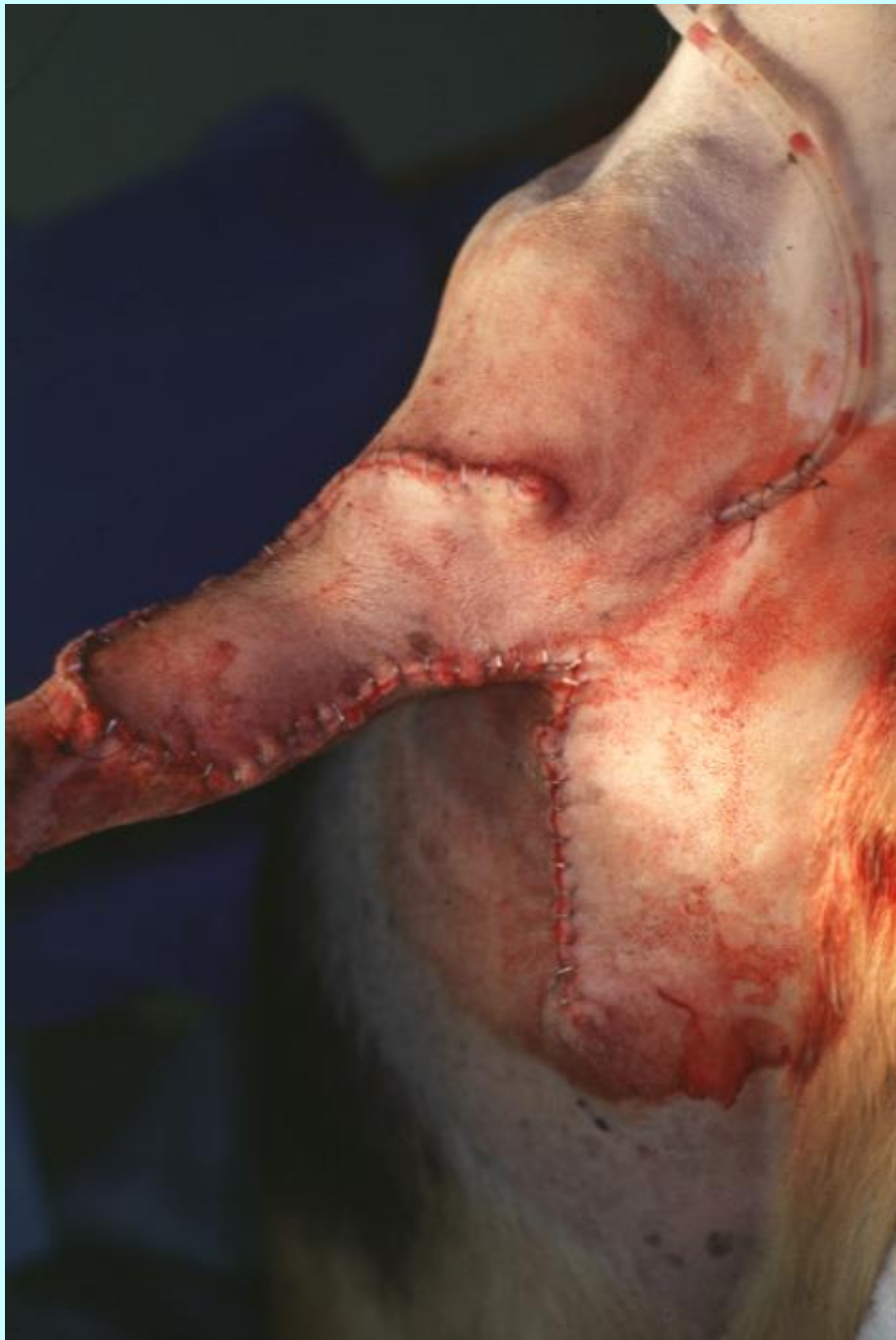


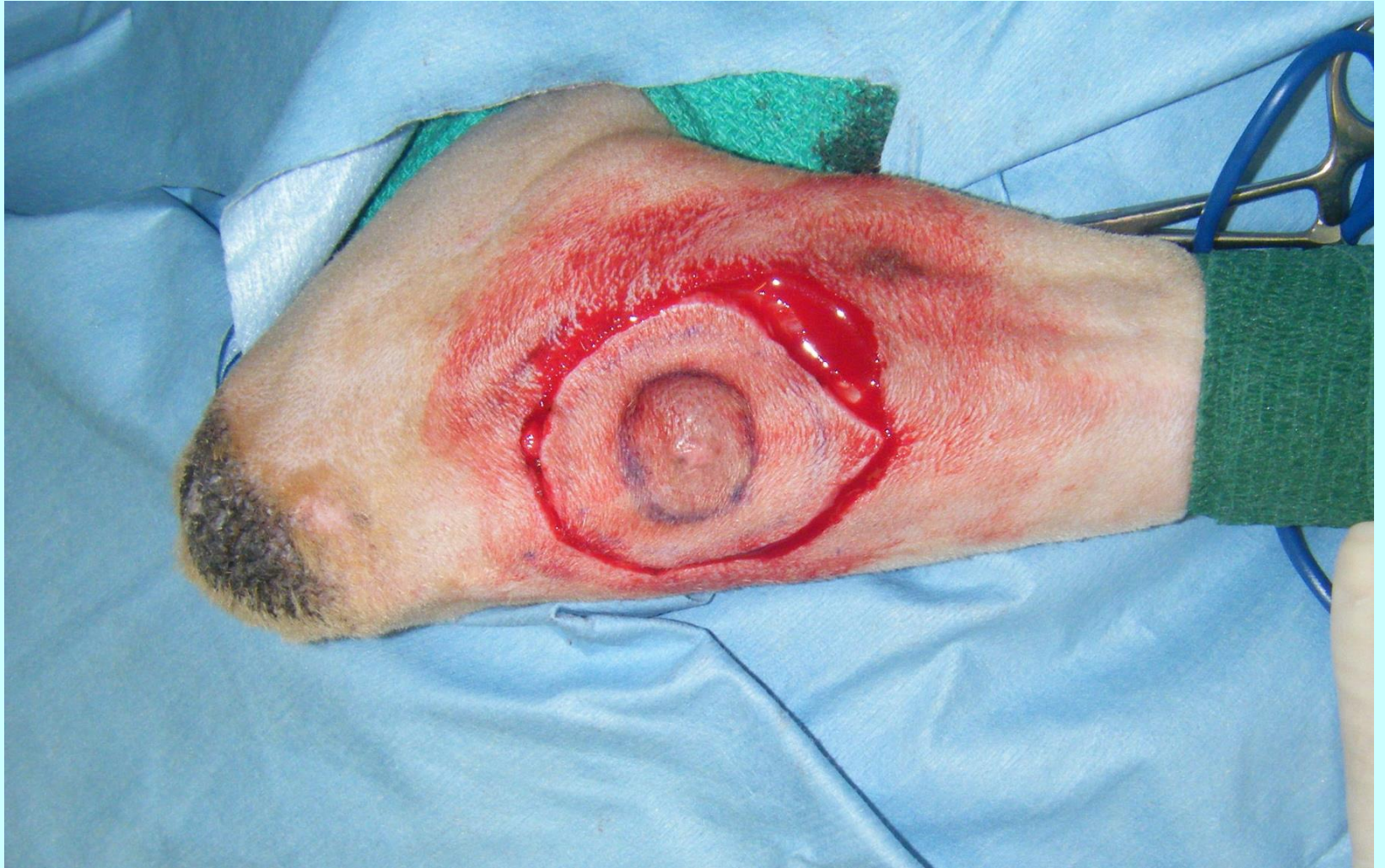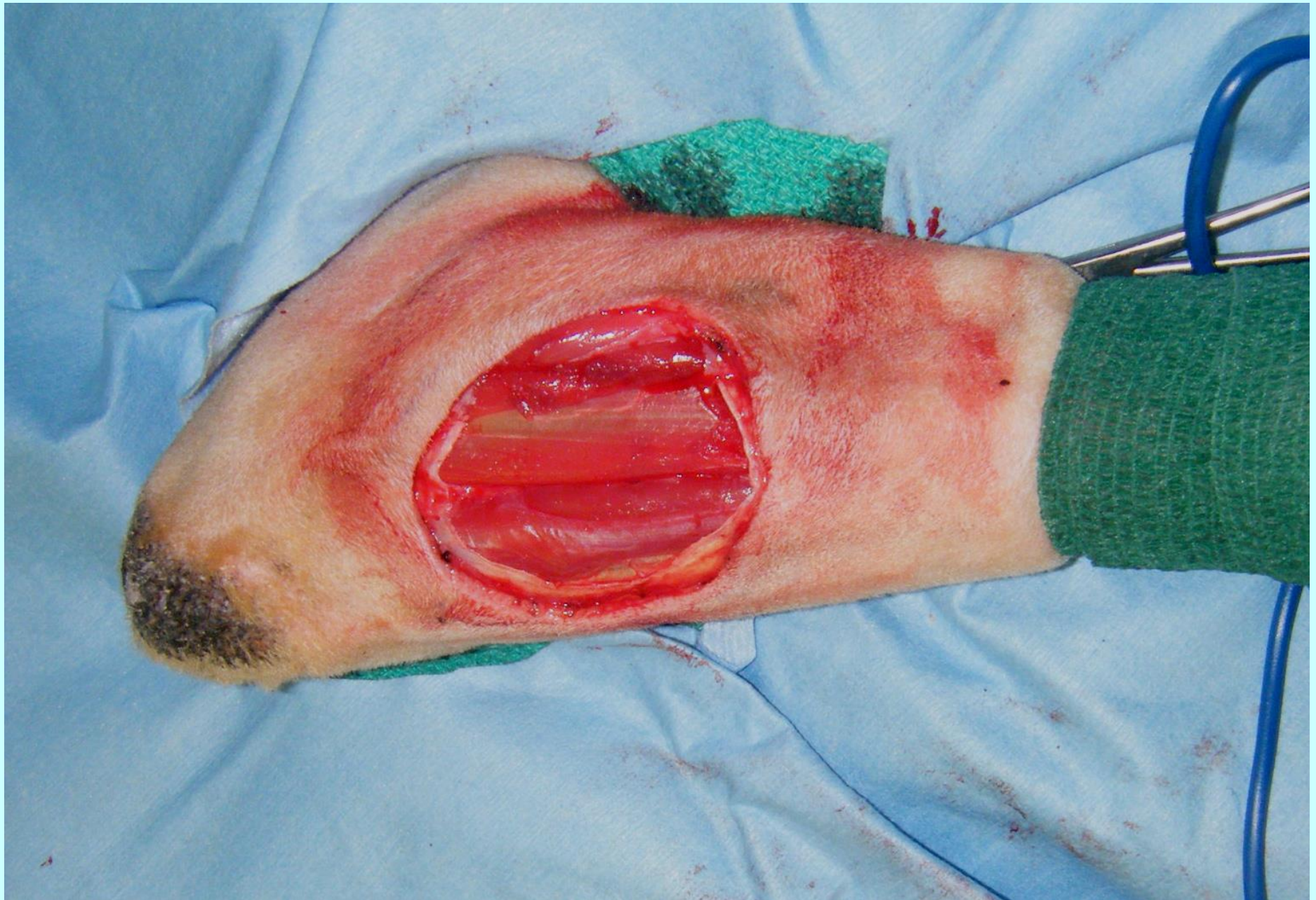$ap=bp=$ όχι τάση

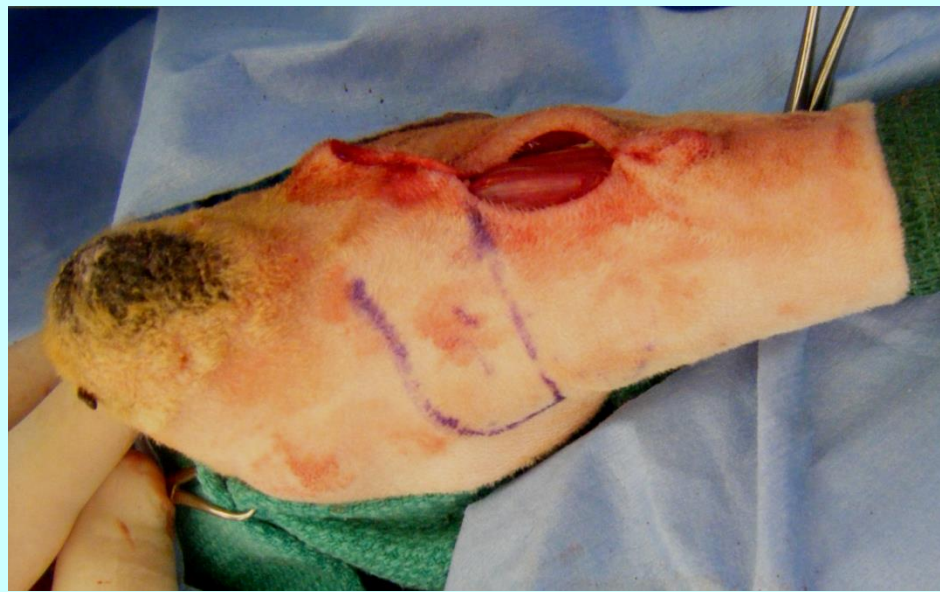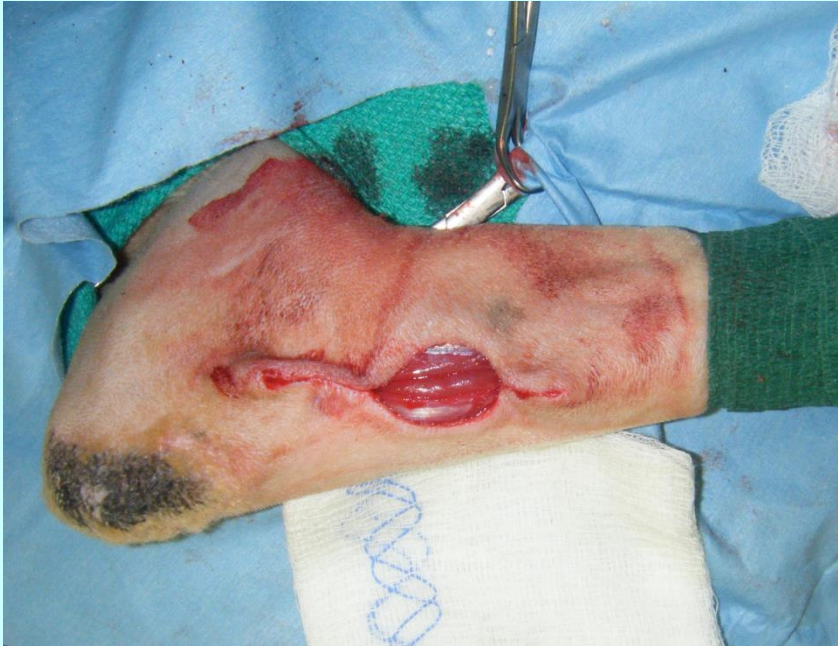$bp<ap=$ τάση

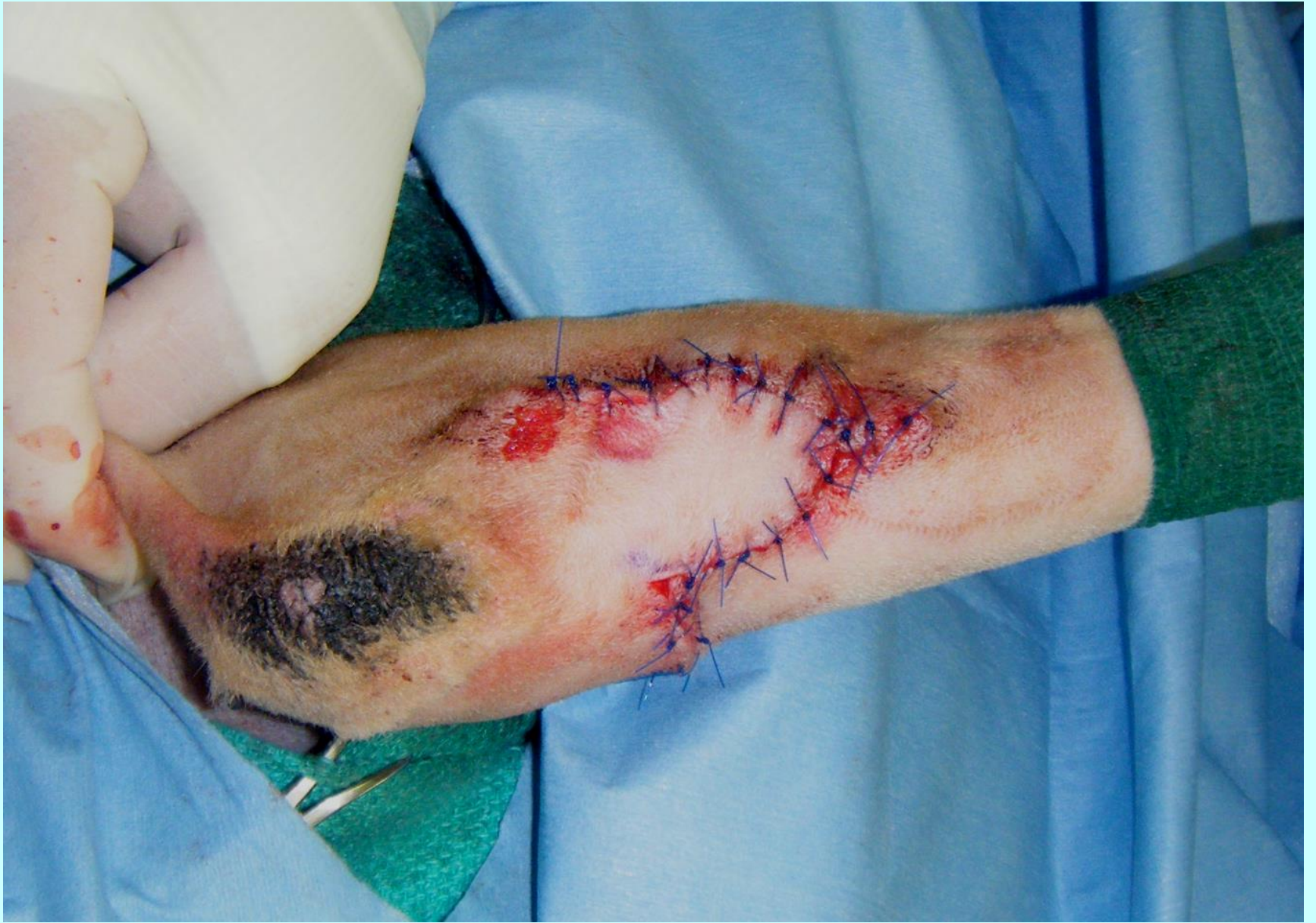

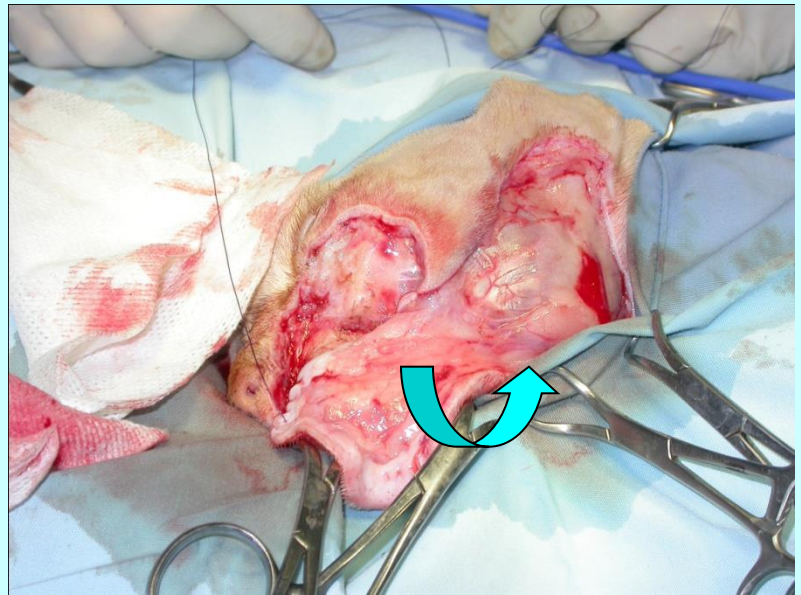
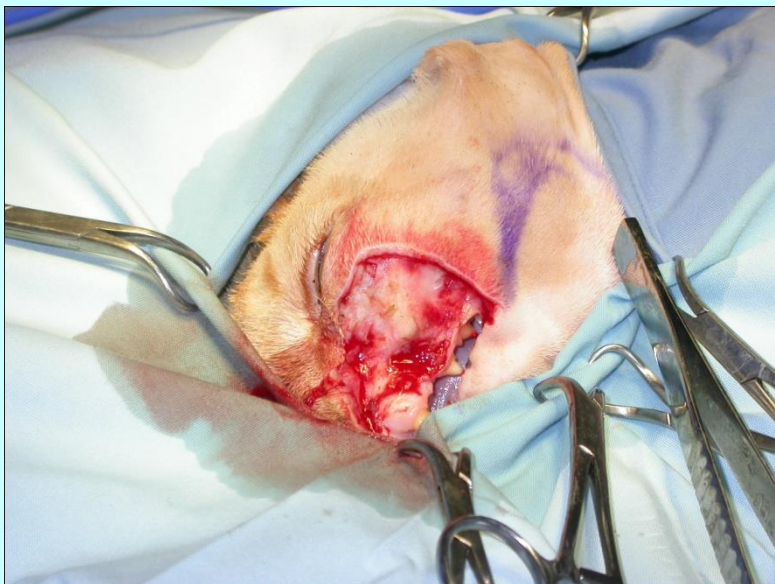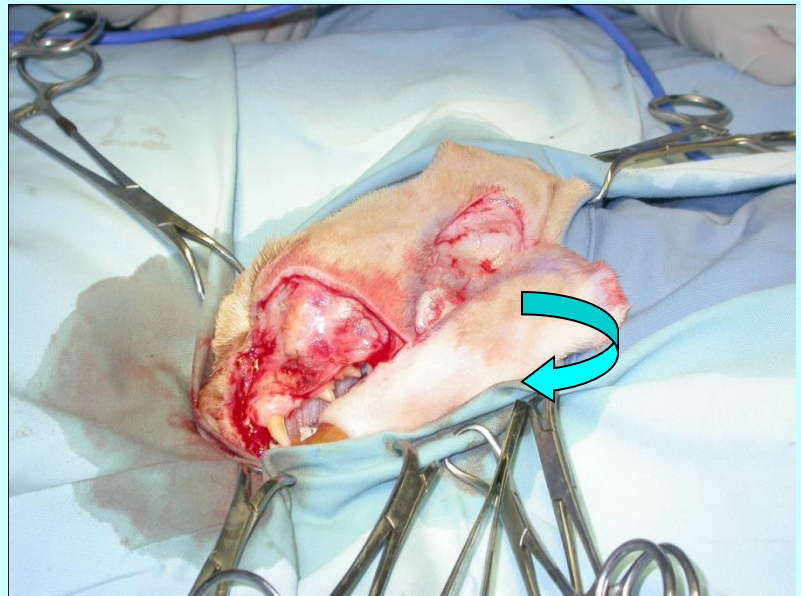


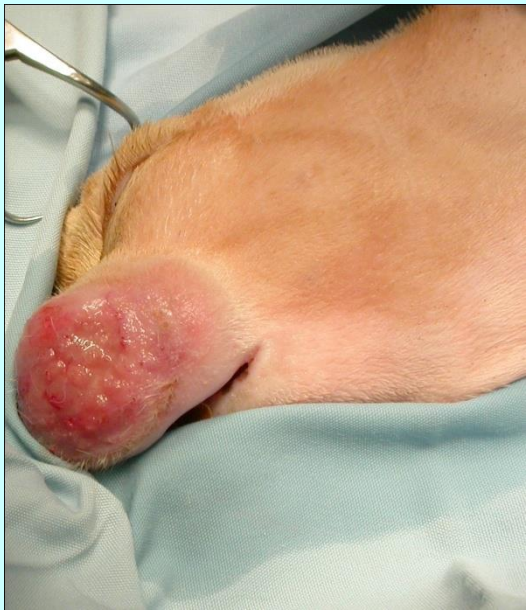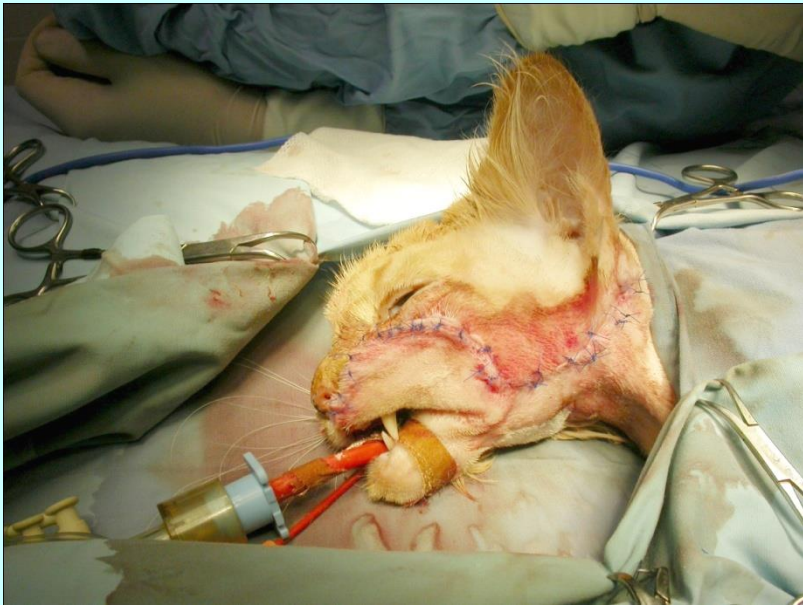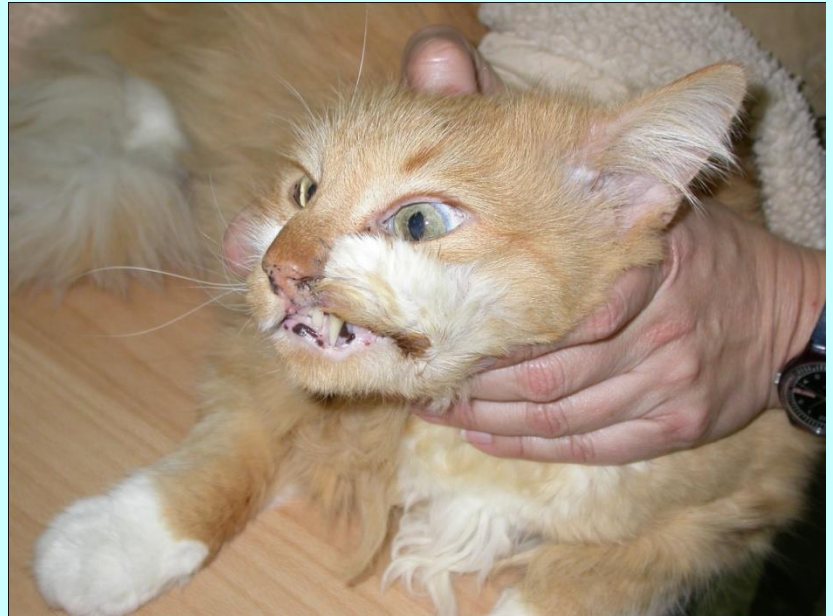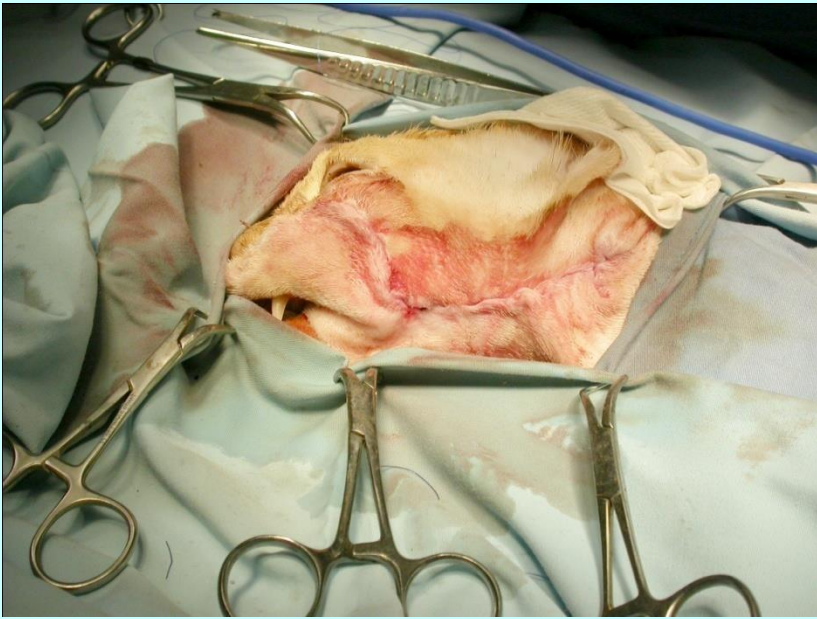












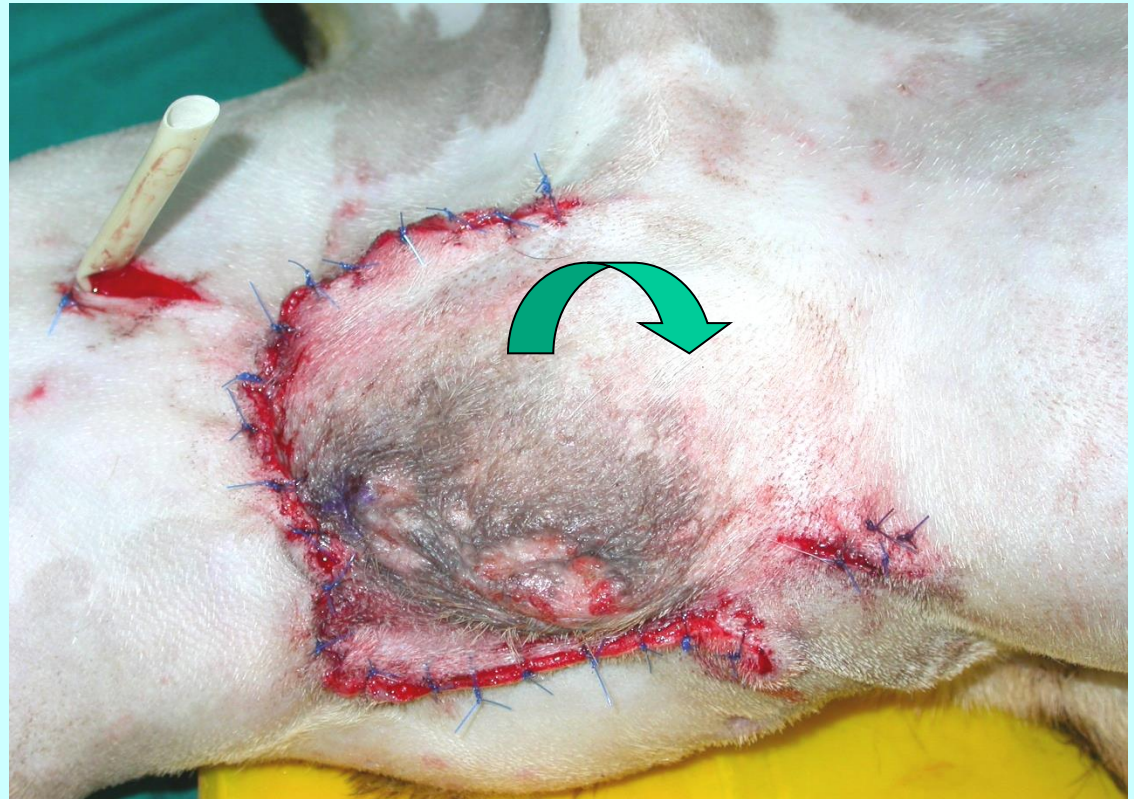
1 month postop

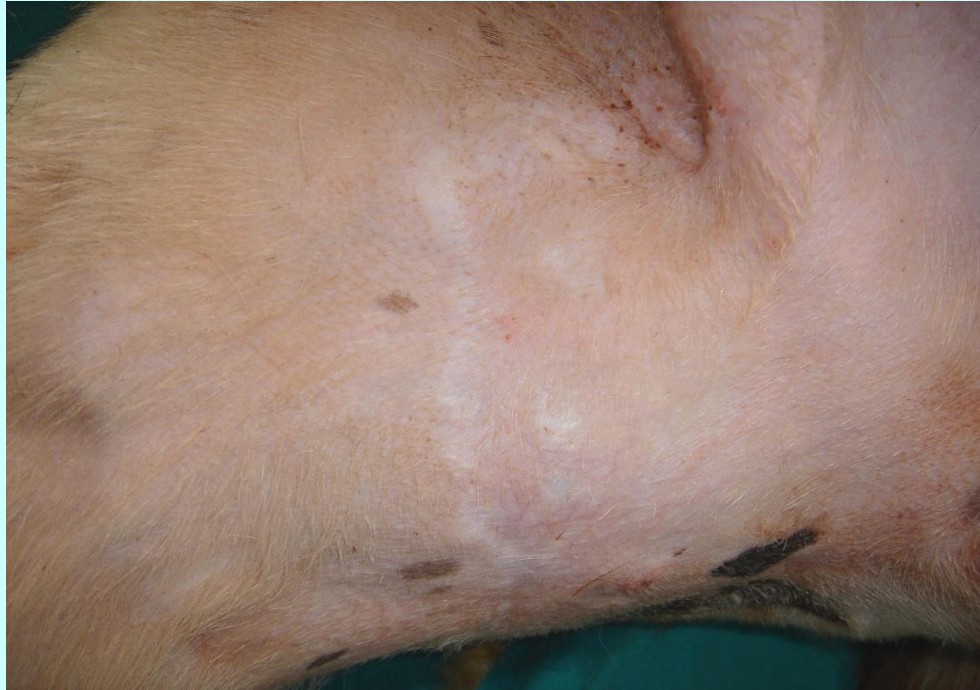Μεταθετικός κρημνός του οσχέου

Περίνεο

Ακροποσθία

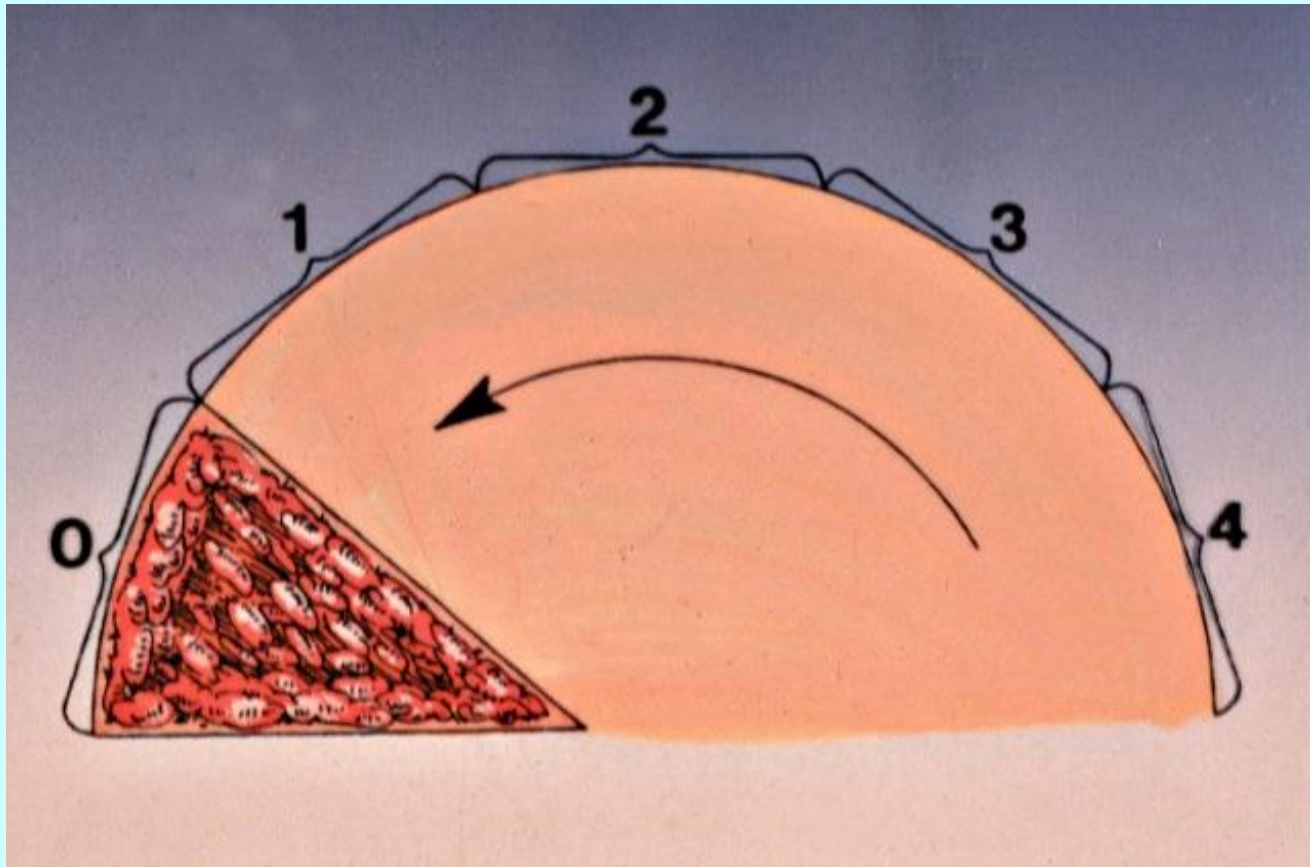
Έσω μηριαία
χώρα

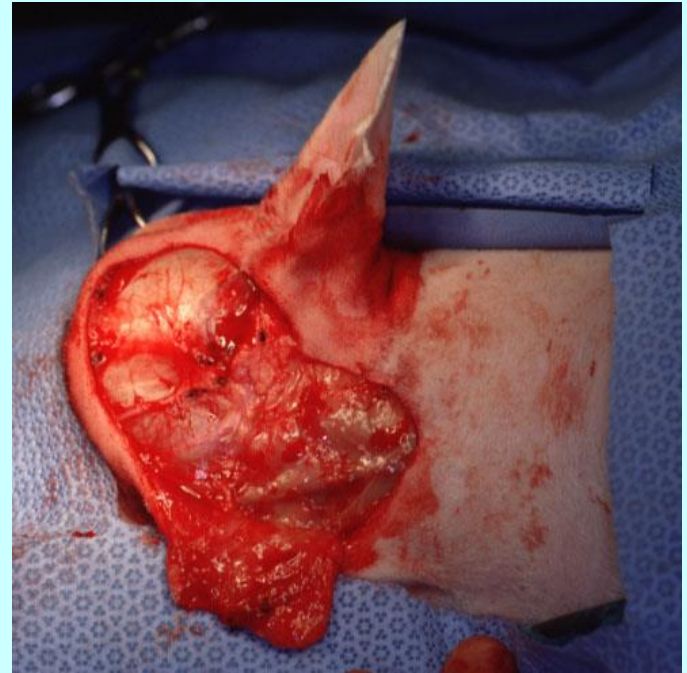
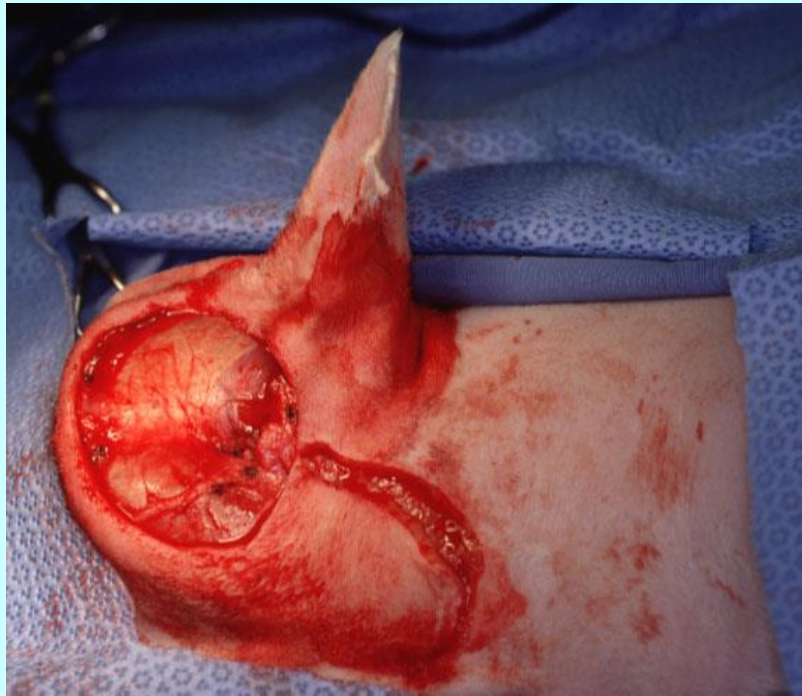
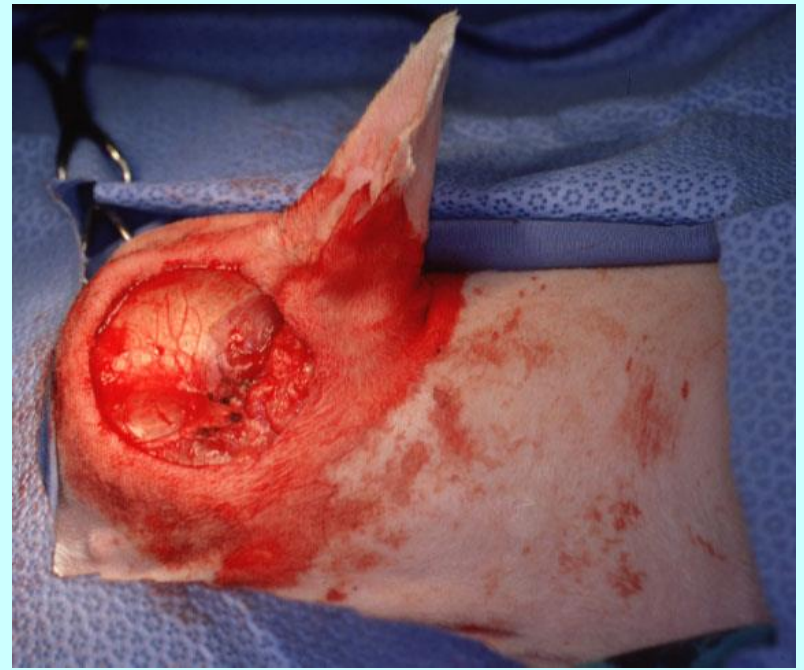
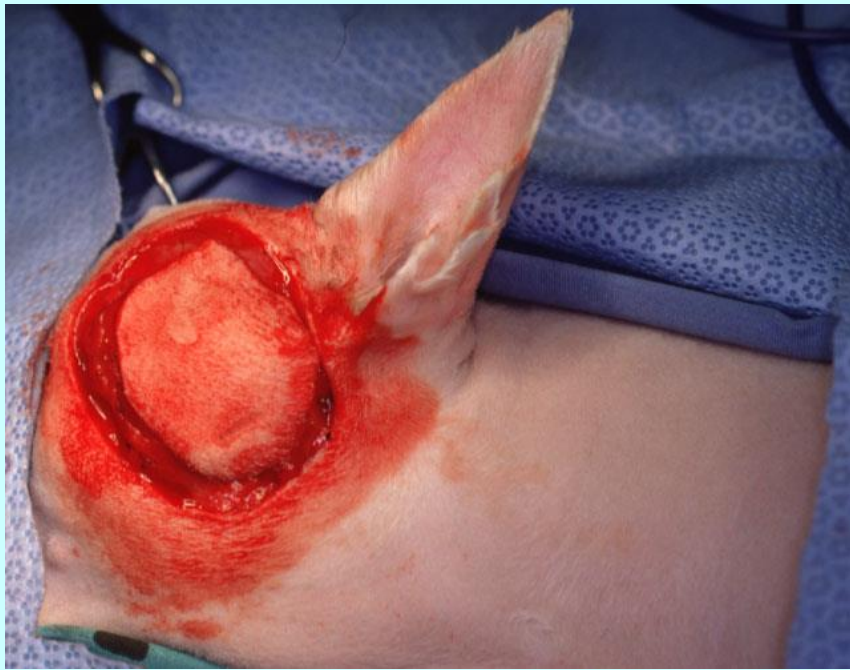
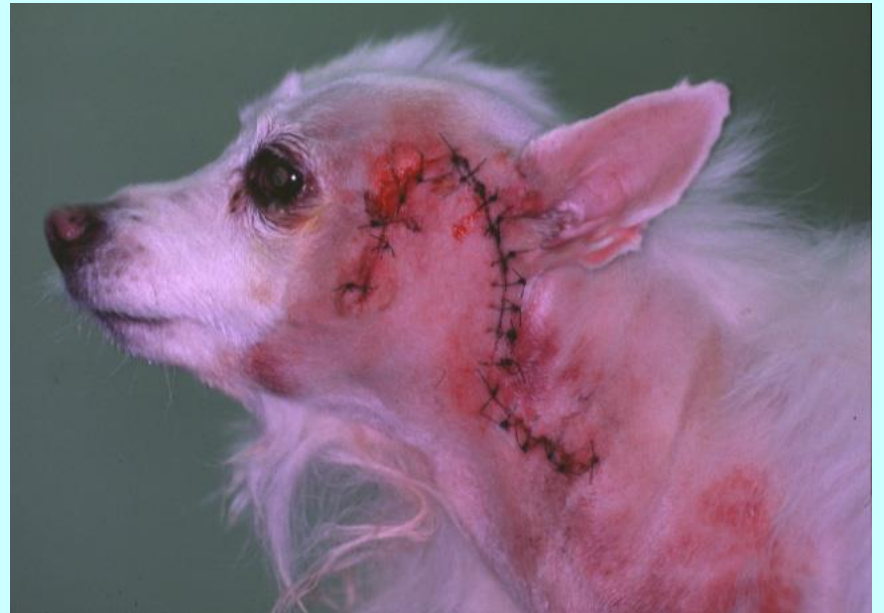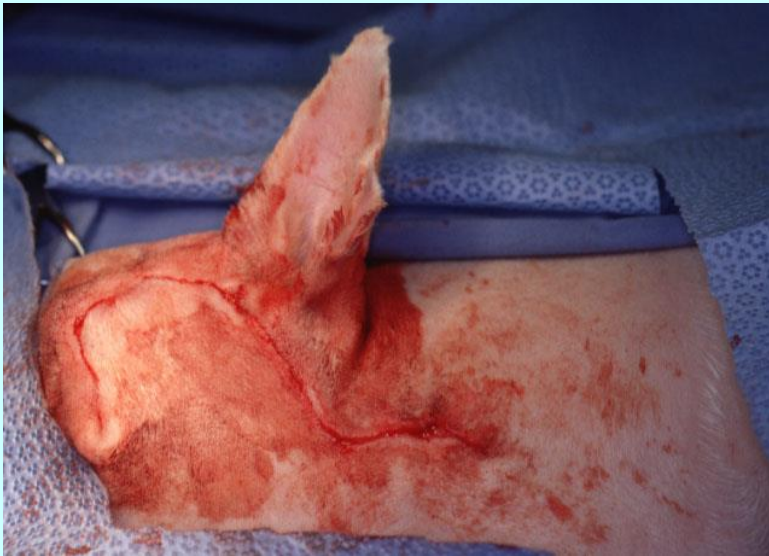
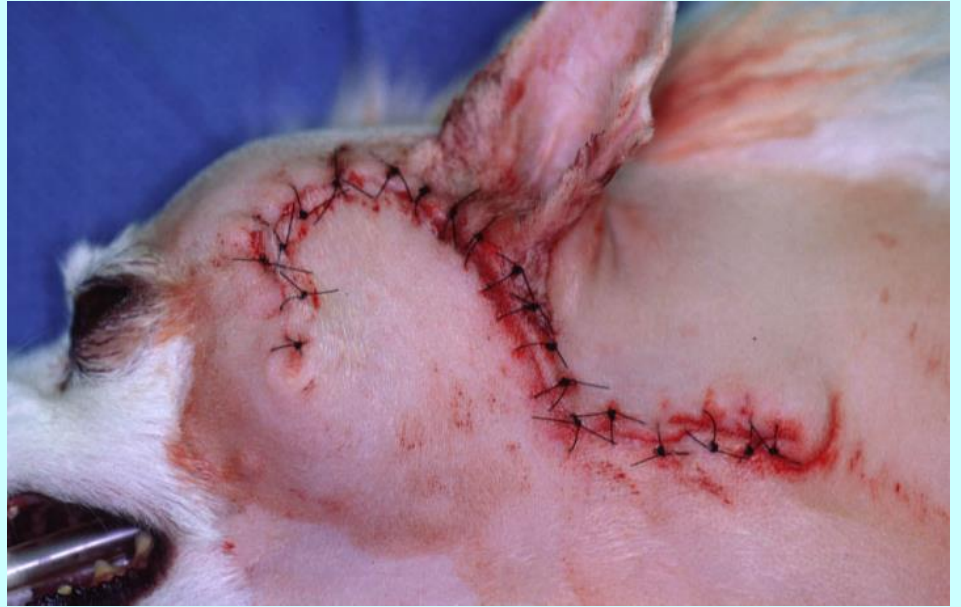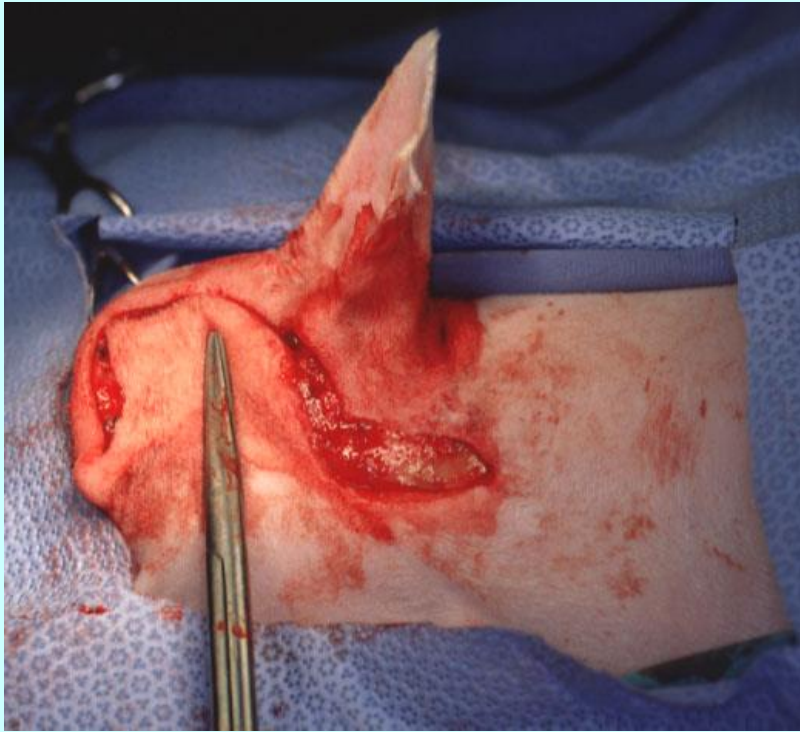


Μετά από 1 έτος

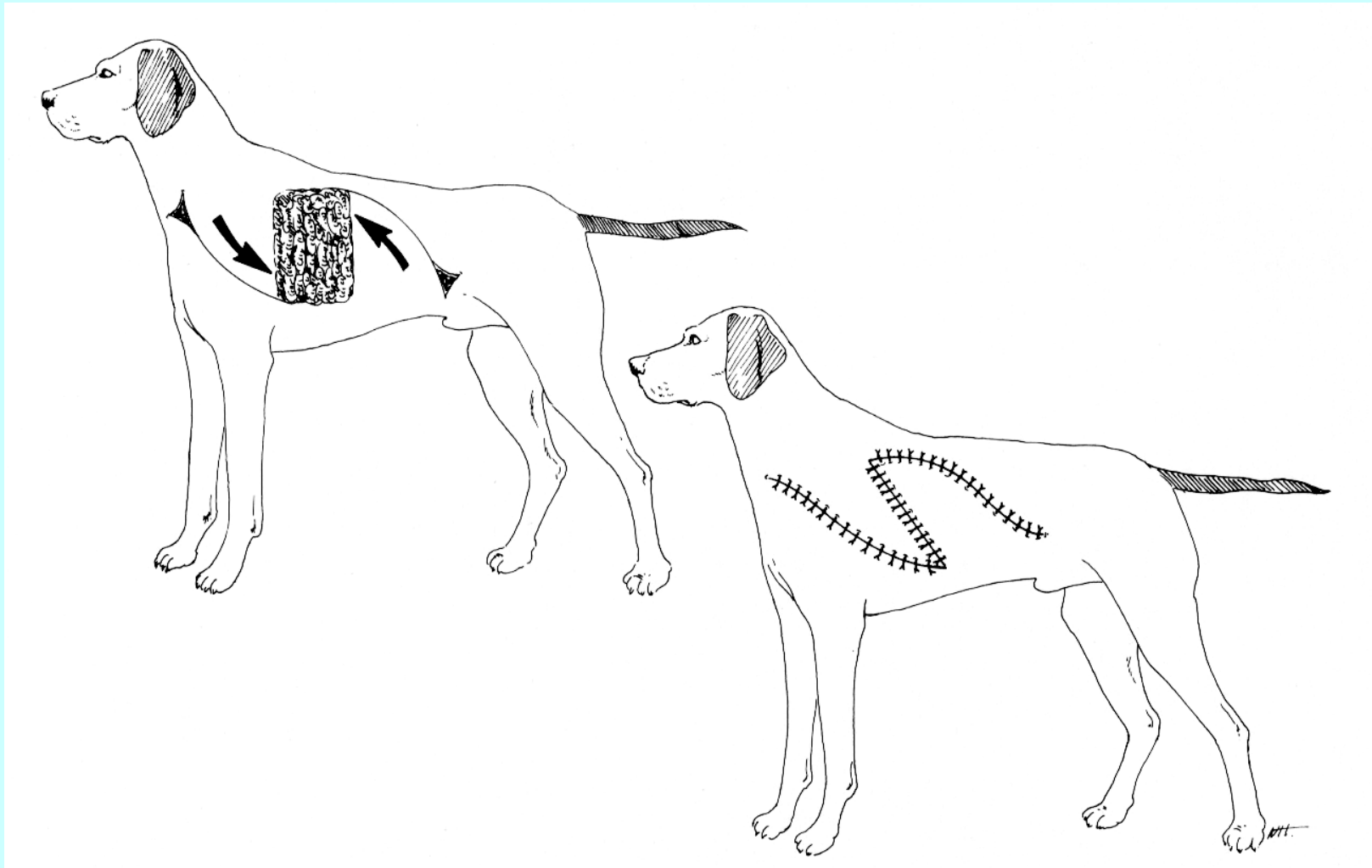
Περιστροφικός κρημνός

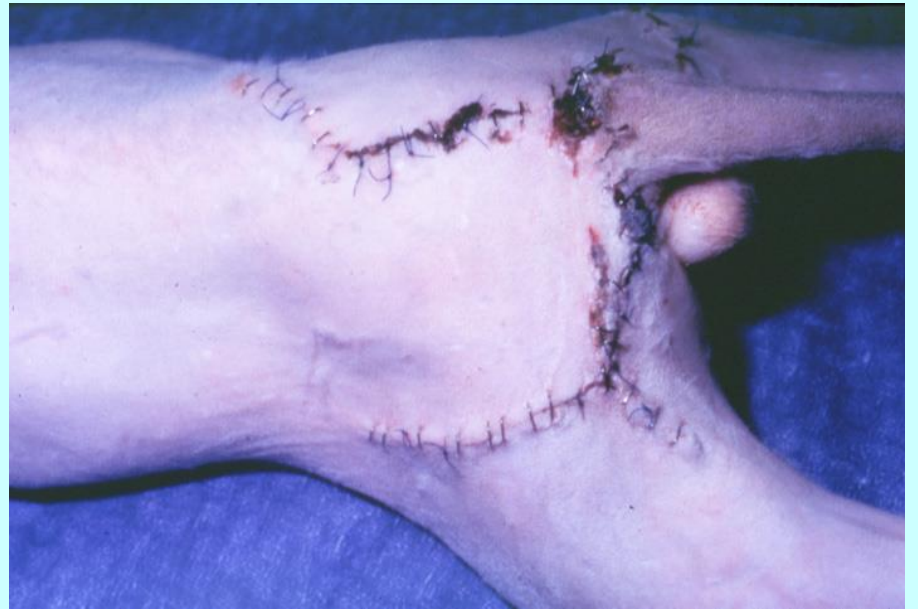
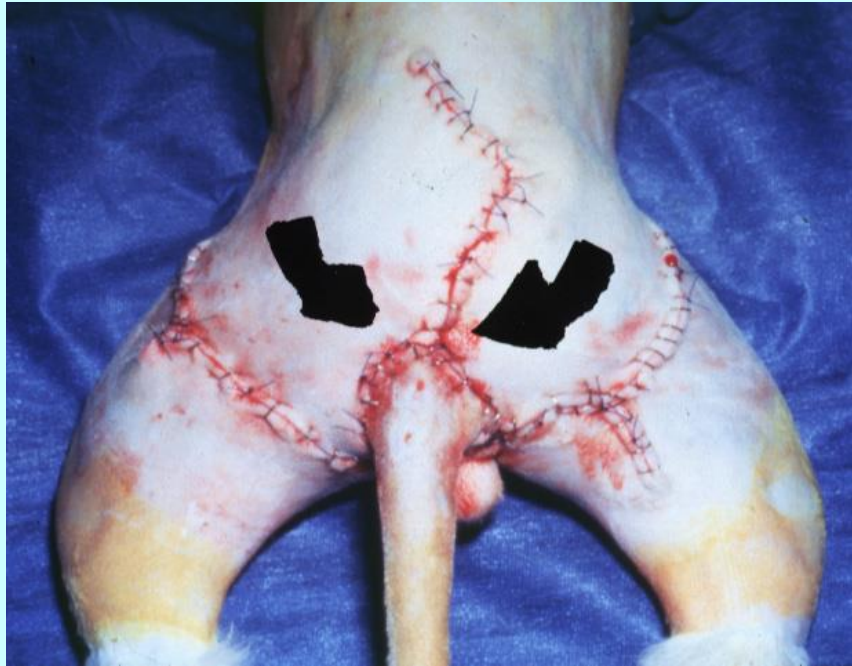
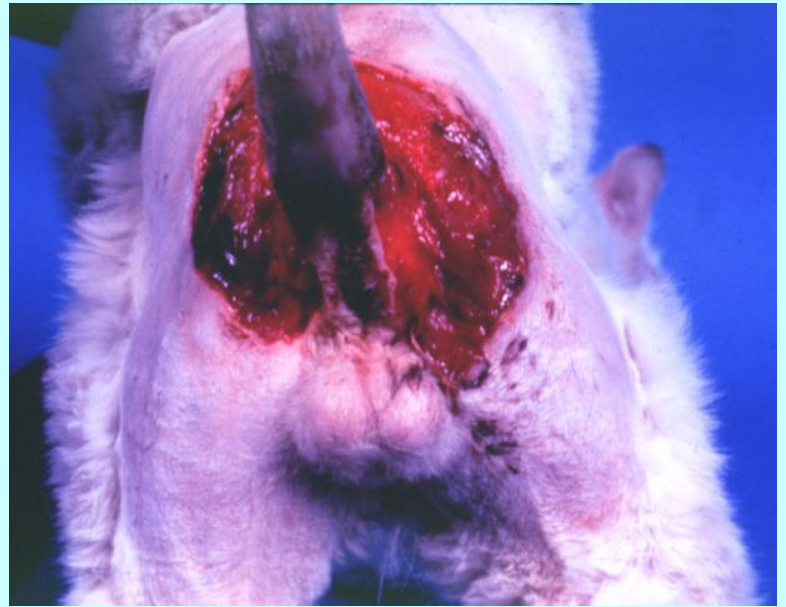
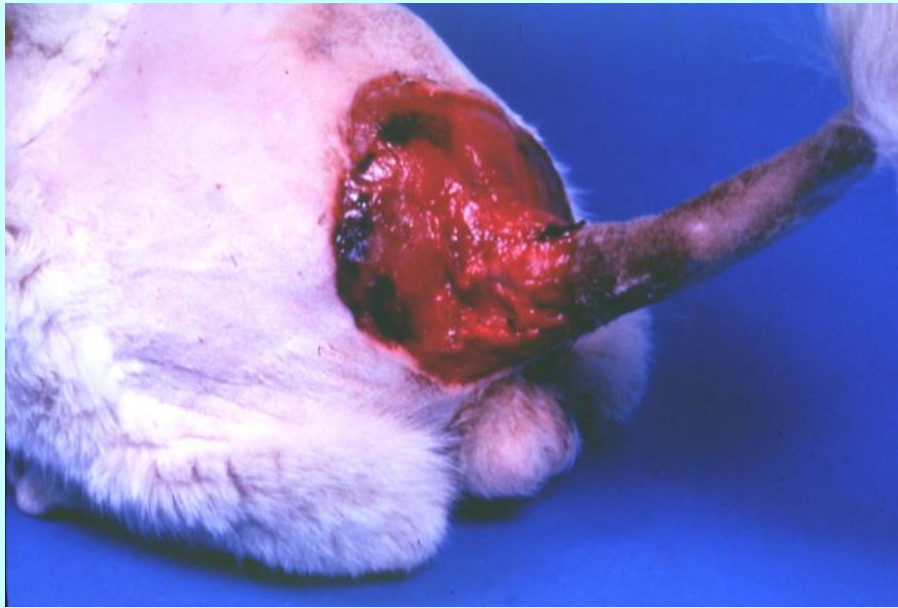


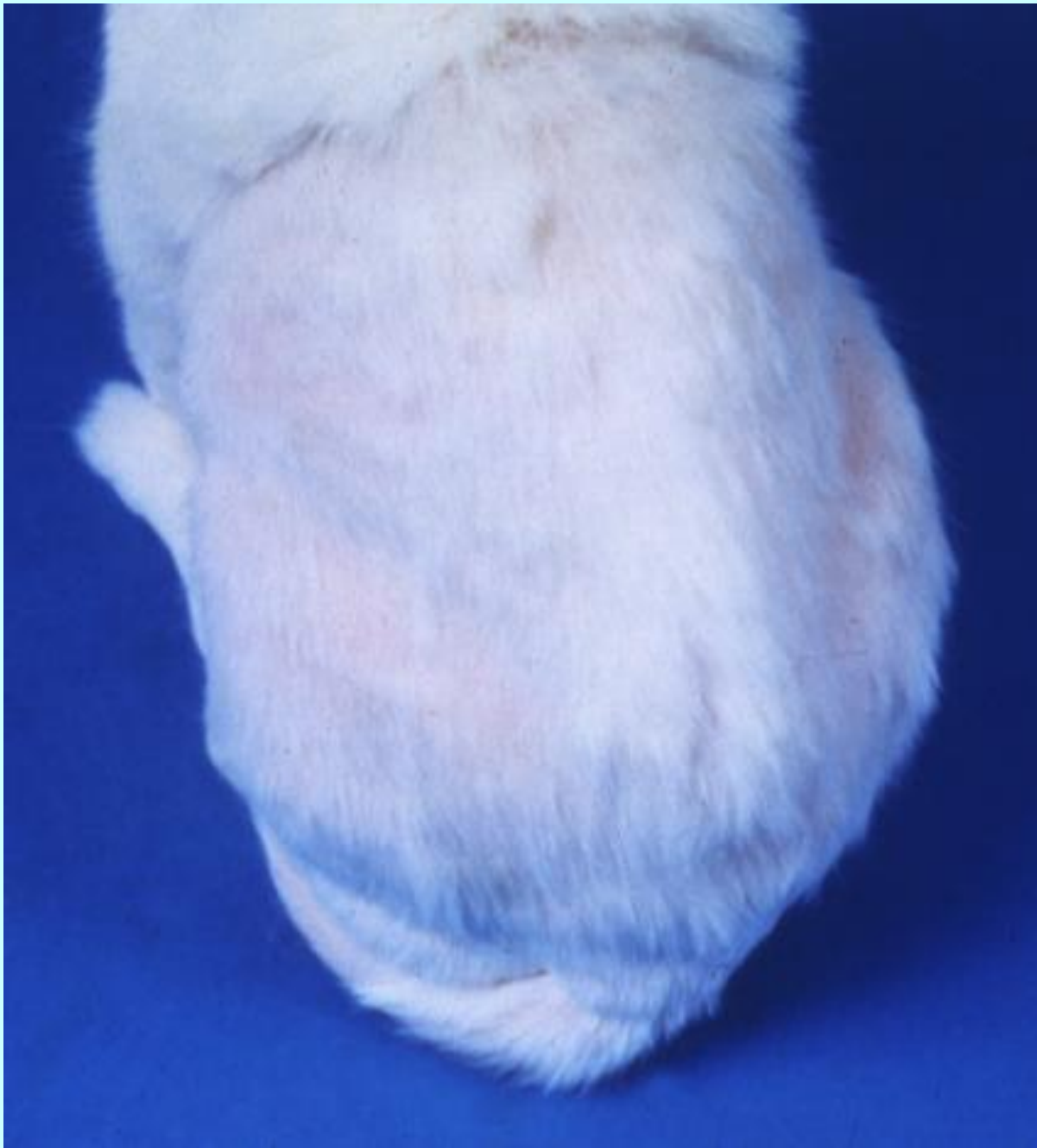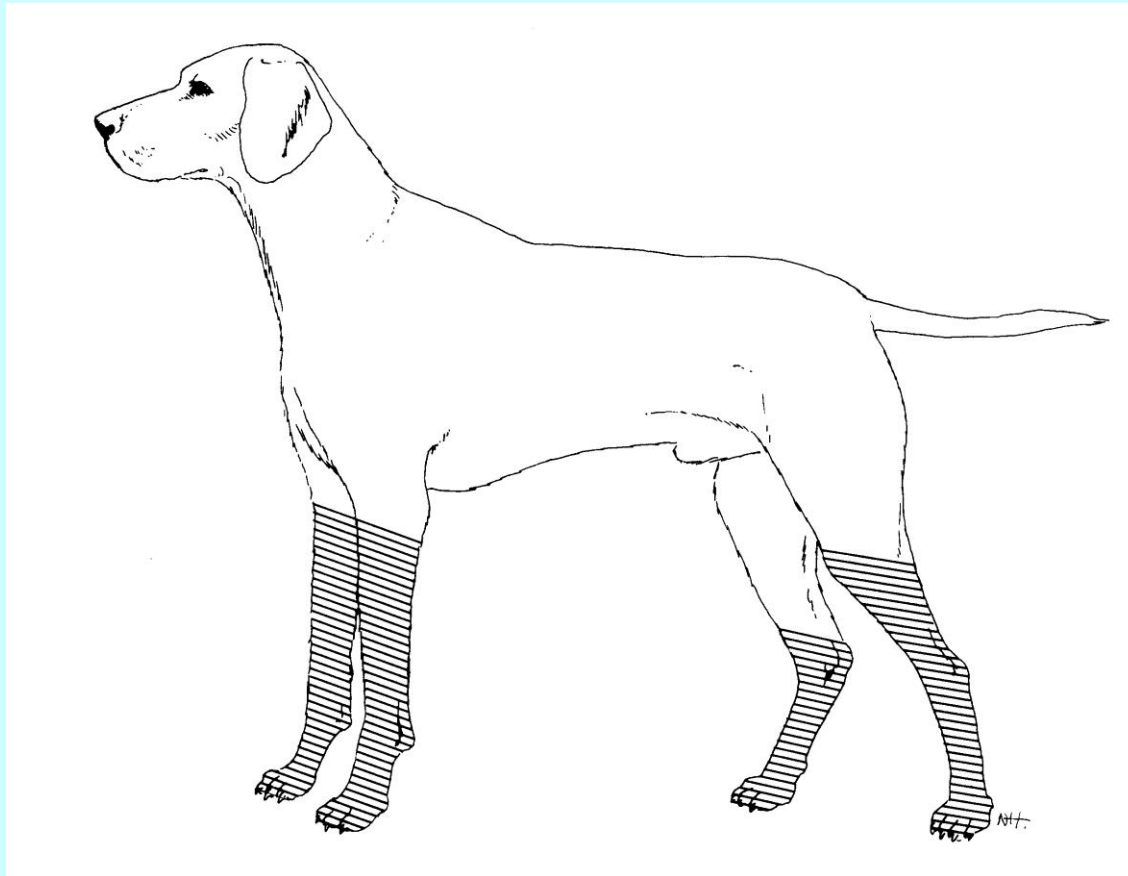
Πολλαπλοί κρημνοί

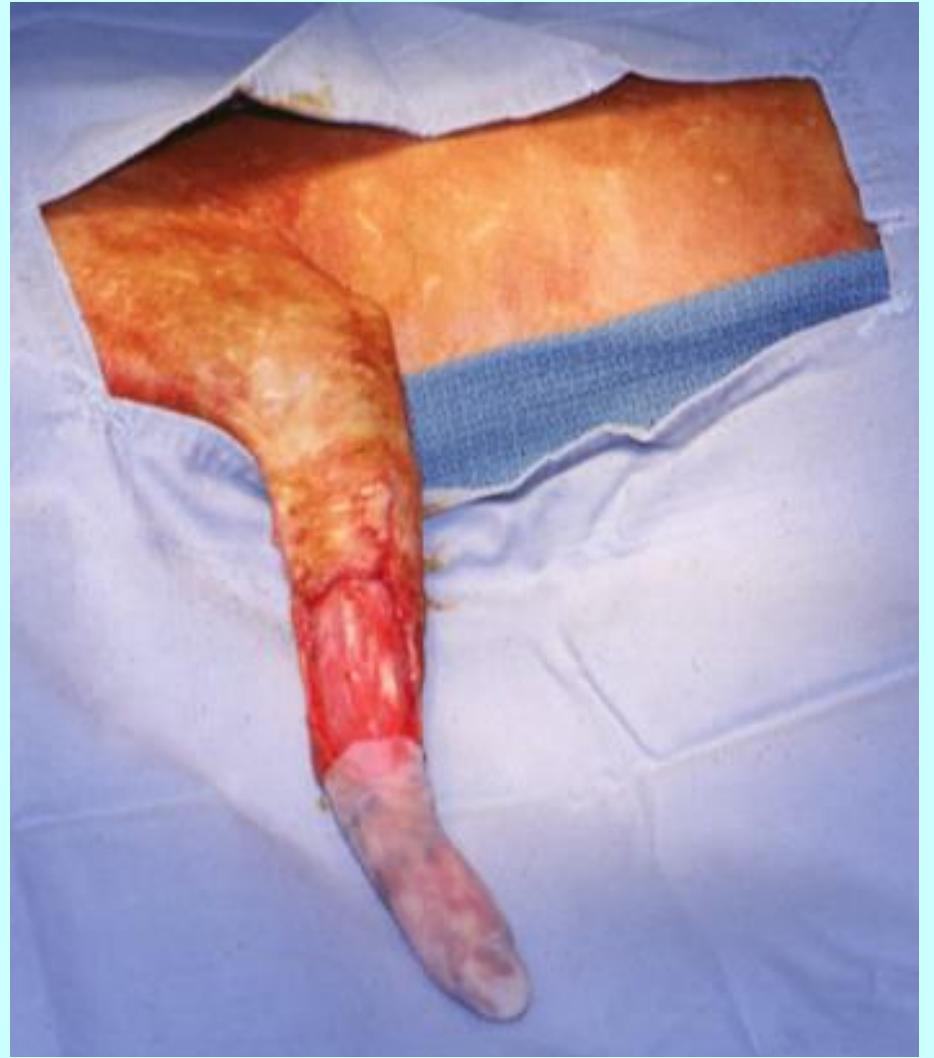
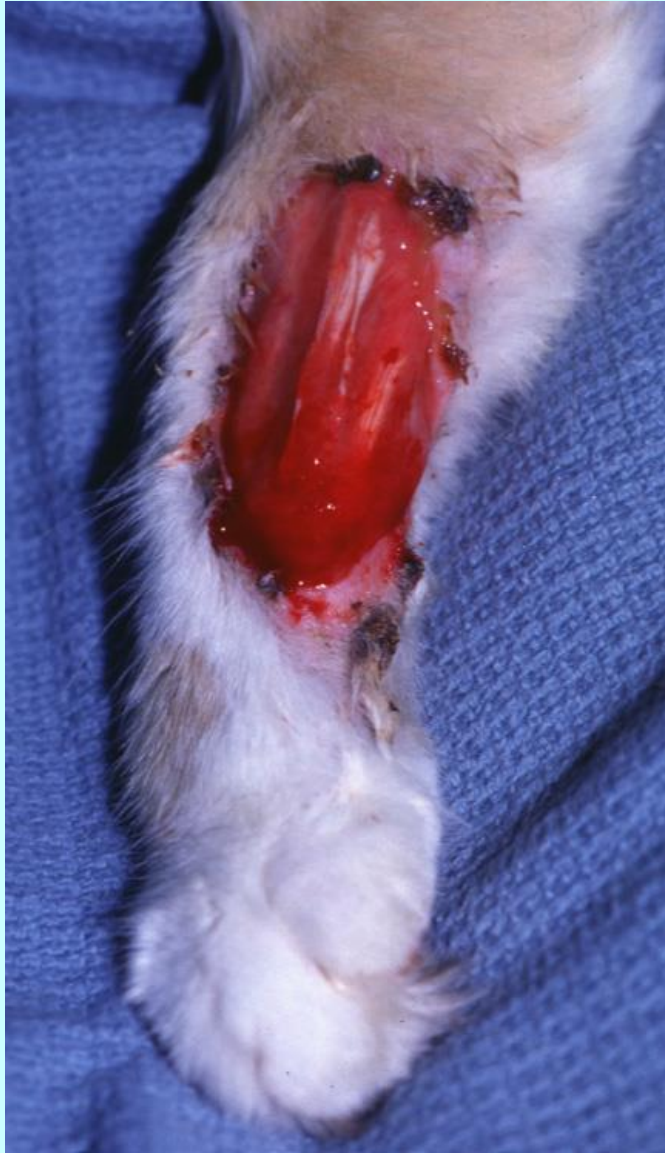


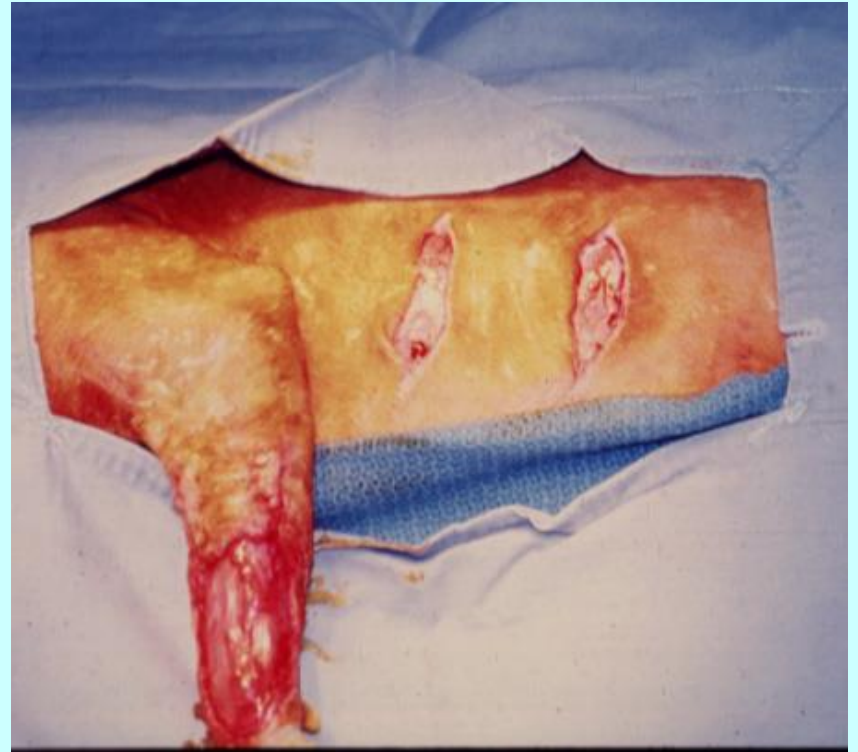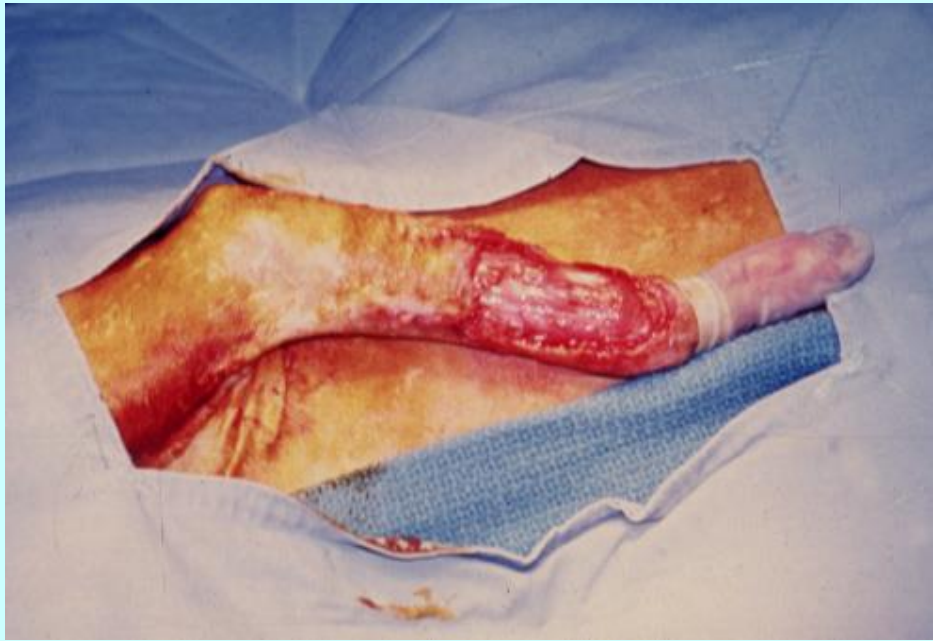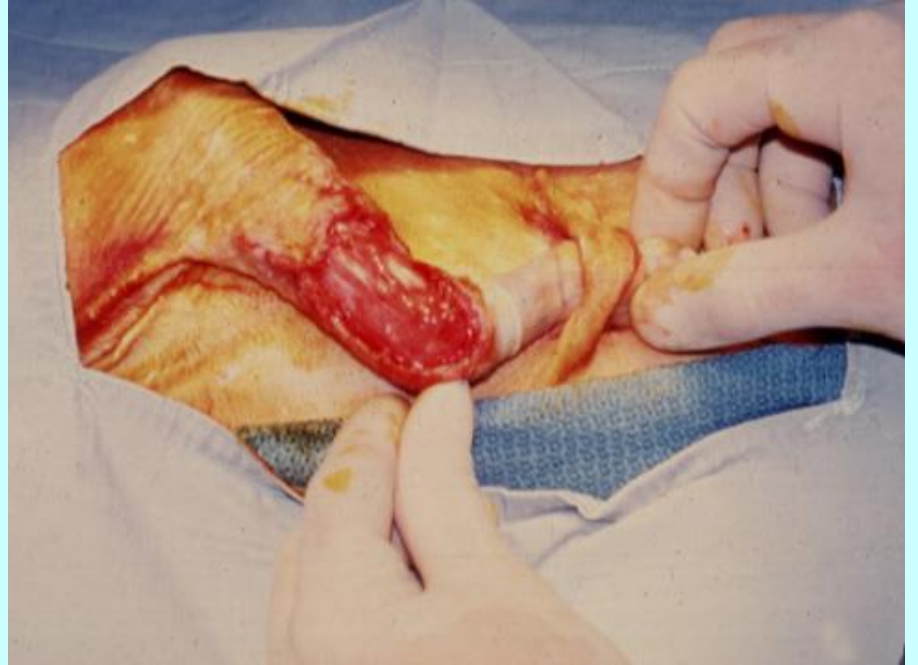
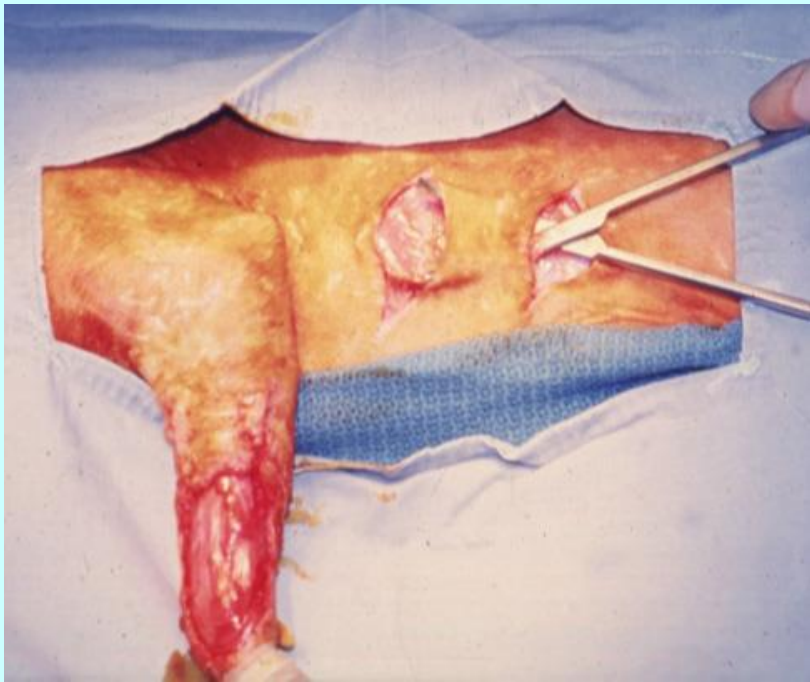


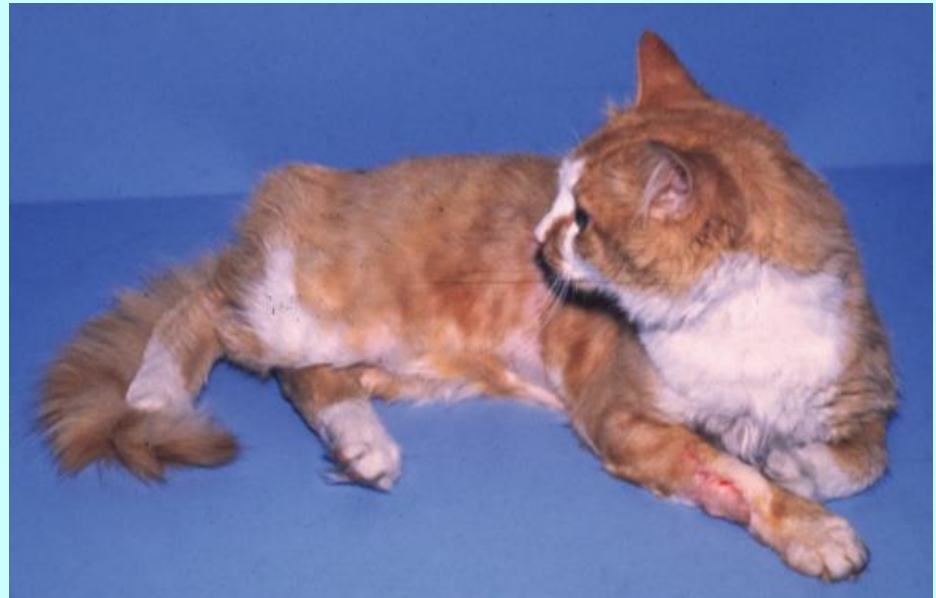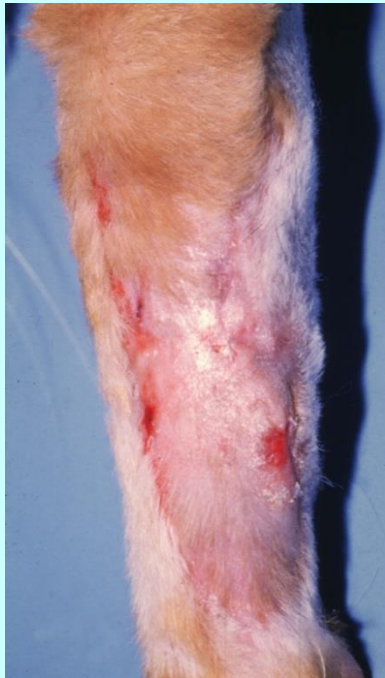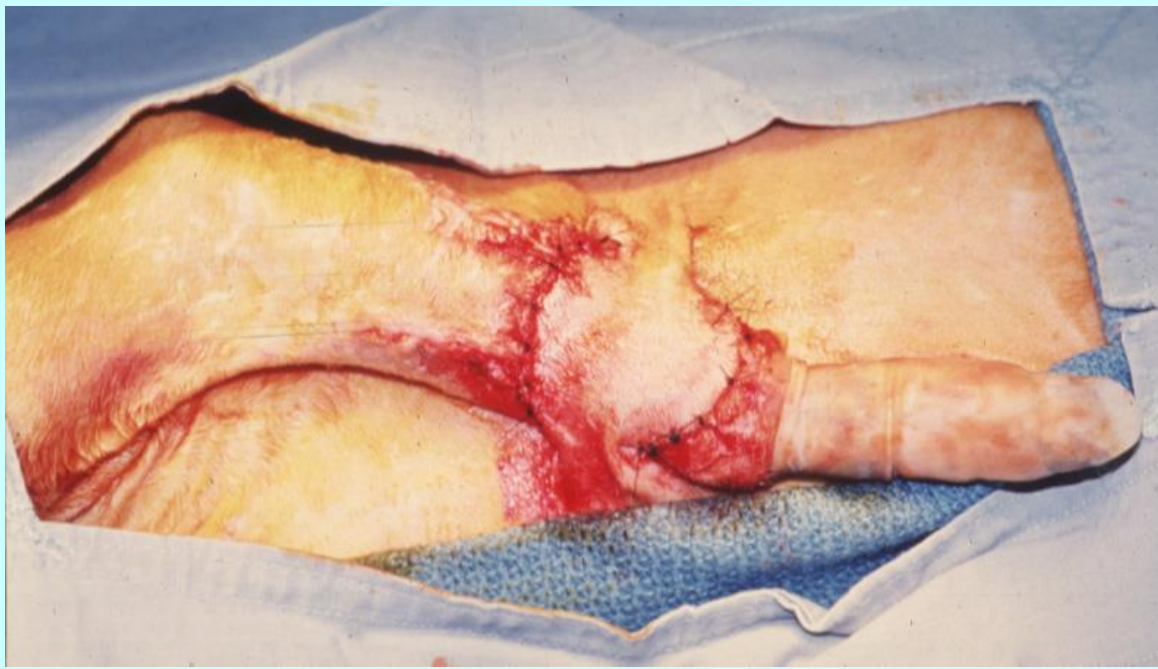Απομακρυσμένοι κρημνοί











Επιπλοκές

- Ισχαιμική νέκρωση
- Ορώδης συλλογή/αιμάτωμα
- Οίδημα
- Διασπαση
- Λοίμωξη

