




DIAGNOSTIC & THERAPEUTIC APPROACHES IN OPHTHALMOLOGY

1st Department of Ophthalmology A.U.T.H.

Clinic Director: Prof. Panagiotis K Oikonomidis

2nd Department of Ophthalmology A.U.T.H.

Clinic Director: Prof. Stavros A. Dimitrakos



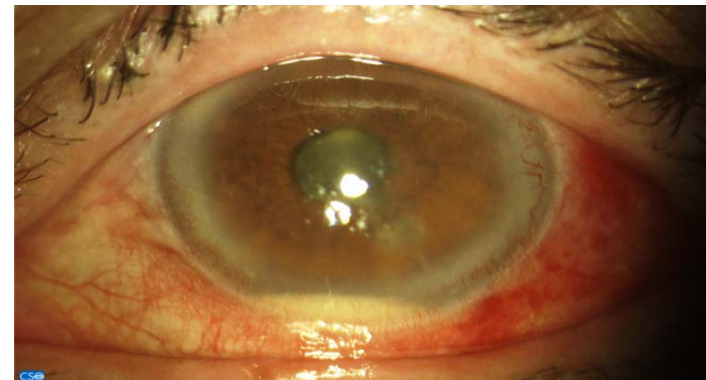
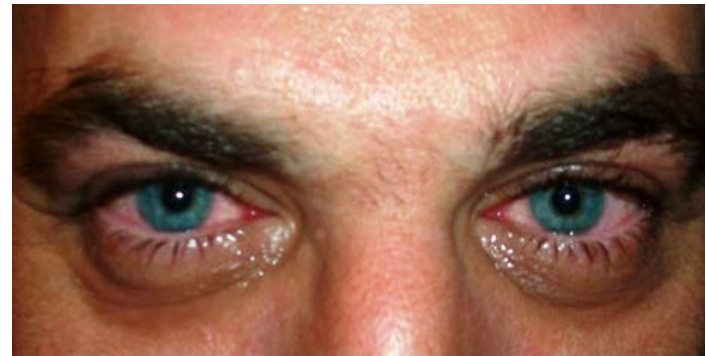Chapter 2

Skills 9-19

- Ophthalmic Symptoms
 - Pain
 - Visual Disturbances

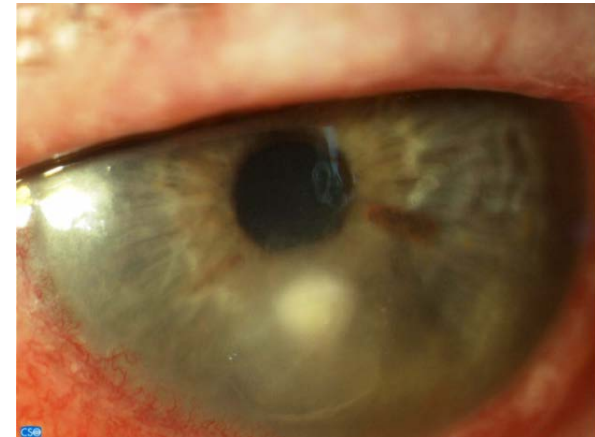
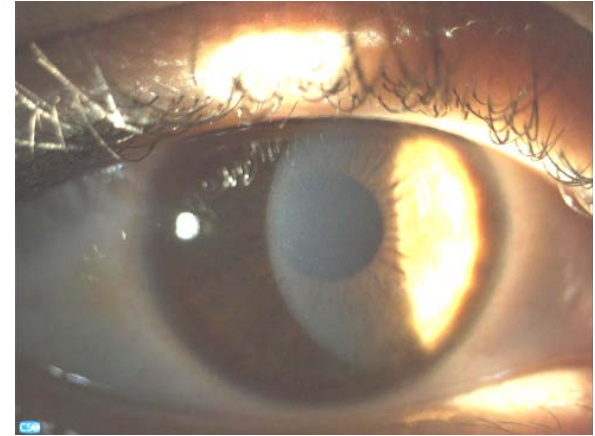
TS 9 : Ocular Pain

- Ocular pain can be:
 - Superficial
 1. Dryness sensation
 2. Foreign body sensation ("sand")
 3. Sharp pain
 - Deep



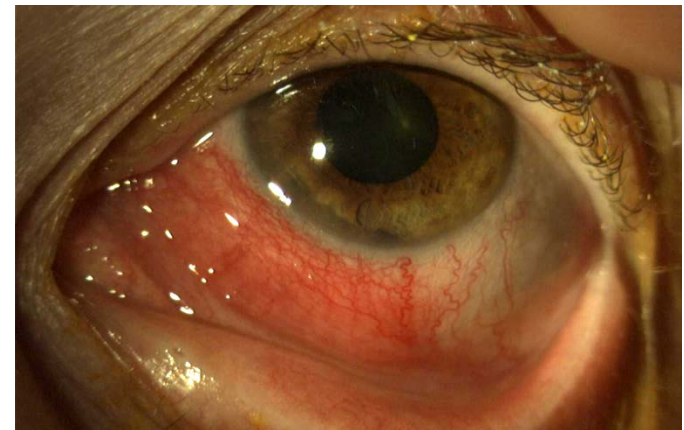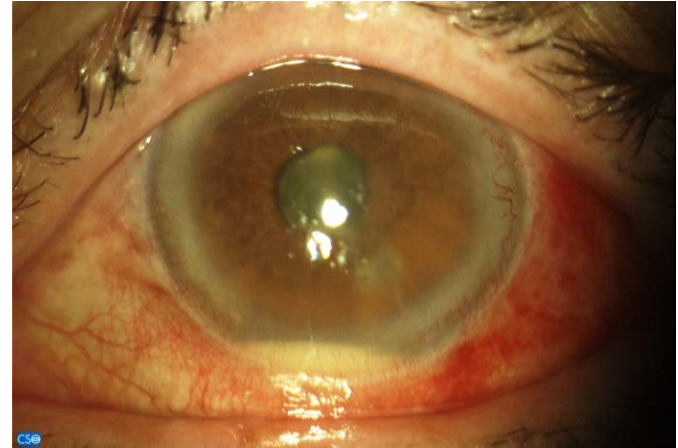
TS 9 : Superficial Ocular Pain

- Mild → Dry eye
- Severe → Keratopathy from radiation, Corneal ulcers
 - Worsens at blinking !
 - HSV → dendritic ulcer, reduced sense of touch



TS 9 : Deep Ocular Pain

- Deep “slow” pain
 - Iritis – Scleritis [uveitis]
 - Reflection → orbit, face
 - Miosis
-
- DD acute glaucoma:
moderate size of pupil



TS 10 : Headache after eye strain

- Headache that ...
 - **Worsens** during the day course
 - **Worsens** after near visual tasks
 - **Stops** after sleeping

... then possibly it's due to



I. Hypermetropia

(effort for constant, excessive accommodation)

or

II. Latent strabismus (heterophoria)

(effort to keep the eyes straight)

TS 11 : Miscellaneous

■ Ophthalmic Migraine

- Secondary to **microvascular** changes
- Is usually accompanied by an aura of $\approx 20'$
 - ✓ Sparkling scotomata
 - ✓ Endoptic phenomena

■ Cluster Headache

- Temporal location, reflects to the globe
- Vivid hyperemia and tearing from the eye



TS 12 : Headache and visual disturbance

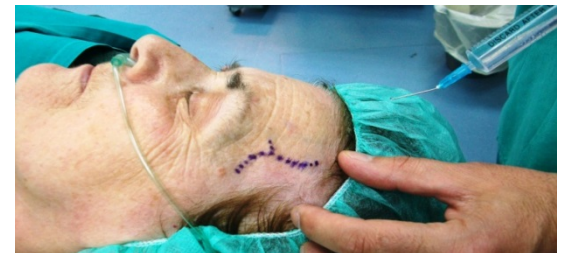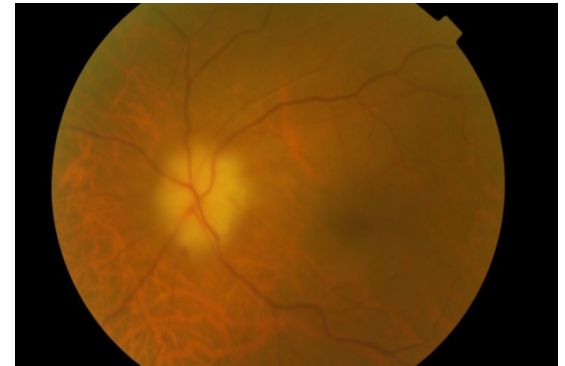
In the elderly

Suspicion of **Temporal Arteritis**

(risk of blindness, general health at risk!!!)

Other **symptoms - signs**:

- Malaise
- Weight loss
- Temporal skin sensitive to touch
- Pain at chewing
- Temporal artery hardness
- High ESR
- Optic disc oedema



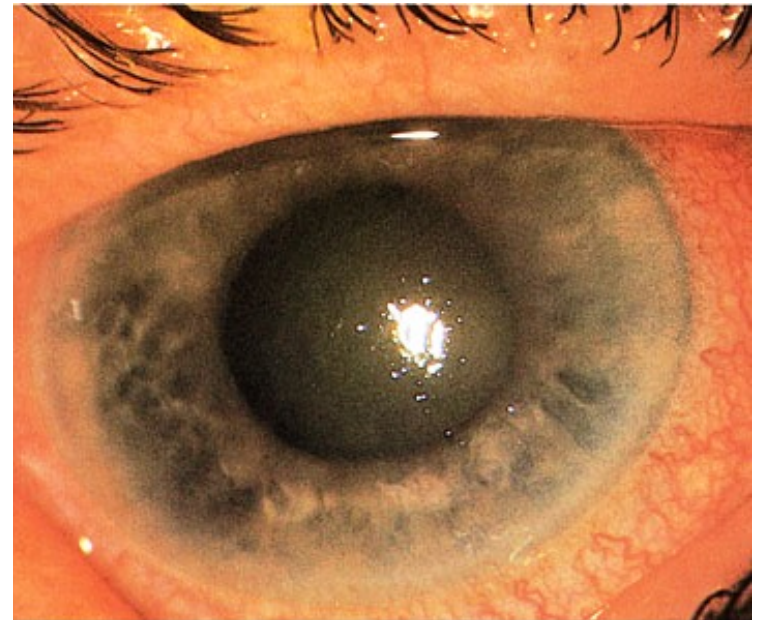
TS 12 : Visual Disturbance and Abdominal Pain

Possible cause

Acute glaucoma

Other symptoms - signs:

- Unilateral ocular pain
- Hazy cornea
- Red eye
- Moderate size of pupil
- Nausea - Vomiting



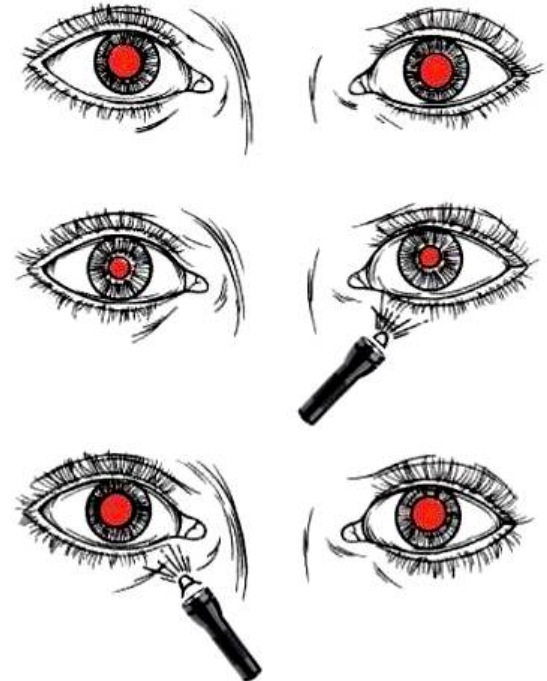
TS 13 : Retrobulbar Pain

Possible cause

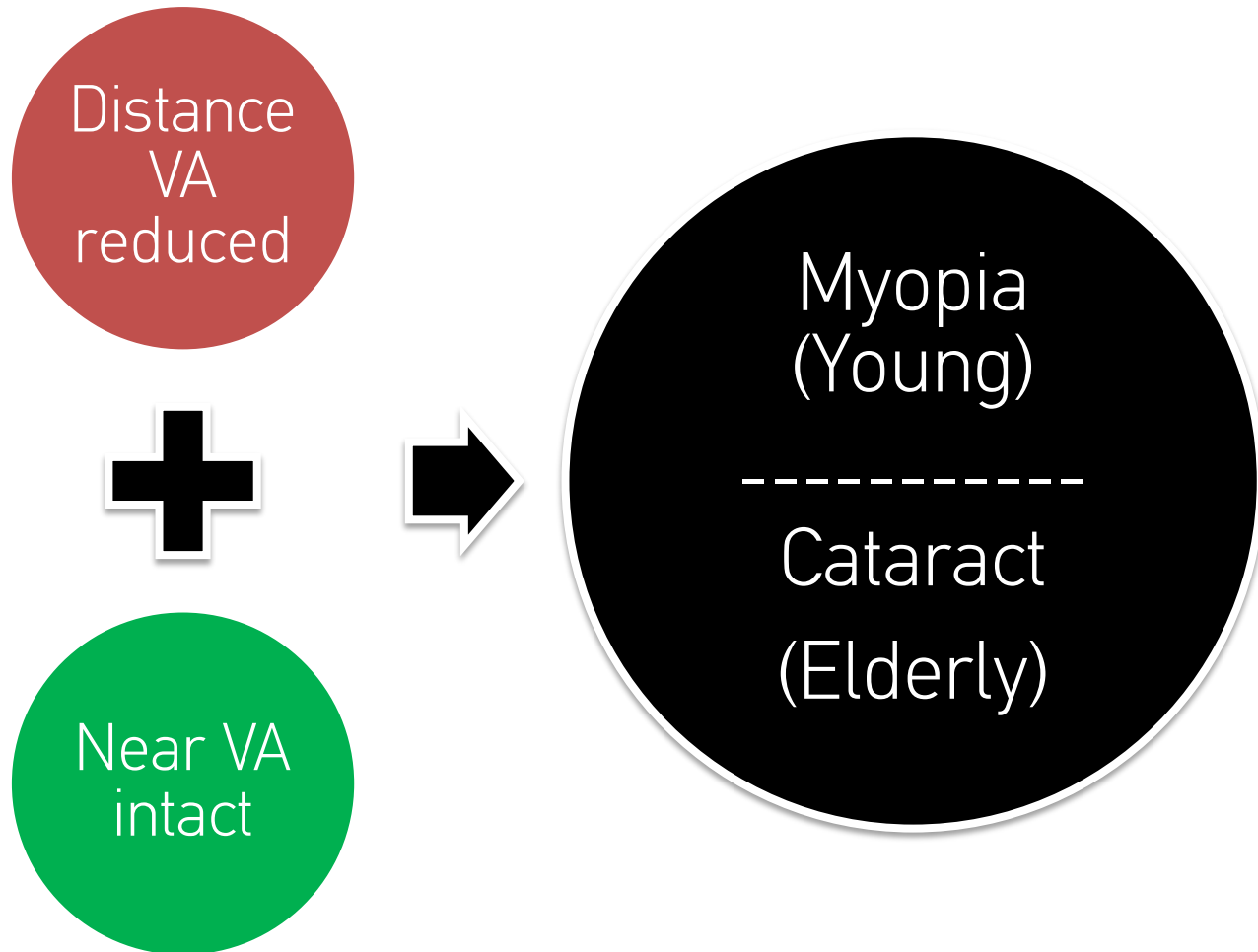
Retrobulbar neuritis

Other symptoms - signs :

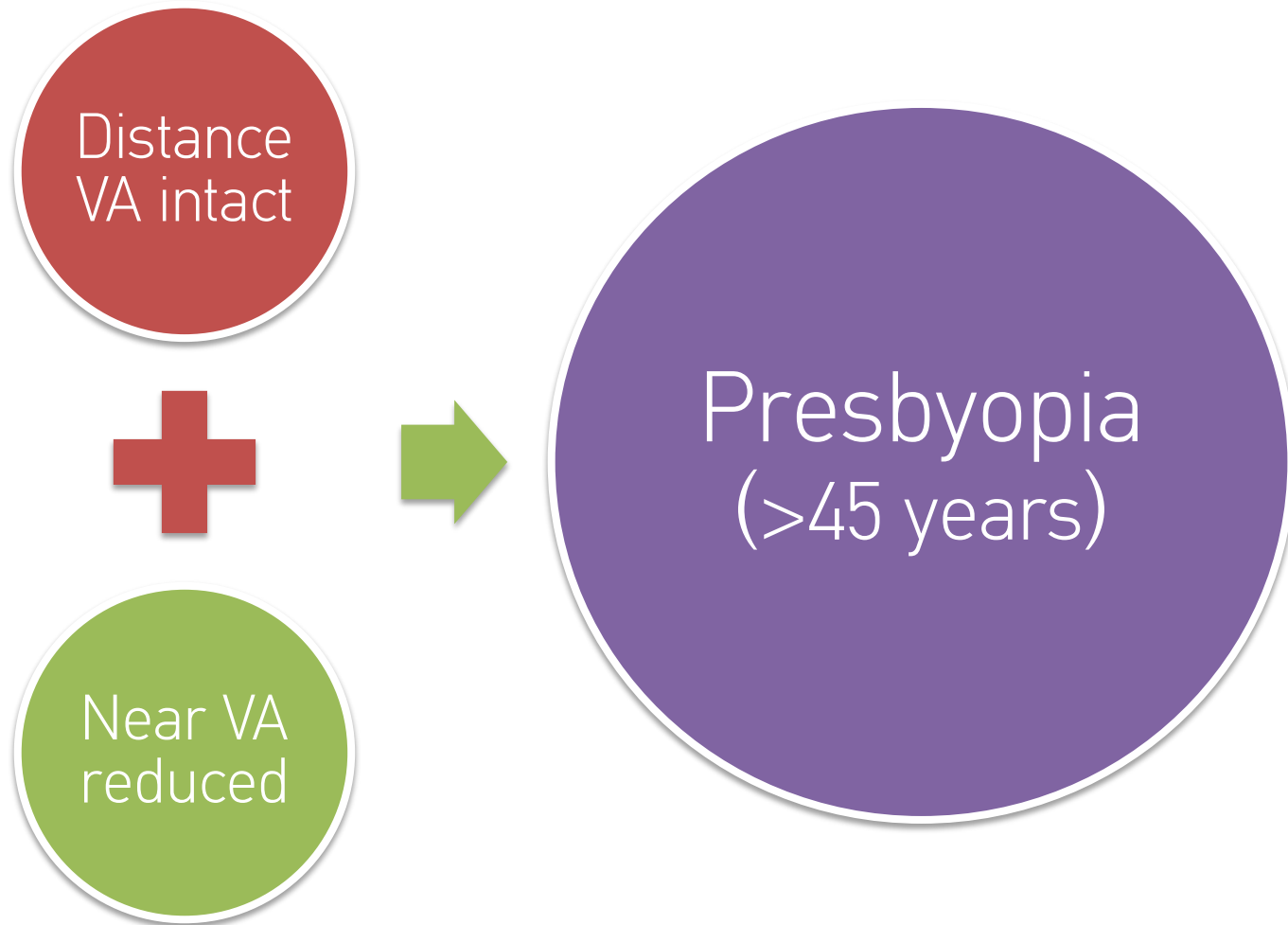
- Visual acuity reduction
- Central scotoma
- Pain worsens at ocular movement



TS 14 : Visual Disturbances



TS 14 : Visual Disturbances



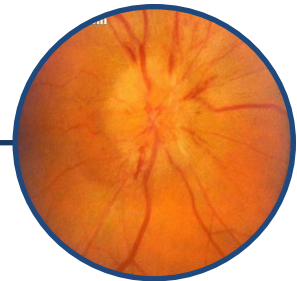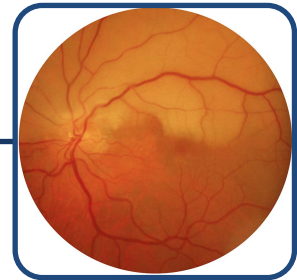

TS 15 : Sudden vision loss

“horizontal” hemifield loss
(superior or inferior)



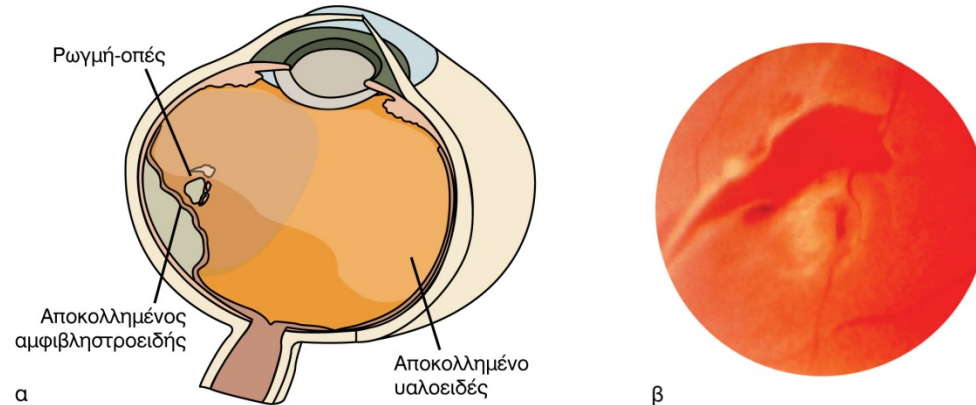
(commonest causes)

- I. Retinal vascular occlusion (artery, vein)
- II. Optic disc capillary occlusion



TS 15 : “black curtain” visual field loss

Possibly
Retinal detachment



- Progressive visual field loss
- Starts from periphery
- Usually 1st symptom is “floaters”

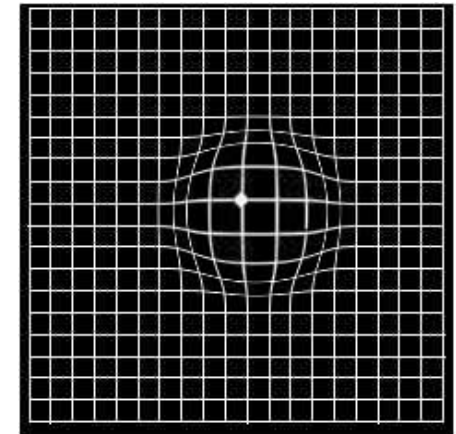
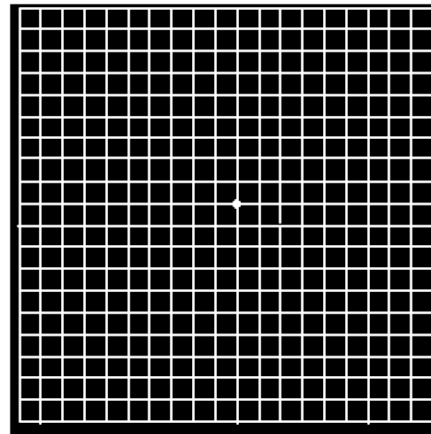
TS 16 : Floaters – “Flashes”

- “flashes”/lightning:
mechanical
 - floaters: vitreal opacities
 - mobile
 - Usually tractional, posterior vitreous detachment
- **NB**
- Risk of retinal detachment



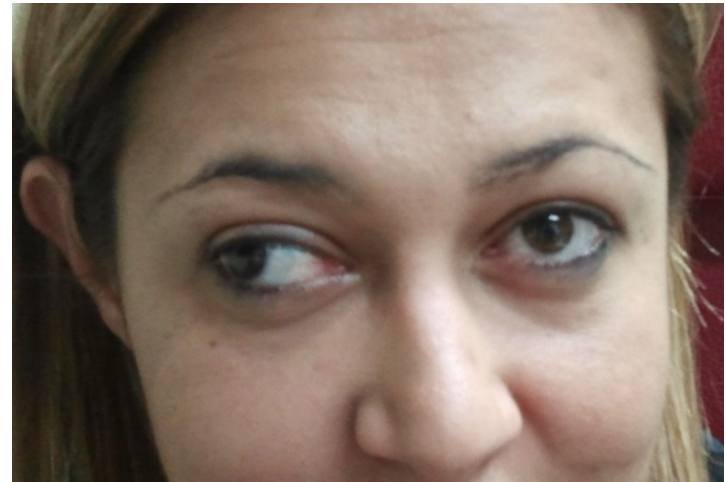TS 17 : Metamorphopsia

- Retinal oedema or wrinkles → image distortion
- Posterior pole (macula) disease
- Amsler grid



TS 18 : Binocular Diplopia

- Disappears when one eye is covered
- Is due to disturbed oculomotility
- Paralytic squint
- Worsens at gaze where the paralytic muscle should be in action



TS 19 : Red eye and visual loss

Disease of:

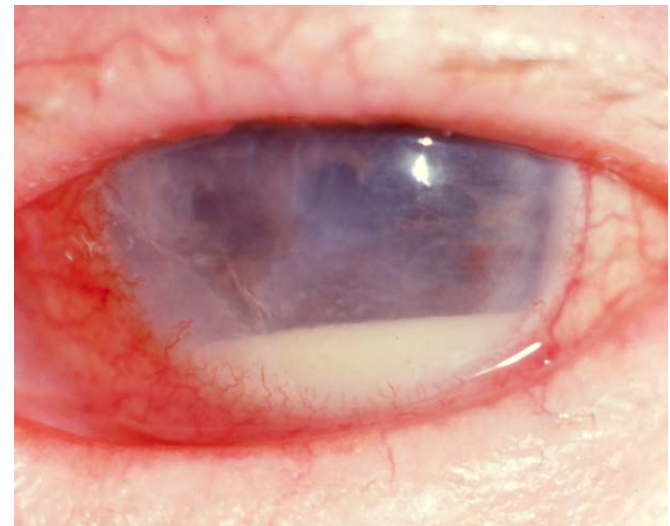
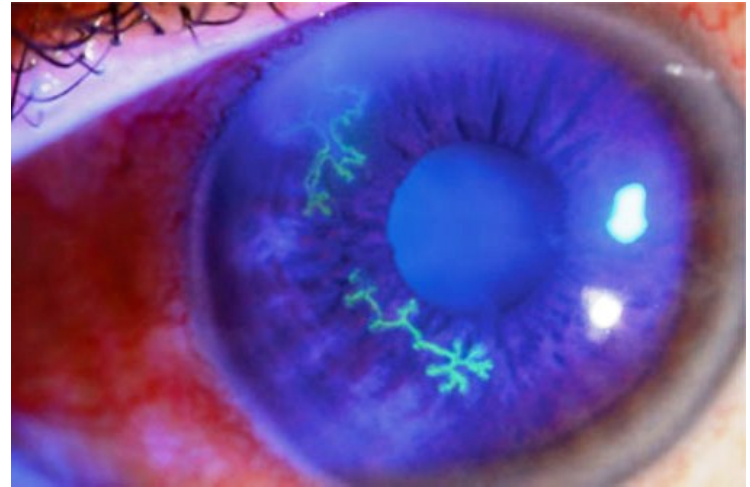- i. Cornea
- ii. Iris – ciliary body

NOT

- ✘ Conjunctiva
- ✘ Sclera (since not in the visual axis)

NB

Visual loss = Refer to
ophthalmologist



Electronic Referrals – 2nd Chapter

1. http://www.emedicinehealth.com/eye_pain/article_em.htm
2. <http://emedicine.medscape.com/article/1192122-overview>
3. <http://migraine.com/migraine-types/ocular-migraine/>
4. <http://www.nlm.nih.gov/medlineplus/ency/article/003029.htm>
5. <http://emedicine.medscape.com/article/1201429-overview>
6. <http://emedicine.medscape.com/article/798811-overview>
7. <http://www.eye-sim.com/>
8. <http://visionsimulations.com/>
9. <http://www.who.int/mediacentre/factsheets/fs282/en/>
10. http://telemedicine.orbis.org/bins/volume_page.asp?cid=1-600-265-14469